

Ectopic supernumerary tooth in the nasal cavity: Report of an unusual case

Dr. Khaled Mahmud¹, Dr. K.A Faisal², Prof. M.N.Faruque³, Dr. Shahan Shah Bappy⁴

¹Associate Professor ENT, Dhaka National Medical College & Hospital. ²Assistant Professor ENT, Dhaka National Medical College & Hospital. ³Professor ENT, Dhaka National Medical College & Hospital. ⁴ Assistant Register ENT, Dhaka National Medical College & Hospital.

Abstract:

The ectopic eruption of tooth in the nasal cavity is uncommon with an incidence of 0.1 to 1.0%. These have been reported from a variety of locations like maxillary sinus, mandibular condyle, coronoid process, orbit, palate and nasal cavity. We report a case involving the floor of nasal cavity.

Keywords: Nasal cavity, Ectopic tooth, Supernumerary tooth, Ectopic eruption

Introduction:

Extra teeth are usually termed supernumerary but some authors reserve this term to describe extra teeth that are ill formed while reserving the term supplemental for extra teeth that have the shape and size of a normal tooth.¹ Intranasal tooth is a rare form of supernumerary tooth. The incidence of supernumerary tooth in general population is 0.1 to 1.0% and of these cases only a small percentage develops intranasal tooth.² We report a case of intranasal tooth.

Case Report:

A 30-year-old female patient presented in the outpatient department of ENT –Dhaka National Medical College & Hospital with a Seven month history of foreign body sensation in the right nostril.

There was no history of nasal discharge, nasal obstruction, pain or epistaxis.

General physical examination of the patient was normal. Anterior rhinoscopy revealed a structure, white to yellowish in color, on the nasal floor around the Little's area. On palpation it was bony hard, slightly mobile and was attached to the hard palate. There were no granulation tissues around it .

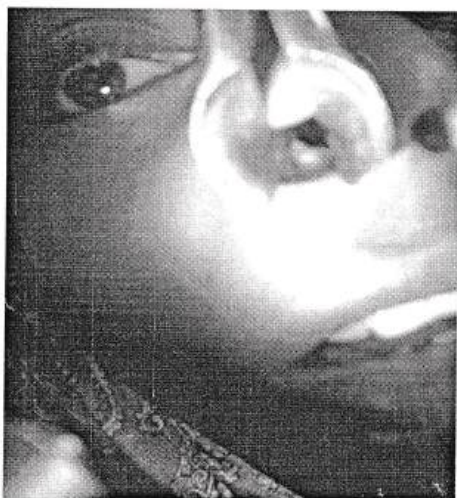


Fig 1: Anterior Rhinoscopy using a Killians nasal speculum showing the tooth lying over the nasal floor.

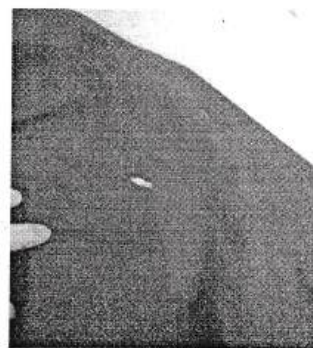

Fig-2: After extraction: Intranasal supernumerary tooth/Ectopic tooth.

Rest of the otorhinolaryngological examination was normal. Dental examination revealed that all the teeth were present. A diagnosis of supernumerary intranasal tooth was made and patient was taken up for extraction under General anesthesia.

A small ball probe was passed under the tooth and it was elevated easily from the hard palate. The tooth was lying in a small shallow groove over the hard palate. The patient made an uneventful recovery.

Discussion:

Nasal teeth are a rare form of supernumerary teeth. The most common location is the upper incisor area known as mesiodens.^{1, 2} The extra teeth have an atypical crown and they appear on the palate as extra teeth as was also seen in our case.

The ectopic eruption of teeth occurs in a variety of locations like maxillary sinus,³ mandibular condyle, coronoid process,⁴ orbit,⁵ palate⁶ and nasal

cavity^{7,8,9,10,11}. The age of diagnosis of intranasal teeth ranges from 3-62 years. There is no sex predilection. Most commonly single ectopic tooth is found but multiple teeth has been reported¹².

The tooth may be asymptomatic at the time of diagnosis and may be noticed on routine clinical or radiological examination.² The symptoms caused by the ectopic tooth include unilateral nasal obstruction,¹³ foul smelling rhinorrhea,¹⁴ crusting, localized ulceration, nasal congestion,¹⁵ epistaxis and foreign body sensation.¹⁶ Uncommon symptoms are pain in the face and nose,¹⁷ sometimes simulating tic douloureux¹³ and nasolacrimal duct obstruction.¹⁸ The complications that can be associated with ectopic teeth include rhinitis caseosa,¹⁹ oro-nasal fistula.²⁰

Clinically, an intra-nasal tooth may be seen as a white mass in the nasal

cavity surrounded by granulation tissue and debris. The diagnosis is usually not difficult, but may be missed most easily when the tooth is almost completely embedded in the nasal mucosa and is on the nasal floor, where it may be overlooked in the routine examination. On probing the tooth is hard, usually smooth and slightly mobile. This is helpful to differentiate it from exostosis and odontomas, which are not mobile and from foreign bodies and sequestra, which are usually readily mobile^{2,12,13,17}.

Radiologically, the nasal teeth appear as radio-opaque lesion with the same attenuation as that of the oral teeth. The soft tissue surrounding the radio-opaque lesion is consistent with the granulation tissue found on clinical and pathological examinations. Radiological examination may or may not be helpful in confirming the diagnosis of intra nasal tooth because it appears only as a non-specific radio-opaque lesion near the nasal cavity. The exact relationships of the supernumerary tooth can be best studied by the panoramic radiology using an orthopantomogram. This can provide a good record of all the teeth present, whether erupted or not.^{7,21}

Supernumerary teeth are more commonly related to the upper jaw and lie either in relation to the central incisors or less frequently to the third molars. These teeth develop either from a third tooth bud that arises from the dental lamina near the permanent tooth bud or possibly from splitting of the permanent bud itself.² The cause of ectopic tooth is not well understood. It has been attributed to

crowded dentition, persistent deciduous tooth or exceptionally dense bone.²² The other proposed pathogenic factors include a genetic predisposition, developmental disturbances such as cleft palate,

rhinogenic or odontogenic infections and displacement as a result of trauma or cyst.^{12, 13,21,22,23} Raje et al described osteomyelitis of the maxilla as a cause of nasal teeth and reported three ectopic nasal teeth, following osteomyelitis of the maxilla.²⁴

The differential diagnosis of nasal teeth includes radio-opaque foreign body, rhinolith, inflammatory lesions due to syphilis, tuberculosis, and fungal infections with calcification. Benign tumors including: hemangiomas, osteomas, calcified polyps, enchondromas, dermoids and malignant tumors like chondrosarcoma and osteosarcoma²¹.

The treatment of ectopic teeth is surgical. Removal of symptomatic intranasal teeth will alleviate the symptoms and prevent complications. When an extra tooth is in the nasal cavity the procedure is usually a minor operation. When a tooth has a bony socket in the floor of the nose, it may be extremely difficult to extract.²⁵ CT is useful to evaluate the depth of eruption site. The best time to remove the tooth is after the roots of the permanent teeth have completely formed to avoid injury during their development.²¹ In case of asymptomatic tooth a close follow up is advised especially when the patient is unwilling to go for surgery.^{2, 7, 12, 21}

References:

1. Worth HM. Principles and practice of oral radiologic interpretations. Year book medical publishers Inc, Chicago Ill 1968; 101-105.
2. Thawley SE, Ferriere KA. Supernumerary nasal teeth. Laryngoscope 1977; 87: 1770-3.
3. Prasanna NM, Vecchio SR. Dentigerous cyst. Canad J Otolaryngol 1974;3: 625-29.
4. Sutton PR. Migratory non-erupted mandibular premolars: A case of migration into coronoid process. Oral Surg 1968; 25: 87-98.
5. Savundranayagan A. A migratory third molar erupting into lower border of the orbit causing blindness in the left eye. Aust Dent J 1972; 17: 418-20.
6. Gans BJ. Ectopic tooth: Report of a case. J Oral Surg 1962; 20: 435-37.
7. Martinson FD, Cockshott WP. Ectopic nasal dentition. Clin Radiol 1972; 23:451-54.
8. Kohli GS, Verma PL. Ectopic supernumerary tooth in the nasal cavity. J Laryngol Otol 1970; 84: 537-38.
9. Rao ABN. Aberrant canine tooth in the nose. J Laryngol Otol 1953; 67: 370-71.
10. Endicoff CL. A case of a supernumerary incisor erupting into the nose. Br Dent J 1934; 56: 385-6.
11. Kasliwal KC, Rastogi PC. Teeth as foreign bodies in nose. Indian J Radiol 1969; 32: 22-3.

12. Smith RA, Gordon NC, De-Luchi SF. Intranasal teeth: report of two cases and review of the literature. *Oral Surg Oral Med Oral Pathol* 1979; 47: 120-22.
13. Hitschler WJ. Nasal teeth. *Arch Otolaryngol* 1938; 28: 911-25.
14. Hiranandani LH, Melgiri RD. Supernumerary tooth in the nose. *J Laryngol Otol* 1968; 82: 845-8.
15. Lindsay JR, Karian BK. Ectopic teeth: report of a case. *J Oral Surg* 1969; 27: 135-36.
16. Bertrand L. Dent Surnumeraire dans les fosses nasales. *Canad Dent Assoc J* 1964; 30: 217-72.
17. Chopra SS, Joshi MR. Mesiodens erupted in the nasal cavity. *Oral surgery* 1969; 28: 856-58.
18. Alexandrakis G, Hubbel RN, Aitken PA. Nasolacrimal duct obstruction secondary to ectopic teeth. *Ophthalmol* 2000; 107: 189- 92.
19. Abercrombie PH. Eruption of a canine tooth into the nasal fossa attended by rhinitis caseosa. *J Laryngol Otol* 1925; 40: 586-9.
20. El-Sayed Y. Sino-nasal teeth. *J Otolaryngol* 1995; 24: 180-83.
21. Chen A, Huang JK, Chen SJ, Shev CY. Nasal teeth: report of three cases. *Am J Neuroradiol* 2002; 23: 671-3.
22. Moreano EH, Zick DK, Goree JC et al. Nasal tooth. *Am J Otolaryngol* 1998; 19: 124- 26.
23. Lumba SP, Nirola A, Grewal BS. Healed osteomyelitis of maxilla with tooth in the floor of the nose. *J Laryngol Otol* 1971; 85: 877-9.
24. Rege SR, Shal KL, Marfati PT. Osteomyelitis of maxilla with extrusion of teeth in the floor of the nose requiring extraction. *J Laryngol Otol* 1970; 84: 533- 35.
25. Wurtele P, Dufour G. Radiology case of the month: A tooth in the nose. *J Otolaryngol* 1994;23: 67-8.