

## Case Report

# Reimplantation of Accidentally Avulsed Permanent Maxillary Anterior Teeth in a 10-Year-Old Girl

Md Abdul Hannan Sheikh<sup>1</sup>

Received: March 17, 2017 Accepted: August 21, 2017

doi: <http://dx.doi.org/10.3329/jemc.v7i3.34078>

### Abstract

*Accidental tooth avulsion is a grievous injury and common among the children. Management of avulsed tooth within alveolar socket by reimplantation becomes a challenge for the clinician due to extraoral time and media of transportation. Although the long-term prognosis of reimplantation is poor, the time during which the tooth remain within the arch will guide the development of alveolar bone completely. Moreover, reimplantation will maintain anatomical, functional and esthetic rehabilitation of the patient. In this case report, we present a case of accidental avulsion where teeth were gently rinsed of any debris and placed in normal saline during the examination and preparation of the reimplantation sockets. The teeth were then reimplanted, functionally splinted followed by endodontical treatment. After 12 months follow-up the periodontal space was healed perfectly without any resorption or ankylosis.*

**Key words:** Trauma; Avulsion; Reimplantation

J Enam Med Col 2017; 7(3): 165–169

### Introduction

Avulsion or exarticulation occurs when a traumatic injury totally displaces a tooth from the socket.<sup>1</sup> Traumatic injuries are quite common. Unfortunately, no valid statistics is available regarding this in our country. According to the National Clinical Guideline of The Royal College of Surgeons, England, the incidence of traumatic avulsion of teeth has been reported as 0.5–16% of all traumatized teeth. Upper central incisor teeth are most frequently avulsed in the age group 7–9 years.<sup>2</sup> Common causes of injury are falls, collisions and accidents during common childhood activities such as contact sports, cycling, swimming, fight etc.<sup>3</sup>

Pathophysiology lies in the fact that extrusive forces impinging on the teeth, when severe enough, can cause a tooth to be displaced out of its socket. For this to happen, the periodontal ligament (PDL) would have

ruptured with remnants remaining on the cementum of the root of the tooth and the inner walls of the alveolar socket. The vessels entering the pulp through the apical foramen would also have been severed with cessation of blood supply to the pulp. The extent of injury sustained by the periodontal ligament and the pulp, and the subsequent healing of these tissues will depend on the extra-alveolar period, i.e., the time during which tooth remains out of its socket and the time require for handling of the tooth.<sup>3</sup>

Treatment is directed at avoiding or minimizing the resultant inflammation from the two main consequences of the avulsed tooth — attachment damage and pulpal infection.<sup>4</sup> Best outcome for a tooth avulsion is when the tooth can be reimplanted within a few minutes after the accident. A very high percentage of teeth reimplanted within 15 minutes will have the PDL restored within a few weeks.<sup>5</sup> Immediately after reimplantation inflammatory process in periodontal

---

1. Classified Specialist in Conservative Dentistry & Endodontist, Combined Military Hospital, Savar Cantonment, Dhaka  
Correspondence Md Abdul Hannan Sheikh, E-mail: [drhannan65@gmail.com](mailto:drhannan65@gmail.com)

tissues induces the reorganization of new attachment apparatus to induce healing. Depending upon severity of injury, four types of healing may occur in periodontal ligament area: (i) healing with normal periodontal ligament, (ii) healing with the surface resorption, (iii) healing with replacement resorption and (iv) healing with inflammatory resorption. More than one type of reaction may present at any time.<sup>6</sup> The present case report describes the management of avulsed permanent anterior teeth by reimplantation and functional splinting followed by endodontic treatment.

### Case report

A 10-year-old girl came to the department of Conservative Dentistry and Endodontics, BSMMU with the complaint of accidental missing of her four upper anterior teeth during playing. Her medical history was not contributory. She had history of tetanus immunization. She reported after 45 minutes of the accident with the missed teeth on her hand which was immersed within normal saline. On clinical examination, she had missing maxillary central and lateral incisors, lacerated gum tissue, swelling of upper lip and blood clot within the sockets (Fig 1). The teeth were gently rinsed of any debris and placed in normal saline during the examination and preparation of the reimplantation sockets (Fig 2). There was no other dental or bony damage in her mouth (Fig 3) but the area was tender on palpation. After discussion of all the treatment options with the patient's guardian, it was decided to reimplant the teeth within the sockets.

The traumatized socket was inspected for any bone and tooth fragments. As the blood clot was present, gentle irrigation with normal saline was done. A straight elevator was introduced into the socket for repositioning of the bone into its normal position as there might be chance of bone collapse.

Avulsed tooth was then reimplanted carefully into the prepared socket one by one holding it with the fingers to avoid contact with the roots (Fig 4). Complete reimplantation was determined by comparing the incisal edge of replanted incisors with the incisal edge

of the adjacent teeth (Fig 5).

After reimplantation, facial and lingual soft tissues covering the alveolar bone was compressed with the fingers. The reimplanted tooth was in slightly rotated position but the guardian told that before avulsion the child's original tooth was in the same position, so it was accepted by the guardian. The reimplanted teeth and adjacent two teeth on each side were attached together with glass-ionomer cement and orthodontic wire to form a functional splint (Fig 6). To ensure complete placement of the reimplanted teeth within the sockets, the patient was asked to bite gently and the occlusion was found normal.

Patient was advised to take soft food, not to bite with the tooth and maintain proper oral hygiene for one week. Chlorhexidine mouth wash was advised while the splint was in place. Antibiotic cefixime (200 mg) was prescribed 12 hourly for 7 days to negate bacterial contamination or rapidly progressing root resorption.

Anti-inflammatory drugs was also prescribed. The patient came at recall visit after seven days of reimplantation for evaluation of healing process. After local anesthesia infiltration, proper access cavity was prepared at all four teeth. Extirpation of pulp tissue was done and normal saline was used for irrigation of the root canals. Working length was measured. Endodontic preparation was completed by hand protaper instruments in standardized technique in all four teeth. Calcium hydroxide was used as intracanal medicament for one week. At third recall visit, canals were obturated with GP Point and zinc-oxide eugenol sealer using lateral condensation technique. The access cavity was then filled with glass-ionomer filling material. The tooth was assessed clinically and radiographically after two weeks (Fig 7) but no pathology was found and the teeth were not mobile at that stage, so the splint was removed.

After six months, there was evidence of apical bone formation and periodontal area was under healing process with cementum (Fig 8). After one year there was increased rate of alveolar bone formation and no sign of tooth resorption (Fig 9, 10).

### Clinical steps of reimplantation, splinting and root canal treatment

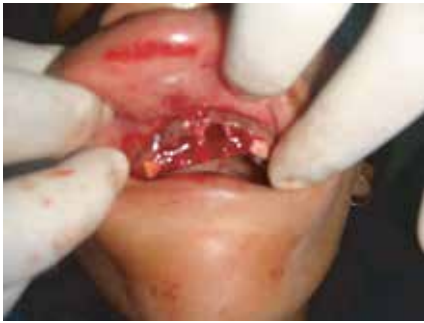

Fig 1. Absence of central and lateral incisors



Fig 2. Avulsed teeth



Fig 3. Empty bony sockets

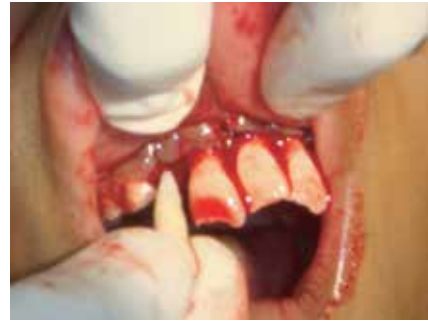

Fig 4. Procedure of re-implantation

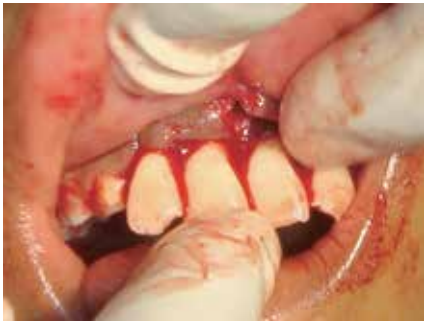

Fig 5. Re-implantation of teeth

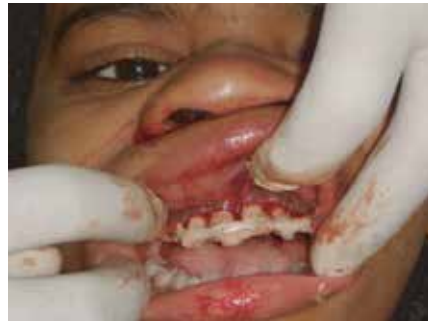

Fig 6. Functional splint

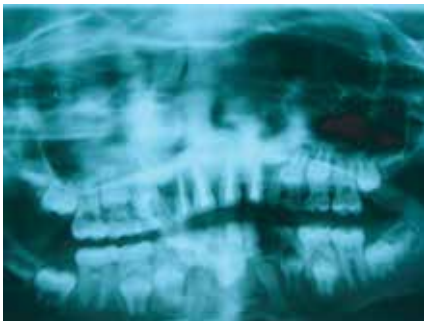


Fig 7. OPG view after RCT and removal of splint

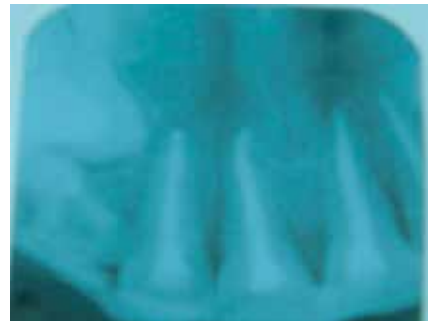


Fig 8. Periapical image after six months



Fig 9. Periapical image after 12 months

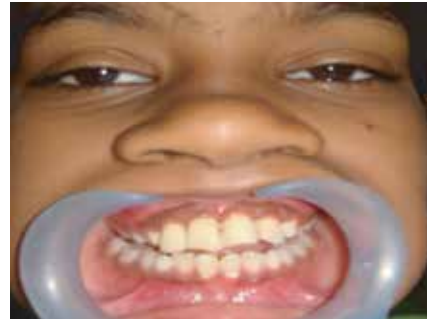

Fig 10. Photograph after 12 months.

## Discussion

The period between tooth avulsion and reimplantation is normally out of control of a dentist but this period is important with regard to the prognosis of the tooth.<sup>2</sup> An extraoral dry time of less than 15–20 minutes is considered optimal where periodontal healing would be expected. A continuing challenge is the treatment of the tooth that has been dry for more than 20 minutes (periodontal cell survival is ensured) but less than 60 minutes (periodontal survival unlikely). In these cases, the root surface consists of some cells with the potential to regenerate and some that will act as inflammatory stimulators.<sup>7</sup> Extraoral dry time was 45 minutes in our case.

The medium in which the tooth has been stored prior to reimplantation has been shown to affect the incidence of root resorption and pulp healing. The most recent guidelines established by the American Association of Endodontists (AAE) list Hank's Balanced Salt Solution or HBSS, a tissue culture medium as the medium of choice. However, its lack of availability at the accident site greatly limits its use. Milk has been shown to be successful in maintaining PDL cell viability for about three hours, and its relatively universal availability further enhances its utility. Low-fat milk at a cool temperature is preferred for ensuring PDL cell viability. In decreasing order of suitability, physiological saline, saliva and water can be used in the absence of milk. Ultimately, the latter two may be detrimental to cell viability owing to the presence of bacteria, unfavourable pH and osmolarity.<sup>8</sup> In the present case, though the transport media (normal saline) was desirable, extraoral time period was unfavourable.

Reimplantation of a tooth may be carried out without

local anaesthesia, especially if presentation to the dentist is soon after avulsion and only a soft blood clot is present. In many cases local anaesthetic is desirable to enable adequate socket preparation and positioning of the tooth.<sup>2</sup> In this case local anaesthesia was used for patient comfort.

A past favoured method of treatment involved carrying out root canal treatment of avulsed teeth prior to reimplantation. In most cases this method of treatment is no longer acceptable as it imparts a poorer prognosis because of increased damage to the periodontal ligament cells by prolonged drying and handling. It is also desirable to maintain a patent root canal as a vehicle for application of medicaments to reduce infection and/absorption. However, in a few cases it may be acceptable to complete endodontic treatment prior to reimplantation.<sup>2</sup> In the present case, root canal treatment was initiated in second visit.

Semi-rigid (physiologic) fixation for 7–10 days is recommended. The splinting period can be extended for up to eight weeks if there is a concomitant alveolar process fracture. If excessive mobility persists after ten days, splinting time can be extended until mobility is acceptable.<sup>2</sup> In this case splinting was removed after 14 days.

Systemic antibiotics given at the time of reimplantation and prior to endodontic treatment are effective in preventing bacterial invasion of the necrotic pulp and therefore subsequent resorption. Tetracycline has the additional benefit of decreasing root resorption. For patients not susceptible to tetracycline staining, doxycycline is the antibiotic of choice. Penicillin V has also been shown to be beneficial. The need for analgesics should be assessed on an individual case basis. Mild analgesics are usually adequate, or a non-steroidal anti-

inflammatory drug may be recommended. In cases of environmental contamination a tetanus booster may be required.<sup>7</sup>

Early removal of the pulp has been advocated as this will prevent the production of inflammatory products. Inflammatory resorption appears to occur more rapidly in young patients and the proposed reason for this is that the dentine tubules, which have not yet become less patent as is the case with advancing age, readily transmit inflammatory products from the pulp to the root surface.<sup>2</sup> Pulp removal was performed on the 7<sup>th</sup> day in the present case.

Inflammatory resorption may be arrested by endodontic treatment which removes the source of inflammation, but ankylosis may still occur because of irreversible damage to the periodontal ligament. Use of an intra-canal medicament has been advocated as this has been shown to reduce the occurrence of root resorption. The high p<sup>H</sup> of calcium hydroxide renders it bactericidal and therefore a suitable intracanal dressing is required where inflammatory resorption has occurred.<sup>2</sup> A new strategy of use of intracanal antibiotic and corticosteroid paste is still under investigation.<sup>7</sup>

The root canal can be filled at the practitioner's convenience or, in the case of long-term calcium hydroxide therapy, when an intact lamina dura can be traced. If the endodontic treatment was initiated 7 to 10 days after the avulsion and clinical and radiographic examinations do not indicate pathosis, filling of the root canal at third visit is acceptable although the use of long-term calcium hydroxide is a proven option for these types of cases.<sup>7</sup> In this case, root filling was completed after 7 days of calcium hydroxide placement.

## Conclusion

Although in many cases a reimplanted tooth survives only few years, it was wise to attempt for re-implantation as the patient was in growing up stage. After 12 months' follow-up, none of the features of resorption and ankylosis was evident. So, general people should get the message of urgency of arrival at the dental office with the avulsed tooth/teeth.

## References

1. Moule AJ, Moule CA, The endodontic management of traumatized permanent anterior teeth. *Australian Dental Journal Supplement* 2007; 52: 1.
2. Treatment of avulsed permanent teeth in children. *National Clinical Guidelines. The Royal College of Surgeons, England*; 1997.
3. Management of avulsed permanent anterior teeth in children. *Clinical Practice Guidelines, Oral Health Division Ministry of Health Malaysia*; 2002.
4. Trope M, Blanco L, Chivian N, Sigurdsson A. The role of endodontics after dental traumatic injuries. In: Cohen S, Hargreaves KM. *Pathways of the pulp*. 9<sup>th</sup> edn. St Louis: Mosby, 2006: 620-654.
5. Endodontic considerations in the management of traumatic dental injuries. *Endodontics, Colleagues for Excellence, American Association of Endodontics, Spring* 2006.
6. Flores MT, Andreasen JO, Bakland LK. Guidelines for avulsion and management of traumatic dental injuries. *Dent Traumatol* 2001; 17: 193-198.
7. Trope M. Endodontic considerations in dental trauma. Ingle, Bakland, Baumgartner. *Ingle's Endodontics*. 6<sup>th</sup> edn. Hamilton: BC Decker Inc Hamilton, 2008: 1330-1357.
8. Diangelis JA, Bakland LK. Traumatic Dental injuries: current treatment concepts. *JADA* 1998; 129(10): 1401-1414.