

## Scenario of Fine Needle Aspiration Cytology of Neck Masses in a Tertiary Care Hospital

Md. Atiqur Rahman<sup>1</sup>, Md. Mamun Ali Biswas<sup>2</sup>, Abdul Mannan Sikder<sup>3</sup>

### Abstract

**Background:** Masses in the neck are very common and these may range from inflammatory to neoplastic lesions. Fine needle aspiration cytology (FNAC) is a simple, quick and minimally invasive procedure that is well recognized and widely accepted diagnostic tool in separating inflammatory lesions from cystic and neoplastic lesions of the neck. We designed this study in our populations for evaluation of FNAC of different neck masses and that might facilitate the diagnosis and management of these lesions. **Objectives:** To find out the frequency of different pathological conditions detected on FNAC, to determine the prevalence of neck masses with respect to age and sex and to assert their organs of origin and the nature of the lesions. **Materials and Methods:** This study was conducted in the Department of Pathology, Enam Medical College, Savar, Dhaka from January 2009 to August 2010. The patients of any age and either sex with neck masses were included. Total 526 patients with neck swellings were included in this study. Among these 60.6% were females and 39.4% were males with male to female ratio of 1:1.54. The age of the patients ranged from 10 months to 85 years with mean age of  $32.52 \pm 17.01$  years. **Results:** Of the 526 cases 341 (64.8%) were from lymph nodes, 127 cases (24.2%) from thyroid glands, 32 cases (6.1%) from salivary glands, 14 cases (2.7%) from cysts and 12 cases (2.2%) from soft tissues. FNAC revealed that 86.2% of the lesions were non-malignant which included 60.5% of inflammatory lesions and 25.7% of other benign lesions. Malignant lesions were found in 8% of cases and 5.9% of the cases were categorized as indeterminate follicular neoplasm of the thyroid gland. **Conclusion:** Reactive lymphadenitis is the commonest condition in the neck swellings followed by tuberculous lymphadenitis, nodular goiter and malignant neoplasm, especially metastatic carcinoma.

**Keywords:** Fine needle aspiration cytology (FNAC), Tuberculous lymphadenitis, Malignant neoplasm

J Enam Med Col 2011; 1(1): 8-14

### Introduction

Masses in the neck are very common. Neck is a complex structure having multiple organs. Knowledge of the various facial spaces and anatomical compartments of the neck helps in the differential diagnosis of neck masses.<sup>1</sup> The common pathologies encountered in the neck masses are lymphadenopathies (specific and nonspecific, acute and chronic), metastatic carcinoma, lymphoma,

thyroid swellings (goiter, nodules and cysts) and salivary gland swellings (sialadenitis, cysts, adenomas and carcinomas). The less common pathologies presenting as swelling in the neck are carotid body tumors, branchial cyst, thyroglossal cyst, cystic hygroma, pharyngeal pouch and lumps of skin appendages.<sup>2</sup>

1. Associate Professor, Department of Pathology, Enam Medical College, Savar, Dhaka

2. Assistant Professor, Department of Pathology, Enam Medical College, Savar, Dhaka

3. Professor, Department of Pathology, Enam Medical College, Savar, Dhaka

Correspondence Md. Atiqur Rahman, Email: mdatiq07@gmail.com

Kun M first reported FNAC for cytological evaluation of neck masses in 1847.<sup>3</sup> Martin HE and Ellis EB from Memorial Hospital in USA rediscovered the utility of needle biopsy of head and neck masses.<sup>4</sup> Over the past two decades FNAC has moved to the forefront of the diagnostic test for the evaluation of palpable masses in the head and neck area.<sup>5</sup>

FNAC is a simple, quick and inexpensive method that is used to sample superficial masses like those found in the neck. Masses located within the region of the head and neck, including salivary gland and thyroid gland lesions can be readily diagnosed using this technique.<sup>6,7</sup>

Combination of clinical examination and FNAC remains the mainstay in selecting patients for thyroid surgery.<sup>8</sup> The sensitivity for FNAC for the diagnosis of lymphadenopathy averages 90% with a specificity of 95%. The high degree of diagnostic accuracy, low costs and minimally disruptive nature of the procedure makes FNAC a highly desirable alternative to open biopsy for investigation of cervical lymphadenopathy. FNAC helps to increase the likelihood of an accurate preoperative diagnosis thereby reducing the number of cases requiring excision biopsy; this has significant financial implications.<sup>9</sup>

FNAC has reported diagnostic accuracy in malignant cases that exceed 90%. It is also valuable in the diagnosis of inflammatory, infection and degenerative conditions in which sample can be used for microbiological and biochemical analysis in addition to cytological preparation. FNAC does not give same architectural detail as histology but it can provide cells from the entire lesion as many passes through the lesion can be made while aspirating.<sup>10</sup>

There are many factors that affect the outcome of FNAC, which include the technique of aspiration, the experience of the person who performs it, the size of the mass, the depth of swelling, site of the lesion, image guidance, the proximity to important structures, the vascularity of lump and the expertise of the interpreter.<sup>11</sup>

The present study was carried out to find the frequency of different pathological conditions detected on FNAC, to determine the prevalence of

neck masses with respect to age and sex and to assert their organs of origin and the nature of the lesions.

#### Materials and Methods

This study was conducted in the Department of Pathology, Enam Medical College, Savar, Dhaka during the period from January 2009 to August 2010. FNAC was done on 533 patients who presented with palpable neck masses. The patients of any age and either sex were included in this study. In each instance, a brief history and physical examination along with evaluation of relevant investigations, if available, were carried out.

The FNAC procedure was done using 23 to 25G needle attached to 5 mL or 10 mL disposable syringe. Multiple sites were aspirated. Usually two to four slides were prepared, fixed in 95% ethyl alcohol, and routinely stained by Papanicolaou stain.

Diagnosis was based on cytomorphological features and clinicocytological correlation. The FNAC results were reviewed and analyzed according to the anatomical locations, and the lesions were categorized into various groups of inflammatory, congenital and neoplastic diseases.

#### Results

Among the 533 patients, 7 were excluded from the study as the smears were unsatisfactory. Adequate specimens were obtained from 526 cases for cytological interpretation and no complication was observed. There were 207 (39.4%) male and 319 (60.6%) female patients with male to female ratio of 1:1.54. The age of the patients ranges from 10 months to 85 years with mean age of  $32.52 \pm 17.01$  years. Most of the patients presented in 3<sup>rd</sup> decade followed by 2<sup>nd</sup> and 4<sup>th</sup> decades of life (Fig 1). The main complaint of these patients was neck masses with duration from 1 month to 11 months (average of 4.5 months). The size of the swellings ranged from 0.8 cm to 18 cm. Two hundred twenty seven lesions (43.2%) were up to 2 cm in size whereas 299 lesions (56.8%) were more than 2 cm in diameter. Solitary lesions comprised 448 cases (85.2%) whereas 78 cases (14.8%) had multiple lumps.

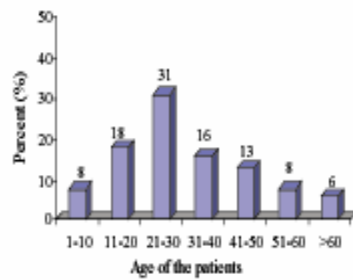


Fig 1. Age distribution of patients with neck masses

Table I: Anatomic locations of neck masses subjected to FNA

Site	Total case	Age range (mean Y)	M/F ratio
Lymph node	341 (64.8%)	10m-85 Y (30.6)	1:1.09
Thyroid	127 (24.2%)	5-79 Y (35.9)	1:8.77
Salivary gland	32 (6.1%)	20-62 Y (41.9)	1:1.13
Cyst	14 (2.7%)	4-65 Y (23.6)	1.8:1
Soft tissue	12 (2.2%)	20-60 Y (35.5)	1.4:1
Total	526	10m-85 Y (32.5)	1:1.54

Anatomic distribution of the neck lesions is shown in Table I. Lymph node (64.8%) was the commonest site aspirated, followed by thyroid gland (24.2%), salivary gland (6.1%), cysts (2.7%) and soft tissue lesions (2.2%).

The spectrum of various lesions according to age groups is depicted in following Tables II, III and IV respectively.

The common cytodiagnosis of the lesions of the neck in the two sexes with relative frequency are given in Table V. The diagnosis encountered most frequently was inflammatory lesions, reported in 60.5% cases, among which reactive and tubercular lymphadenitis, were found in 27.8% and 23.2% of cases, respectively. This was followed by other benign lesions, malignant neoplasms and indeterminate follicular neoplasm of the thyroid gland, which were reported in 25.7%, 8% and 5.8% respectively.

Table II: Spectrum of lymph node lesions

Age group (years)	Reactive hyperplasia		Acute lymphadenitis		Tuberculous lymphadenitis		Lymphoma				Metastatic carcinoma		
	M	F	M	F	M	F	HL		NHL		M	F	
1-10	15	12	2	1	3					1			
11-20	17	17	3	2	13	21					1		
21-30	13	30	2	2	25	31				1			
31-40	6	9	3	9	8	6				1		2	
41-50	7	7	2	5	5	7		1	1		1	4	
51-60	6	2	2	1		1		1	3	1	6	1	
>60	1	4	1	1	1	1							12
M:F	1:1.2		1:1.4		1:1.2		0:2		3.5:1		4.2:1		

M=Male, F=Female, HL=Hodgkin lymphoma, NHL=Non-Hodgkin lymphoma

Table III: Spectrum of thyroid lesions

Age group (years)	Benign Lesion						Inflammatory lesions				Malignant		
	Nodular goiter		Follicular neoplasm		Cystic lesions		Lymphocytic thyroiditis		Hashimoto thyroiditis		M	F	
	M	F	M	F	M	F	M	F	M	F	M	F	
1-10		1				1							
11-20	1	9		4		1							
21-30	1	21	1	8	2	3		2	1	2		2	
31-40		14	2	7	1	5				1			
41-50		8		6		2							
51-60	2	6		3		1							
>60		4			1	4							
M:F	1:15.8		1:9.3		1:3.2		0:2		1:3		0:2		

Table IV: Spectrum of salivary gland lesions

Age group (years)	Inflammatory		Neoplastic			
	M	F	Benign		Malignant	
			M	F	M	F
11-20				1		
21-30			3	5		
31-40	1	2	3	1		
41-50	1	2	1	2	1	1
51-60	1	1	1	1	1	
> 60			2	1		
M: F	1:1.7		1:1.1		2:1	

Patients with lymph node swelling comprised of 163 males and 178 females, and their age ranged from 10 months to 85 years. Reactive lymphadenitis was the commonest cause of lymphadenopathy (42.8%), followed by tuberculosis, acute lymphadenitis, metastatic carcinoma and lymphoma (35.8%, 10.6%, 7.6% and 3.2% respectively). Among the tubercular lymphadenitis epithelioid granuloma without caseation necrosis were in 12 cases, epithelioid granuloma with caseation necrosis in 108 cases and caseation necrosis without granuloma in 2 cases.

Table V: FNAC diagnoses of the neck lesions in two sexes

Sexes	Cytological Diagnosis				Total
	Inflammatory	Benign	Indeterminate	Malignant	
Males	139 (26.4%)	35 (6.7%)	3 (0.6%)	30 (5.7%)	207 (39.4%)
Females	179 (34.1%)	100 (19%)	28 (5.2%)	12 (2.3%)	319 (60.6%)
Total	318 (60.5%)	135 (25.7%)	31 (5.8%)	42 (8%)	526 (100%)

Patients with thyroid swelling comprised of 13 males and 114 females, and their age ranged from 5 to 79 years. The commonest lesion was nodular goiter (52.8%), followed by follicular neoplasm (24.4%). Among the malignant neoplasms two papillary carcinomas were detected.

Patients with salivary gland lesions comprised of 15 males and 17 females, and their age ranged from 20 to 62 years. Salivary gland aspirates were from the parotid in 29 cases and submandibular in 3 cases. Pleomorphic adenomas were reported in 20 cases (62.5%), sialadenitis in 8 (25%), Warthin tumor in one (3.1%), mucoepidermoid carcinoma in 2 (6.3%) and adenoid cystic carcinoma in 1 case (3.1%). All the malignant lesions were from the parotid gland.

Patients with soft tissue lesions comprised of 7 males and 5 females and their ages ranged from 20 to 52 years. Cytologically diagnosed cases were lipoma and hemangioma. The frequency and anatomic distribution of neck cysts are shown in Table VI. Of the 7 congenital cysts, 5 were thyroglossal, 1 branchial and 1 cystic hygroma.

In this study, lymph nodes with metastatic carcinomas were the most common (61.9%) malignant tumors of the neck region, followed by lymphomas (26.2%), carcinoma of the salivary gland (7.1%) and carcinoma of thyroid gland (4.8%). All of the lymphomas were nodal, 2 Hodgkin lymphoma and 9 non-Hodgkin lymphoma; one case was reported from submandibular lymph node and rest from cervical lymph nodes. Among the benign tumors of the neck region, salivary gland adenomas constitute the majority. Of the reported 28 cases, pleomorphic adenomas constituted 21 and Warthin tumor 1 case. These were followed by lipomas and hemangiomas.

Table VI: Frequency of neck cysts- types, locations and age

Types	Number	Sites	Mean age (yrs)
Thyroglossal	5	Neck midline	16
Branchial	1	Upper cervical	35
Cystic hygroma	1	Pre auricular	06
Epidermoid	5	Variable	18
Cutaneous	2	Variable	44

## Discussion

Fine needle aspiration cytology has become established as an investigation of choice in the diagnosis of neck masses because of patient compliance, minimal discomfort and trauma, minimal invasiveness, cost-effectiveness, rapidity, accuracy in most cases and avoidance in surgery in situations where a conservative approach is more preferable.<sup>12</sup> In our study the spectrum of lesion observed from the various regions in the neck confirms its utility as an effective tool in the diagnostic workup of this area.

Among a total of 533 aspirates, 7 were (1.3%) excluded, as they were inadequate. The incidence of inadequate or unsatisfactory samples in various studies has ranged from 0 to 25%.<sup>13</sup> All 526 cases of neck masses were analyzed with their history, clinical presentation, relevant investigations and fine needle aspiration cytology.

The mean age of the patients was  $32.52 \pm 17.01$  years with age range of 10 months to 85 years. Most of the lesions occurred in the 3rd decade of life. Inflammatory lesions were commonly seen in the age group of 31-40 years. Malignant lesions were reported in the older age group. These findings are comparable to that of Tariq N et al.<sup>14</sup> Analysis of the lymph node aspirates from the present study reveal that maximum number of patients (n=178; 52.2%) were in 11-30 years of age group. Thirty five cases (10.3%) were less than 10 years of age. Similar study of lymph nodes conducted by Chhabra S et al<sup>15</sup> reported that maximum number of patients (55.2%) belonged to 10-29 years of age.

Among the 526 cases 207 (39.4%) were males and 319 (60.6%) were females with male to female ratio of 1:1.54. Similar observations of female predominance were found in other studies.<sup>10,16</sup> In the females 179 cases (34.1%) were inflammatory, 100 cases (19%) benign in nature, 12 cases (2.3%) malignant lesion and 28 cases (5.3%) were follicular neoplasm of the thyroid gland. Males had fewer benign lesions, inflammatory lesions and follicular neoplasms but had 30 malignant cases (5.7%) in comparison to the females in whom there were 12 cases (2.3%) of malignancy. In FNAC, follicular adenoma and carcinoma cannot be differentiated because capsular/vascular invasion cannot be seen in the

smears. Hence, they are simply termed as follicular neoplasm, and require histological confirmation.<sup>9</sup> A female predominance of tuberculous lymphadenitis was also noted by this study, with a female to male ratio of 1.2:1. This result is in agreement with another study.<sup>16</sup> However, another study has shown male preponderance.<sup>17</sup>

In this study maximum number of cases were from lymph node (64.8%), followed by thyroid (24.2%) and salivary gland (6.1%). Our results are comparable with the results of Shahid F et al<sup>5</sup> where lymph node aspirates was the commonest (68.7%), followed by thyroid gland (23.9%). These results were different to the findings of Mahrous et al<sup>18</sup> where parotid gland (48%) was the commonest site aspirated, 33% from other sites and 19% from the thyroid gland. Sack M et al<sup>19</sup> showed that the thyroid gland was the commonest site for neck swelling, followed by the parotid gland than other sites. These differences can be attributed to the environmental factors that play role in the nature of neck swellings.

Among the 526 aspirates, 453 cases (86.2%) were non-malignant which included 318 cases (60.5%) of inflammatory lesions and 135 cases (25.7%) of other benign lesions. Malignant lesions were 42 cases (8%) and 31 cases (5.9%) were categorized as indeterminate follicular neoplasms. These findings are consistent with the results reported by Shahid F et al<sup>5</sup>, who found 87.2% cases of benign lesion, 6.8% of indeterminate lesion and 6% of malignant lesions. Ahmad T et al<sup>20</sup> also quoted a similar incidence of benign lesions as 86% and malignant lesions as 14%. However, Cheng et al<sup>21</sup> and Schwarz et al<sup>22</sup> found malignant lesions were the commonest neck lesions, 50% and 48% respectively. This may be attributed to the fact that developed countries, where these studies were carried out show predominance of malignant conditions over benign conditions. Similarly, studies done in developing countries have consistently shown reactive and tuberculous lymphadenitis to be the more common cause.<sup>20</sup>

The spectrum of lymph node lesions in this study showed maximum cases of reactive hyperplasia, which were 146 cases (42.8%). Ahmad S et al<sup>23</sup> also found reactive hyperplasia as the predominant lesion (53.6%). El Hag et al<sup>10</sup> in a similar study in Saudi

Arabia showed reactive lymphadenitis to be the commonest cause of neck masses accounting for 33% cases. In our study tuberculous lymphadenitis was found to be the next common pathology constituting 35.4% of cases which is in concordance with those described by Ahmad S et al.<sup>23</sup> However, in two other studies we find a higher incidence of tuberculous lymphadenitis as 66.9% and 52.8%.<sup>5,14</sup>

Regarding thyroid lesions, our analysis showed 67 cases (52.8%) of goiter, while 31 cases (24.4%) were of follicular neoplasm and cystic lesions were 21 cases (16.5%). Our results were similar to the study by Shahid F et al<sup>5</sup>, which showed 52.4% of nodular goiter and 16.9% of follicular neoplasm, as well as study conducted by Tariq N et al<sup>14</sup> which showed 56.9% of nodular goiter and 23.1% of follicular neoplasm.

Among the salivary gland lesions, the parotid was the most commonly involved gland. Pleomorphic adenoma was the commonest benign tumor (62.5%) and mucoepidermoid carcinoma was the most common malignant tumor. These findings were consistent with the findings of Fernandes et al.<sup>16</sup>

The study concluded that reactive lymphadenitis is the commonest problem in patients presenting with neck swellings in our set-up, followed by tuberculous lymphadenitis, nodular goiter and malignant neoplasms especially metastatic carcinoma. FNAC is a rapid, convenient and accurate method of tissue diagnosis that can be done on out patient basis. FNAC offers a highly effective procedure in the diagnosis and management of palpable neoplastic and non-neoplastic lesions of the neck.

#### References

1. Ansari NA, Derias NW. Origins of fine needle aspiration cytology. *J Clin Pathol* 1997; 50: 541-543.
2. DeMay RM. The art & science of cytopathology. ASCP Press, 1996: 643-649.
3. Kun M. A new instrument for the diagnosis of tumours. *Month J Med Sci* 1847; 7: 853-854.
4. Martin HE, Ellis EB. Biopsy by needle puncture and aspiration. *Ann Surg* 1930; 92(2): 169-181.
5. Shahid F, Mirza T, Mustafa S, Sabahat S, Sharafat S. An

experiential status of fine needle aspiration cytology of head and neck lesions in a tertiary care scenario. *J. basic appl. sci.* 2010; 6(2): 159-162.

6. Celeste NP, Williams JF. Fine needle aspiration biopsy of the head and neck. USA. Butterworth Heinemann, 1996. 1-13.
7. Gamba PG, Messineo A, Antonjello LM et al. A simple exam to screen superficial masses: fine-needle aspiration cytology. *Med Pediatr Oncol* 1995; 24(2): 97-99.
8. Lee JCY, Siow JK. Thyroid surgery: the Tan Tock Seng hospital otolaryngology experience. *Ann Acad Med Singapore* 2002; 31: 158-164.
9. Orell SR, Sterrett GF, Walters MNI, Whitaker D. Manual and atlas of fine needle aspiration cytology, the thyroid gland. Churchill Livingstone, 2003; 110-140.
10. El Hag IA, Chiedozi LC, Reyes FA, Kollur SM. Fine needle aspiration cytology of head and neck masses: seven years' experience in a secondary care hospital. *Acta Cytol* 2003; 47(3): 387-392.
11. Merkle EM, Lewin JS, Aschoff AJ et al. Percutaneous MRI guided biopsy and aspiration in the head and neck. *Laryngoscope* 2000; 111(3): 382-385.
12. Gartner R, Podoshin L, Fradis M. Accuracy of fine needle aspiration biopsy in neck masses. *Laryngoscope* 1984; 94: 1370-1372.
13. Afroze N, Karyani N, Hasan KS. Role of fine needle aspiration cytology in the diagnosis of palpable thyroid lesions. *Indian J Pathol Microbiol* 2002; 45(3): 241-246.
14. Tariq N, Sadiq S, Kehar S, Shafiq M. Fine needle aspiration cytology of head and neck lesions - an experience at the Jinnah Postgraduate Medical Centre, Karachi. *Pakistan Journal of Otolaryngology* 2007; 23: 63-65.
15. Chhabra S, Mohan H, Bhat A. A retrospective histological evaluation of non-neoplastic superficial lymphadenopathy. *The Internet Journal of Internal Medicine* 2006. Available from: <http://www.ispub.com/journal/the-internet-journal-of-internal-medicine/volume-6-number-4/a-retrospective-histological-evaluation-of-non-neoplastic-superficial-lymphadenopathy.html>.
16. Fernandes H, D'souza CRS, Ebejuswini BN. Role of FNAC in palpable head and neck masses. *Journal of Clinical and Diagnostic Research* 2009; 3(5): 1719-1725.
17. Wiwatworapan T, Anantasetagbon T. Extra-pulmonary tuberculosis at a regional hospital in Thailand. *Southeast Asian J Trop Med Public Health* 2008; 39(3): 521-525.

18. Mahrous AK, Hashem AEH, Elsayy MM, Abdesallam HA, Elfattah AMA. Evaluation of fine needle aspiration cytology (FNAC) in diagnosis of head and neck swellings in Bab Elsheria Hospital. *The Egyptian Journal of Hospital Medicine* 2007; 27: 122-127.
19. Sack MJ, Weber RS, Weinstein GS, Challion A, Neisenbaum HL, Yousem DM. Image guided FNA of the head and neck: five years' experience. *Arch Otolaryngol Head Neck Surg* 1998; 124(10): 1155-1161.
20. Ahmad T, Naeem M, Ahmad S, Samad A, Nasir A. Fine needle aspiration cytology (FNAC) and neck swellings in the surgical outpatient. *J. Ayub Med Coll Abbottabad* 2008; 20(3): 30-32.
21. Cheng AT, Derman B. Fine needle aspiration cytology: the Auckland experience. *Aust N Z J Surg* 1992; 62(5): 368-372.
22. Schwarz R, Chajn NH, MacFarlane JK. Fine needle aspiration cytology in the evaluation of head and neck masses. *Am J Surg* 1990; 159(5): 482-485.
23. Ahmad S, Akhtar S, Akhtar K, Naseem S, Mansoor T. Study of fine needle aspiration cytology in lymphadenopathy with special reference to acid-fast staining in cases of tuberculosis. *JK science* 2005; 7(1): 1-4.