

Lupus Vulgaris Causing Nasal Destruction: Rare Presentation in Current Time

Md. Rokon Uddin¹, Farzana Akhter², Ahmed Minhaz Shumon³

Abstract

A 42-years old lady reported with slowly progressive reddish lesions over the nose, followed by atrophy and ulceration for about 6 years. Clinical examination revealed atrophied, ulcerated, erythematous lesions over central face, forehead and neck destroying whole nose. Mantoux test resulted 16×18 mm on 48 hours observation. Histopathological examination of the lesion showed noncaseating granuloma along with Langhans giant cells in the upper dermis surrounded by lymphocytes. The conclusive diagnosis was lupus vulgaris based on above findings. Six months therapy with INH 300 mg plus rifampicin 600 mg supplemented by initial 2 months ethambutol 1000 mg plus pyrazinamide 1500 mg daily resulted clean-looking perforation with healthy margin.

Key words: *Lupus vulgaris, Nose destruction, Lymphadenitis, Skin TB*

J Enam Med Col 2011; 1(1): 43-45

Introduction

Tuberculosis is quite common in Bangladesh. Lupus vulgaris is an extremely chronic, progressive and the commonest form of cutaneous tuberculosis occurring in individuals with moderate immunity and high degree of tuberculin sensitivity.¹ Lupus vulgaris may appear at sites of inoculation in scrofuloderma scars, or most commonly at distant sites from the initial infectious focus, probably by hematogenous dissemination.¹ The disease commonly affects the nose and nasal cartilages.² Lupus vulgaris usually appears as a single plaque composed of grouped red-brown papules. The papules tend to heal slowly in one area and progress to another. They are minute, translucent and embedded deeply and diffusely in the infiltrated dermis, expanding by the development of new papules at the periphery, which coalesce with the main plaque.³ Lupus vulgaris lesions of head and neck can at times be associated with lymphangitis or

lymphadenitis. If lesions involve the nose or the lobes of the ears, these structures are shrunken and scarred, as if nibbled away and the whole nose may be destroyed, and only the orifices and posterior parts of the septum and turbinate visible.¹ We are reporting a case of lupus vulgaris involving nose, face and neck presented with destruction of whole nose, scarring upper lip, central face and associated with lymphadenitis.

Case Report

A 42-years old lady presented with 6 years history of reddish lesions over the nose, followed by ulceration at the same site. The ulcer was increasing in size despite previous treatment with several courses of broad spectrum systemic antibiotics and subsequently destruction of whole nose. There was no positive history of tuberculosis among her family

1. Associate Professor, Department of Skin & VD, Enam Medical College & Hospital, Savar, Dhaka

2. Junior consultant, Skin & VD, Upazila Health Complex, Savar, Dhaka

3. Associate Professor, Department of Ear, Nose & Throat, Enam Medical College & Hospital, Savar, Dhaka

correspondence Md. Rokon Uddin, E-mail: drrokon47@gmail.com; +8801711-392013

members. She had received BCG vaccination in childhood. Clinical examination revealed atrophic, ulcerated, erythematous lesions over central face, forehead and neck. Atrophy and scarring were observed in upper and lower lips, both cheeks and forehead with destruction of whole nose. Some areas of the face were covered with brownish crusts. Central ulcer destroyed the whole nose, only orifices and posterior parts of the septum and turbinates were visible. On right lateral side of neck there were erythematous, crusted, oozing lesions with lymphadenopathy. [Figs A, B]. No other abnormality was found on examination of other systems.



Fig: A



Fig: B

Biopsy from forehead showed noncaseating granuloma along with Langhans giant cells in the upper dermis, surrounded by lymphocytes [Fig C]. Special stain for acid-fast bacilli, LD bodies, other bacteria were negative. Routine laboratory investigations including complete blood counts, biochemical profile, liver function tests, urine analysis and chest x-ray were normal. Serology for

syphilis, ELISA for human immunodeficiency virus (HIV), sputum for acid-fast bacilli and antinuclear antibodies were negative. An intradermal tuberculin test (Mantoux test) was highly positive with an induration of 16×18 mm.

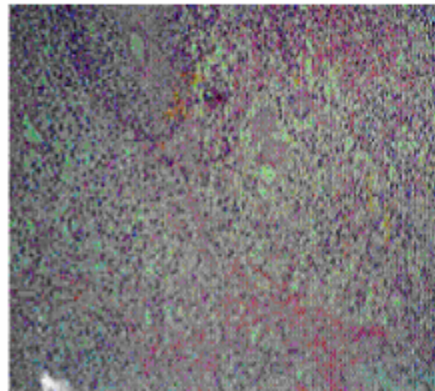


Fig C: Focus under light microscope with noncaseating granuloma in dermis

The various differential diagnoses considered were lupus vulgaris, Leishmaniasis, Hansen's disease, Wegener's granulomatosis and sarcoidosis. However, based on clinical features, histopathology and highly positive tuberculin test, lupus vulgaris was regarded as the most likely diagnosis. Antituberculous therapy was started. Clinical improvement was observed within one month and at the end of six months therapy, ulcerated plaque had completely resolved. A clean looking perforation with healthy margin was present, which was surgically repaired and closed to achieve an acceptable cosmetic appearance.

Discussion

Lupus vulgaris patients usually have moderate or high degree of immunity. This patient had positive Mantoux test to support this criterion. The sites which commonly involved are nose, cheek, ear lobe or scalp and slowly extend into adjacent region. Other areas are rarely involved. This patient's lesion was also over central face which supports the criteria. Usually in lupus vulgaris papules tend to heal slowly in one area and progresses to another. They are minute, translucent and embedded deeply and diffusely in the infiltrated dermis, expanding by the development of new papules at the periphery which coalesce with the main plaque. The disease is destructive, frequently

ulcerates and on involution leaves deforming scars as it slowly spreads peripherally over the years. Lupus lesions of head and neck can at times be associated with lymphangitis or lymphadenitis.¹ If lesions involve the nose or ear lobes, the structures are shrunken and scarred, as if nibbled away. On examination, atrophy and scarring were observed in upper and lower lips, both cheeks, forehead with destruction of whole nose. Right cervical lymphadenopathy was present. These happened very slowly for about 6 years. All these criteria fit with typical presentation of lupus vulgaris. Histopathology of skin showed noncaseating granulation along with Langhans giant cells in upper dermis surrounded by lymphocytes, which fit with the histopathological

findings of lupus vulgaris. Complete clearance of ulcerated plaque, clean looking perforation with healthy margin after treatment with antitubercular regime is strongly suggestive of its tubercular origin.

References

1. WD James, TG Berger, DM Elston (eds). *Andrews' disease of the skin: clinical dermatology*. 11th edn. USA: Elsevier, 2006: 325-326.
2. Sehgal VN, Wagh SA. Cutaneous tuberculosis: current concepts. *Int J Dermatol* 1990; 29: 237-252.
3. K Wolff, LA Goldsmith, SI Katz, BA Gilchrist, AS Paller, DJ Lefell (eds). *Fitzpatrick's dermatology in general medicine*. 7th edn. New York: McGraw Hill, 2008: 1768-1775.