



Behavior of Non-Hybrid and Hybrid Forms of Fibro-Osseous Lesions in The Craniomaxillofacial Region of Patients Attending at The Tertiary Hospital at Dhaka City



Abu Mohammad Shahed¹, Mohiuddin Ahmed², Motiur Rahman Molla³,
Md. Rezaul Huq⁴, Bilquis Ara Begum⁵

¹Assistant Professor & Head, Department of Oral & Maxillofacial Surgery, Dhaka Medical College & Hospital, Dhaka, Bangladesh;

²Professor Department of Oral & Maxillofacial Surgery, Sapporo Dental College, Dhaka, Bangladesh; ³Ex. Professor & Chairman, Department of Oral & Maxillofacial Surgery, Bangabandhu Sheikh Mujib Medical University, Dhaka, Bangladesh; ⁴Professor & Former Head, Department of Oral & Maxillofacial Surgery, Principal of Pioneer Dental College. Dhaka, Bangladesh; ⁵Ex. Associate Professor, Department of Biochemistry, Dhaka Medical College, Dhaka, Bangladesh

Abstract

Background: Fibro-osseous lesions of the craniofacial complex are represented by a variety of disease processes that are characterized by the nature of ossifications and calcifications. **Objective:** The purpose of the present study was to see the behavior of non-hybrid and hybrid forms of fibro-osseous lesions. **Methodology:** This was a cross-sectional study at the Department of Oral & Maxillofacial Surgery of Dhaka Dental College & Hospital, Dhaka (DDCH), Shaheed Suhrawardi Hospital, Dhaka (SSH) and Bangabandhu Sheikh Mujib Medical University (BSMMU) from January 2004 to December 2005. Participants were selected for the study who attended into outpatient and inpatient departments with fibro-osseous lesions during study period, irrespective of age & sex. patients were included who gave informed consent, patients attended with jaw swellings, and radiologically suspecting as fibro-osseous lesions, Biopsy proven fibro-osseous lesions. All patients were advised initially for radiological examination which includes orthopantomogram (OPG), postero-anterior (P/A) view of skull with mandible, lateral view of skull with mandible. After taking informed consent, biopsy was done. The diagnosis was established initially in all cases preoperatively on the basis of an incision biopsy. As soon as tissue was removed, it was then immersed into a preservative considering 10% neutral buffer formalin as ideal for 24 to 48 hours. Before immersing in a preservative solution, the specimen was rinsed in normal saline to remove excess blood. Postoperatively every surgical specimen was examined carefully and sectioned to examine the nature of tissue within the tumour and examination of the expansion and perforation of the bone was performed. Then histologic examination was done for re-evaluation. **Results:** A total number of 40 patients were included, in Hybrid form, the growth pattern of majority of swellings were slow at first but later rapid (66.7%) while in Non-hybrid form, it was slow always (61.8%). Maximum site of involvement was in mandible (66.7%) in Hybrid form whereas both mandible and maxilla were equally involved in Non-hybrid form. Hybrid form has significantly higher probability of tenderness in comparison with Non-hybrid form ($p < 0.001$). Tenderness was found in all cases of hybrid form (100%) whereas in Non-hybrid form it was 17.6%. Most of size of Non-hybrid swellings were less than 35 sq. cm but for Hybrid form the size were comparatively bigger. In Non-hybrid form, only 2.9% of swellings were hard and egg shell crackling but it was 33.3% for Hybrid form and the difference was significant. **Conclusion:** In conclusion the behavior of non-hybrid and hybrid forms of fibro-osseous lesions is varied from each other. [Journal of National Institute of Neurosciences Bangladesh, July 2023;9(2):136-140]

Keywords: Hybrid forms; Fibro-osseous lesion; Non-Hybrid forms; Fibro-osseous lesion; ossifying fibroma; cementifying fibroma and cemento-ossifying fibroma

Introduction

Fibro-osseous lesions characteristically demonstrate replacement of normal bone architecture by a benign fibrous tissue containing varying amount of mineralized

material such as cementum, osteoid and woven¹. It has been suggested by Hammer et al. that fibro-osseous lesions other than fibrous dysplasia arise from multipotential mesenchymal blast cells situated in the

Correspondence: Dr Abu Mohammad Shahed, Assistant Professor & Head, Department of Oral & Maxillofacial Surgery, Dhaka Medical College & Hospital, Dhaka, Bangladesh; Email: abu.shahed1965@gmail.com; Cell no: +8801552323023

ORCID: <https://orcid.org/0009-0007-1551-6826>

©Authors 2023. CC-BY-NC

periodontal membrane that have the capacity to produce cementum, bone and fibrous tissue. Fibrous dysplasia, ossifying fibroma, cemento-ossifying fibroma all have microscopically identical areas of fibro-osseous proliferation. In addition to fibro-osseous zones, the cemento-ossifying fibroma has a large component of basophilic spherules that traditionally have been interpreted as cementum and this lesion becomes a distinctive pathologic entity than any other fibro-osseous condition. There is special variety named "Hybrid" type which is a combination of aneurysmal bone cyst with one or more fibro-osseous lesions. In 1983, Kramer stated that the occurrence of hybrid fibro-osseous lesions, exemplifying the histological heterogeneity of the group, has become increasingly recognized though to date infrequently documented. Adekeye et al. have cited the combination of aneurysmal bone cyst with the early active phase of fibrous dysplasia in producing an aggressive dysplastic rather frankly neoplastic tumor². There may be another form of hybrid lesion within the fibro-osseous spectrum demonstrating the different histological features of aneurysmal bone cyst, ossifying fibroma and cementifying fibroma³. ABC is indicative of pathophysiological change rather than a true cyst or aneurysm. It is a benign nonneoplastic bone lesion characterized by the presence of numerous blood-filled, usually nonendothelialized cavities. ABC is considered to be a secondary vascular phenomenon superimposed as an existing pathological process of bone. A primary bone lesion initiates an osseous, arteriovenous fistula, which creates, via its haemodynamic forces, a secondary reactive lesion of bone, the ABC. Among the associated bone lesions are unicameral bone cysts, giant cell tumors, nonossifying fibroma and fibrous dysplasia⁴. ABC arising from fibrous dysplasia have been reported as case reports but the frequency has not been reported in large series⁵. The majority were presented as painful swelling over a short period and rarely spontaneous recurrent haemorrhage which may clinically simulate sarcomatous transformation of fibrous dysplasia. When fluid-fluid levels are demonstrated within fibrous dysplasia on CT and MRI⁶, it may be associated with sarcomatous transformation of fibrous dysplasia, simple cystic degeneration of fibrous dysplasia, secondary midphase ABC or a combination of these processes.

The clinical course of fibrous dysplasia is unpredictable, although most of the lesions tend to stabilize with the onset of puberty, others may undergo secondary ABC development from being static fibrous dysplasia for a long time or malignant transformation with the frequency

of 0.5% of patients with monostotic fibrous dysplasia and 4% of patients with polyostotic fibrous dysplasia or McCune-Albright syndrome⁷ and involves transformation into osteosarcoma, fibrosarcoma or chondrosarcoma.

ABC itself can completely alter the morphology of the preexisting bone tumor, with clinical manifestations simulating malignant change. This process may be aggressive and can change remarkably and quickly.

Occasionally cemento-ossifying and ossifying fibroma may occur in gigantic form and there is high prevalence of ABC formation in these lesions exhibiting aggressive nature although none have been known to metastasize. The formation of ABC in giant lesions is probably due to prominent fibrous component which contains more loose edematous areas than in smaller ossifying fibromas⁸. Hamner et al. defined giant lesions as those exceeding 2x2 cm in size or involving the space occupied by two or more teeth. The giant lesion is related to rural character of population where proper diagnosis and treatment are often misleading and delayed due to poor socio-economic status, lack of awareness and poor referral system. Van Heeden et al¹¹. reported 8 giant lesions exhibiting focal areas of ABC formation. Struthers and Shear⁹ found this change in only 4% of their ossifying fibromas and Eversole et al¹⁰. In 3 out of 64 cases.

Methodology

Study Settings and Population: It was Cross-sectional observational type of study at the Department of Oral & Maxillofacial Surgery of Dhaka Dental College & Hospital, Dhaka (DDCH), Shaheed Suhrawardi Hospital, Dhaka (SSH). And Bangabandhu Sheikh Mujib Medical University (BSMMU) from January 2004 to December 2005. A total 40 participants were selected for the study who attended outpatient and inpatient departments with fibro-osseous lesions during study period, irrespective of age & sex. patients were included who gave informed consent, patients attended with jaw swellings, and radiologically suspecting as fibro-osseous lesions, Biopsy proven fibro-osseous lesions. Patients were excluded who had not been clinically or radiologically susceptible for fibro-osseous lesions, Psychotic patients and Pregnant women.

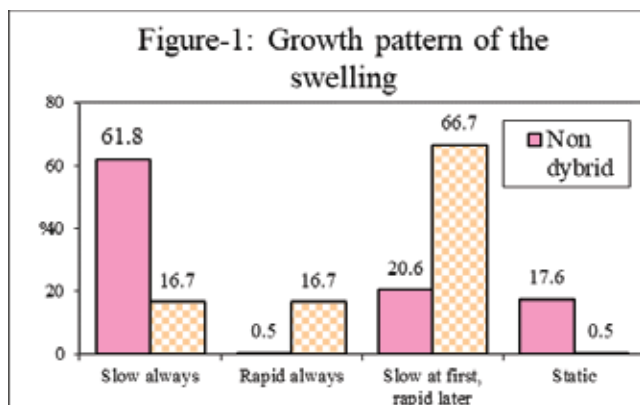
Study Procedure: A standardized structured data collection sheet was used to collect necessary information of the study history of the patients and clinical examination; radiology, histopathology and macroscopic findings of surgical specimen were recorded. All patients were advised initially for

radiological examination which includes orthopantomogram (OPG), postero-anterior (P/A) view of skull with mandible, lateral view of skull with mandible. After taking informed consent, biopsy was done. The diagnosis was established initially in all cases preoperatively on the basis of an incision biopsy. The tissue was processed for preparation of slide and stain with haematoxylin and eosin to study under a light microscope. After incision and reflection of mucoperiosteum, bony window was made by rongeurs, drill bur or chisel according to need. As soon as tissue was removed, it was then immersed into a preservative considering 10% neutral buffer formalin as ideal for 24 to 48 hours. Before immersing in a preservative solution, the specimen was rinsed in normal saline to remove excess blood. Postoperatively every surgical specimen was examined carefully and sectioned to examine the nature of tissue within the tumour and examination of the expansion and perforation of the bone was performed. Then histologic examination was done for re-evaluation.

Data Analysis: All the data were analyzed after thorough checking, cleaning, editing and compiling by the software SPSS.window V-11.6. Descriptive statistics were followed first and then appropriate statistical tests were performed to find out the association between different variables when and where necessary.

Results

During the period of January 2004 to December 2005 a total number of 40 consecutive patients were studied, those were attending in outpatient and inpatient department of DDCH, SSH and BSMMU based on inclusion and exclusion criteria. Among the studied population 34 were non-hybrid and rest 6 (15%) were



p> .05 Not significant, p< .05 Significant at 95% level, p<.01 Significant at 99% level

Figure I: Growth pattern of the swelling

hybrid form.

In Hybrid form, the growth pattern of majority of swellings were slow at first but later rapid (66.7%) while in Non-hybrid form, it was slow always (61.8%). This pattern of growth differs significantly ($\chi^2 = 12.5, p < .01$) (Figure I).

Duration of onset of swelling was from 6-12 months (66.7%) in Hybrid form, whereas in Non-hybrid form it was comparatively long duration. The figure shows the percentage of patients suffering from fibro-osseous lesions with different duration (Figure II).

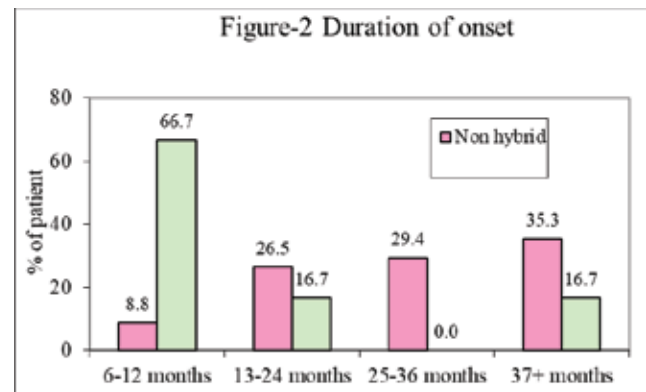


Figure II: Duration of onset of Fibro-osseous lesion

Maximum site of involvement was in mandible (66.7%) in Hybrid form whereas both mandible and maxilla were equally involved in Non-hybrid form (47.1%) (Figure III)

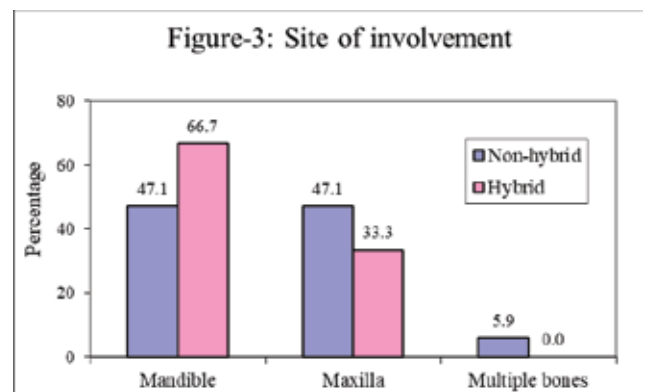


Figure III: Site of Involvement of Fibro- Osseous Lesion

Most of size of Non-hybrid swellings were less than 35 sq. cm but for Hybrid form the size were comparatively bigger (Table 1).

Hybrid form has significantly higher probability of tenderness in comparison with Non-hybrid form (p < 0.001). Tenderness was found in all cases of hybrid form (100%) whereas in Non-hybrid form it was 17.6% (Table 2).

Table 1: Distribution of Swellings by Size

Size	Non-hybrid	Hybrid	Total
1-15 sq cm	10 (29.4%)	0 (0%)	10 (25%)
16-35 sq.cm	22 (64.7%)	3 (50%)	25 (62.5%)
36+ sq. cm	2 (5.9%)	3 (50%)	5 (12.5%)
Total	34 (100%)	6 (100%)	40 (100%)

Table 2: Distribution of Swelling by Tenderness

Tenderness	Non-hybrid	Hybrid	P Value
Absent	28(82.4%)	0(0.0%)	
Present	6(17.6%)	6(100.0%)	<0.001
Total	34 (100%)	6 (100%)	

In Non-hybrid form, only 2.9% of swellings were hard and egg shell crackling but it was 33.3% for Hybrid form and the difference was significant ($p < 0.01$), p value is reached from unpaired student's t test (Table 3)

Table 3: Distribution of swellings by consistency

Consistency	Non-hybrid	Hybrid	P Value
Hard	32(94.1%)	3(50%)	
Firm	0(0%)	1(16.7%)	
Hard and egg shell crackling	1(2.9%)	2(33.3%)	<0.01
Firm and egg shell crackling	1(2.9%)	0(0%)	
Total	34 (100%)	6 (100%)	

Recurrent bleeding from the swellings was noted in few cases of hybrid form (33.3%) but it was noted in minority of non-hybrid form (5.9%) (Table 4).

Table 4: Status of Types of Bleeding

Recurrent bleeding	Non-hybrid	Hybrid	P Value
Yes	2 (5.9%)	2 (33.3%)	
No	32(94.1%)	4(66.7%)	<0.05
Total	34 (100%)	6 (100%)	

Discussion

During the period of January 2004 to 2005 a total number of 40 consecutive patients were studied those were attending outpatient and inpatients of Oral and Maxillofacial Surgery department at DDCH, SSH and BSMMU. The study population were clinically and radiologically suspected and confirmed histologically fibro-osseous lesions of the jaws based on inclusion and exclusion criteria. Among the studied population, 34 patients were non-hybrid and the rest 06 were hybrid form and were diagnosed by proper imaging and histological examination.

In our study, the growth pattern of the hybrid type was "slow at first but later rapid" (66.7%) while in non-hybrid it was "slow always" (61.8%) which differed significantly between the two forms ($\chi^2 = 12.5$, $p < 0.01$). Posnick JC et al a more aggressive, non-disabling approach to these benign yet deforming fibro-osseous growths is possible. Hybrid form lesions had significantly higher prevalence of tenderness in comparison with non-hybrid form ($p < 0.001$). Tenderness were found in all cases (100%) whereas it was 17.6% in non-hybrid lesions.

Consistency of swelling of fibro-osseous lesions are from firm to hard. When fibrous dysplasia is matured, it becomes completely hard. But, the ossifying fibroma, is initially hard but gradual progressive expansile growth may ultimately produce expansion and thinning of cortex resembling egg-shell crackling sensation. Crusoé-Rebello I et al¹² had similar findings of our study. In our study, only 2.9% of swelling of non-hybrid form exhibited hard and egg-shell crackling consistency whereas it was 33.3% for hybrid form and this difference was significant ($p < 0.01$).

Normally no bleeding is encountered in fibro-osseous like benign lesions. But, whenever, there is secondary ABC formation within primary fibro-osseous lesion, majority of hybrid form present as acute onset of pain with rapid exacerbation over a short period of time with occasional presentation of spontaneous recurrent haemorrhage around the lesion⁸.

In this study, recurrent haemorrhage from hybrid form was noted in a few cases (33.3%) whereas minority of non-hybrid form (5.9%) presented with this complication. Odds ratio was 8 which indicated that hybrid form had 8 times higher risk of recurrent haemorrhage compare to non-hybrid form ($p < 0.05$).

Conclusion

In conclusion, it can be predicted that whenever there is secondary ABC transformation within pre-existing fibro-osseous lesion, its clinical behaviour Egg-shell crackling sensation and loosening of tooth were detected clinically and becomes quite different from the previous ones and manifest aggressiveness in the form of acute onset of pain with rapid exacerbation over a short period of time with occasion recurrent bleeding.

Acknowledgements

None

Conflict of interest

There is no conflict of interest relevant to this paper to disclose.

Funding agency

None

Contribution to authors

Shahed AM, Ahmed M were involved in protocol preparation, data & sample collection and literature search and manuscript writing. Molla MR, Huq MR, Begum BA were involved in sample preparation and testing. All the authors have read and approved the final version of the manuscript.

Data Availability

Any inquiries regarding supporting data availability of this study should be directed to the corresponding author and are available from the corresponding author on reasonable request.

Ethics Approval and Consent to Participate

Ethical approval for the study was obtained from the Institutional Review Board. As this was a prospective study the written informed consent was obtained from all study participants. All methods were performed in accordance with the relevant guidelines and regulations.

How to cite this article: Shahed AM, Ahmed M, Molla MR, Huq MR, Begum BA. Behavior of Non-Hybrid and Hybrid Forms of Fibro-Osseous Lesions in The Craniomaxillofacial Region of Patients Attending at The Tertiary Hospital at Dhaka City. *J Natl Inst Neurosci Bangladesh*, 2023;9(2):136-40

Copyright: © Shahed et al. 2023. Published by Journal of National Institute of Neurosciences Bangladesh. This is an open access article and is licensed under the Creative Commons Attribution Non Commercial 4.0 International License (CC BY-NC 4.0). This license permits others to distribute, remix, adapt and reproduce or changes in any medium or format as long as it will give appropriate credit to the original author(s) with the proper citation of the original work as well as the source and this is used for noncommercial purposes only. To view a copy of this license, please See: <https://creativecommons.org/licenses/by-nc/4.0/>

ORCID:

Abu Mohammad Shahed: <https://orcid.org/0009-0007-1551-6826>

Mohiuddin Ahmed: <https://orcid.org/0009-0007-1560-1326>

Motiur Rahman Molla: <https://orcid.org/0000-0002-7812-2425>

Md. Rezaul Huq: <https://orcid.org/0009-0003-8234-2783>

Bilquis Ara Begum: <https://orcid.org/0000-0002-7812-2425>

Article Info

Received on: 7 April 2023

Accepted on: 24 May 2023

Published on: 1 July 2023

References

1. Waldron CA (1970). Fibro-osseous lesions of the jaws. *Oral Surg*, 28, 58-64.
2. Adekeye, EO; Edwards, MB and Goubran, GF (1980). Fibro-osseous lesions of the skull, face and jaws in Kaduna, Nigeria. *British Journal of Oral Surgery*, 18: 57-72.
3. Blayney AW, Tayeb AA; The "hybrid" benign fibro-osseous lesion. *The Journal of Laryngology and Otology*, March, 1986. Vol 100: 291-302.
4. Waldron CA. Fibro-osseous lesions of the jaws. *J Oral Maxillofac Surg* 1985; 43: 249-262
5. Itshayek E, Spector S, Gomori M, Segal R. Fibrous dysplasia in combination with Aneurysmal bone cyst of the occipital bone and the clivus: Case report and review of the literature. *Neurosurgery*. Vol 51, No. 3, Sep 2002: 815- 817.
6. Som PM, Schatz CJ, Flaum EG, Lanman TH. Aneurysmal bone cyst of the paranasal sinuses associated with Fibrous dysplasia: CT and MR findings. *J Comput Assist Tomogr*, Vol. 15, No. 3, 1991: 513-515.
7. Ruggieri P, Sim FH, Bond JR, et al.: Malignancies in Fibrous dysplasia. *Cancer* March 1, 1994, Vol. 73, No.5 : 1411-1424.
8. Van Heerden et al. Giant ossifying fibroma: a clinicopathologic study of 8 tumours. *J Oral Pathol Med* 1989; 18: 506-509.
9. Struthers PJ, Shear M. Aneurysmal bone cyst of the jaws(II). Pathogenesis. *Int J Oral Surg* 1984; 13: 92-100.
10. Eversole LR, Leider AS, Nelson K. Ossifying fibroma: a clinicopathologic study of sixty-four cases. *Oral Surg*, 1985; 60: 505-600.
11. Itshayek E, Spector S, Gomori M, Segal R. Fibrous dysplasia in combination with Aneurysmal bone cyst of the occipital bone and the clivus: Case report and review of the literature. *Neurosurgery*. Vol 51, No. 3, Sep 2002: 815- 817.
12. Crusóé-Rebello I, Torres MG, Burgos V, Oliveira C, Santos JD, Azevedo RA, Campos PS. Hybrid lesion: central giant cell granuloma and benign fibro-osseous lesion. *Dentomaxillofacial Radiology*. 2009 Sep;38(6):421-5.