

Anterior Cervical Arachnoid Cyst in A Child: A Case Report

DM Arman¹, Sheikh Muhammad Ekramullah², Sudipta Kumer Mukherjee³,
Misbahuddin Ahmed⁴, MA Quddus Mia⁵, Naila Huq⁶

¹Assistant Professor, Department of Paediatric Neurosurgery, National Institute of Neurosciences and Hospital, Dhaka, Bangladesh;

²Professor & Head, Department of Paediatric Neurosurgery, National Institute of Neurosciences and Hospital, Dhaka,

Bangladesh; ³Assistant Professor, Department of Paediatric Neurosurgery, National Institute of Neurosciences and

Hospital, Dhaka, Bangladesh; ⁴Assistant Professor, Department of Neurospine, National Institute of Neurosciences

and Hospital, Dhaka, Bangladesh; ⁵Consultant (Neuroanaesthesia), National Institute of Neurosciences and

Hospital, Dhaka, Bangladesh; ⁶Associate Professor, Department of Neuropathology, National Institute

of Neurosciences and Hospital, Dhaka, Bangladesh

[Reviewed: 21 January 2016; Revised: 6 March 2016; Accepted: 11 December 2016; Published: 1 January 2017]

Abstract

Intradural arachnoid cysts involving the spine are uncommon and especially rare in an anterior cervical location. In the literature, among 15 patients, 8 were in the paediatric age group and in 3 patients the cyst was localized to the full length of the cervical spinal canal. Although they occur secondary to trauma, haemorrhage, surgery or inflammation, most of them are known to be idiopathic or congenital. Although the disease shows a dramatic neurological course, early diagnosis and treatment could provide good results. In the paediatric age group, cervical anterior intradural arachnoid cyst is an unusual cause of quadriplegia. The rarity of this condition and the relevance of MRI in the accurate and early diagnosis is discussed here. A 4 year-old girl with a intradural arachnoid cyst extending from C4 to C7 situated anteriorly is reported here; diagnosis and treatment modalities are discussed. [Journal of National Institute of Neurosciences Bangladesh, 2017;3(1): 52-56]

Keywords: Anterior cervical; arachnoid cyst; child; intradural; Spinal arachnoid cyst

Correspondence: Dr. D.M. Arman, Assistant Professor, Department of Paediatric Neurosurgery, National Institute of Neurosciences and Hospital, Sher-E-Bangla Nagar, Agargaon, Dhaka, Bangladesh; Email: armandmdr@yahoo.com; Cell no.: +8801745771780

Contribution to authors: Arman DM, Ekramullah SM, Mukherjee SS have clinically diagnosed the case the manage the case. Arman DM has written the manuscript. Ahmed M and Mia MAQ have revised the manuscript. Huq N has diagnosed the case histopathologically.

How to cite this article: Arman DM, Ekramullah SM, Mukherjee SS, Ahmed M, Mia MAQ, Huq N. Anterior Cervical Arachnoid Cyst in A Child: A Case Report. J Natl Inst Neurosci Bangladesh, 2017;3(1): 52-56

Copyright: ©2017 Arman et al. Published by Journal of National Institute of Neurosciences Bangladesh. This article is published under the Creative Commons CC BY-NC License (<https://creativecommons.org/licenses/by-nc/4.0/>). This license permits use, distribution and reproduction in any medium, provided the original work is properly cited, and is not used for commercial purposes.

Introduction

Arachnoid cysts are congenital lesions that arise during development from the splitting of the arachnoid membrane and contain fluid that is usually identical to CSF¹. Rarely, arachnoid cysts may follow infection or trauma. Arachnoid cysts in the spine are rare and are seldom a cause of spinal cord compression. In the spine region they almost always communicate with the intrathecal subarachnoid space through a small defect in the dura². Usually asymptomatic, in some cases can cause local and radicular pain, motor weakness of extremities, sensory disturbances, ataxia, and sphincter disturbances. The mainstay of treatment in patients with

neurological symptoms is surgical removal of the cyst, together with ligation of the communicating pedicle and closure of the dural defect¹.

In the modern era of neuroimaging, these lesions can also be discovered incidentally. Once the cyst has been diagnosed, typically by MRI, surgery is usually performed to prevent further spinal cord or nerve root compression. Depending on the location of the cyst and the duration and degree of spinal cord compression, postoperative outcomes vary substantially. Some degree of improvement is reported in 45.0% to 70.0% of cases following surgery, and complete elimination of symptoms is reported in 20.0% to 30.0% of cases².

Most SACs are extradural and arise dorsal to the spinal cord^{3,4}. Many cases of intradural cysts and some rare cases of intramedullary cysts have been reported². Generally speaking, extradural SACs are resected, whereas intradural SACs are usually fenestrated. Although they most commonly develop in the thoracic

region, SACs may arise at any spinal level². The mechanism of formation and enlargement of SACs is likely multifactorial, and numerous theories have been proposed².

Anteriorly located arachnoid cysts are exceptional, particularly those occurring in the cervical spinal

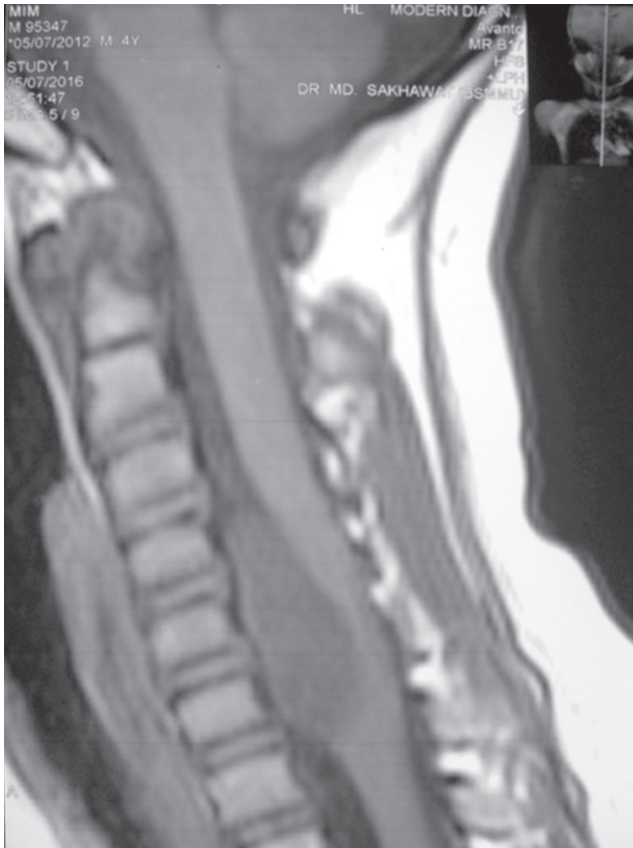


Figure 1a: T1 weighted magnetic resonance image (MRI), sagittal view showing hypointense lesion anterior to the cord at C4-C7 level

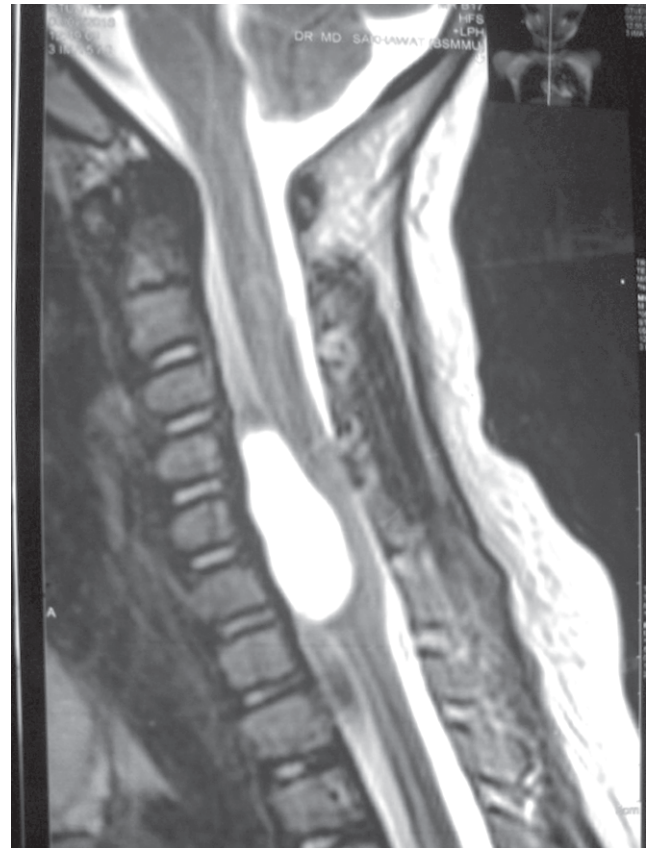

Figure 1b: T2 weighted MRI demonstrating hyperintense cyst at C4-C7 level of the same patient

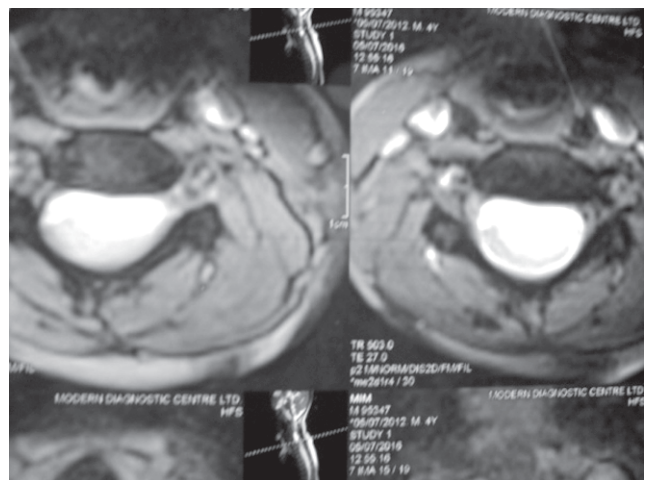
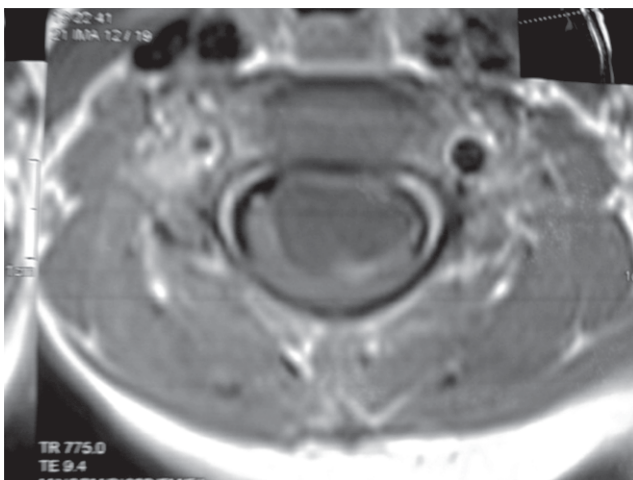


Figure 2a: T1 magnetic resonance images of the case showing an anteriorly located hypointense lesion compatible with a cyst; 2b. T2 weighted MRI of the case showing a hyperintense lesion

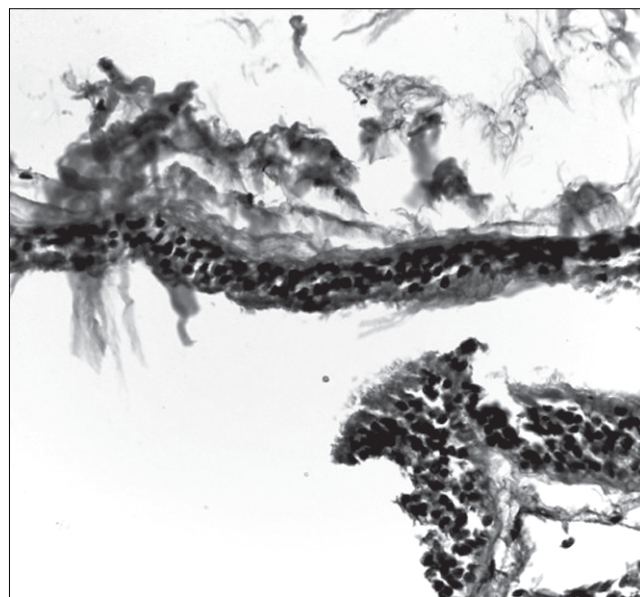
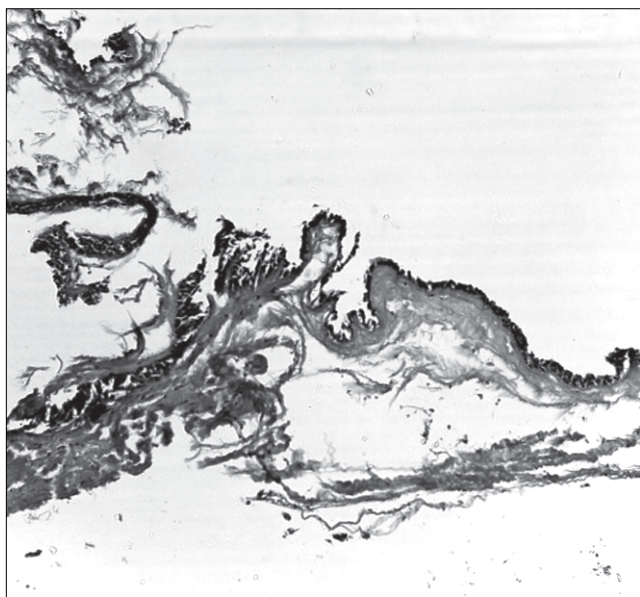


Figure III: Histopathological exam showed cyst wall lined by flattened layer of meningotheelial cells, compatible with arachnoid cyst

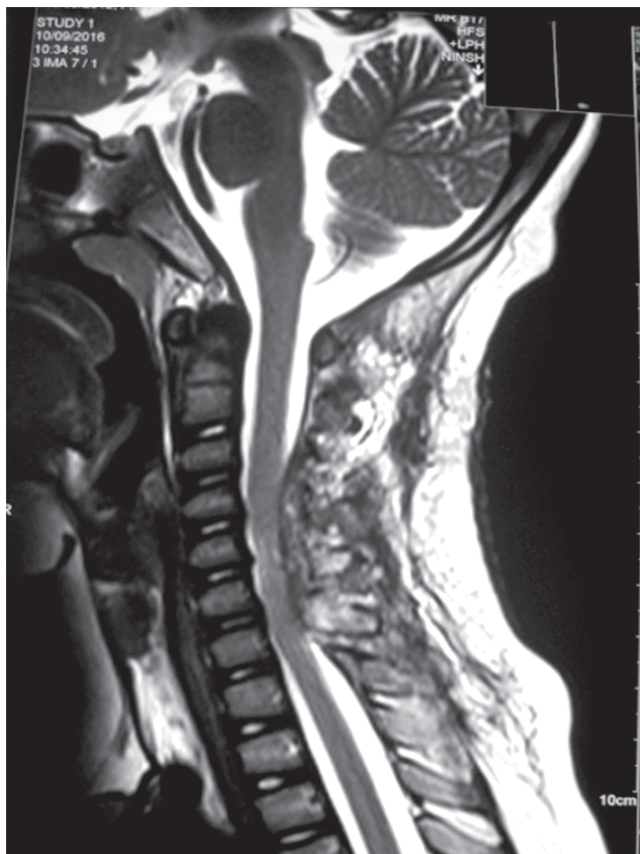
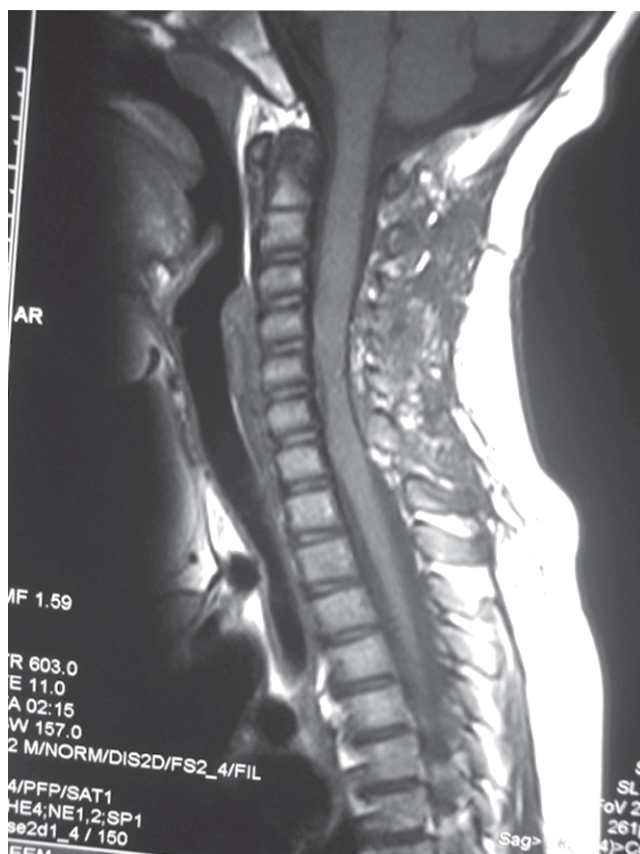
Figure IVa, b: Postoperative T1 and T2 weighted magnetic resonance sagittal images of the cervical spine showing near to complete resolution of the cyst

region⁵. A 4 year-old girl with an extradural spinal arachnoid cyst extending from the C4 to C7 situated anteriorly is reported here, pathogenesis, diagnosis and treatment modalities are discussed.

Case Presentation

This 4-year-old girl was admitted to our hospital with a 3 months history of neck pain and weakness of 4 limbs. She had no history of trauma or infection. Her

neurological exam showed muscle power in upper limbs 4/5 and in lower limbs 3/5, all reflexes were exaggerated and planter reflex was extensor bilaterally. Magnetic resonance imaging (MRI) revealed an extradural hypo-intense cystic lesion anterior to the cord in T1 and hyper-intense in T2 images resembling cerebrospinal fluid (CSF) intensity at C4-C7 level which was markedly compressing the cord (Figure I, II). A provisional diagnosis of extradural arachnoid cyst was made. With the patient in prone position laminotomy of C4 to C7 was done on 23.08.2016. The dentate ligaments at C5-C6 level were cut on the left side revealing a translucent cystic collection anterior to the cord. The cyst was aspirated revealing CSF. Following aspiration, the cyst shrunk and the dural pulsation appeared. With gentle retraction of the cord, the cyst's capsule was excised totally. Postoperative period was uneventful and the child showed motor recovery. MRI showed resolution of the arachnoid cyst (Figure 4). Histopathological examination revealed arachnoid cyst. After 1 year of follow-up the child was asymptomatic.

Discussion

Spinal arachnoid cysts are a relatively uncommon lesion that may be either intra- or extradural, and intradural spinal arachnoid cysts are even less common. These cysts are usually asymptomatic but may produce symptoms by compressing the spinal cord or nerve roots suddenly or progressively. We present three cases in the pediatric age group with spinal intradural arachnoid cysts without a preceding history of trauma. Three patients with symptomatic intradural arachnoid cysts were investigated with conventional T1- and T2-weighted magnetic resonance imaging (MRI). The MRI scans demonstrated the intradural arachnoid cysts with slightly lower CSF signal intensity on the gradient echo images and slightly higher signal intensity on T1-weighted images. The first cyst was located at the level T12-L1 and compressed the conus medullaris, with neurogenic bladder and cauda equina syndrome for 2 months. The second was located at the level C5-T1 ventrally, with spastic gait and neurogenic bladder for 4 years.

The other was located at T2-3 ventrally, with sudden onset of quadriplegia after jumping rope. The combined treatment of total resection and wide fenestration in our three patients produced an excellent return of neurologic function in each one, except for residual urinary disturbance in case 2. Intradural spinal arachnoid cysts appear to result from an alteration of

the arachnoid trabeculae; some such cysts are ascribed anecdotally to previous trauma or arachnoiditis, whereas the majority are idiopathic and congenital. The majority of intradural spinal arachnoid cysts occur in the thoracic region and most are dorsal to the neural elements. Only 10 cases have been reported in which the intradural arachnoid cysts were located anterior to the cervical spinal cord, of which 8 were in the pediatric age group, like our case 2. Myelography, post-contrast CT myelography and MRI have been demonstrated as useful for the diagnosis of intradural arachnoid cysts. MRI is the imaging modality of choice, and the extent, size and nature of the lesion in our cases were well demonstrated by MRI. Surgical treatment is necessary if progressive neurological dysfunction appears in the course of spinal cord compression. Complete surgical excision of the cysts is the best choice of treatment, and wide fenestration and shunting of the cyst to the peritoneum, pleural cavity or right atrium were the modalities of choice. MRI offers a noninvasive and effective means to make the diagnosis of arachnoid cysts easier. Intradural arachnoid cysts may cause progressive myelopathy; however, the postoperative prognosis is good if the operation is performed prior to neurologic deficits.

Spinal arachnoid cysts have been a rare cause of spinal cord or nerve root compression, especially in the pediatric age group². Most of these arachnoid cysts were considered congenital, however minor or major trauma was suspected to play a role in five instances⁵⁻⁹. Trauma might take part in the pathology and semiology of intradural arachnoid cysts in two ways either by producing a breach in the arachnoid membrane and subsequent development of a cyst or may trigger a silent preexisting arachnoid cyst into a symptomatic one.

The mechanism for the initial formation of an arachnoid cyst is likely multifactorial and is not completely understood. A few theories have been proposed. Elsberg et al⁹ reported 4 cases of arachnoid cysts in 1934 and proposed an origin from congenital diverticula or a congenital dural defect with herniation of the arachnoid. Support for the congenital theory is further strengthened by a few case reports of familial tendencies² and the frequency of association with neural tube defects². Other reports have hypothesized that congenital defects in the distribution of arachnoid trabeculations lead to misplaced cellular remnants resulting in an embryonic malformation, which may act as a nidus for cyst formation¹⁰.

The most common region for the development of

symptomatic SACs is the thoracic canal. In Bond et al² series, the distribution of SACs in pediatric patients was 1(3%) in the cervical region, 4(13%) thoraco-cervical, 11(36%) thoracic, 6(19%) thoracolumbar, 2(7%) lumbar, 4(13%) lumbosacral, and 3(10%) sacral. In previous reports, SACs were more commonly located extradurally than intradurally³⁻⁴. This relationship, however, was not observed in Bond et al² series. In that series eighteen (58%) patients had intradural cysts. Although arachnoid cysts are usually extramedullary, there have been a few reports of cases of intramedullary arachnoid cysts².

Majority of these cysts lie posteriorly on the spinal cord and are rarely located anteriorly. Review of the literature revealed that anteriorly located intradural arachnoid cyst are very rare in the cervical region. Symptoms of SACs likely develop as a result of pressure on the spinal cord or a spinal nerve root². Patients most commonly present with pain, followed by sensory changes (often presenting as gait instability), urinary dysfunction, and/or weakness². In pre MRI era, myelography and computed tomography (CT) myelography were used to diagnose these lesions². MRI is the modality of choice in diagnosis of the anterior cervical arachnoid cysts being demonstrated as a low signal round or oval lesions in T1 and hyperintense mass in T2 images compatible with CSF.

The treatment of choice for symptomatic SACs is excision or fenestration. The first step is laminectomy or laminoplasty, Nowadays en block laminoplasty is suggested to avoid postoperative kyphosis. For extradural cysts, excision of the cyst and closure of the cyst/dural communication is performed². Effort is made to remove as much of the cyst wall possible; however, recurrence has been reported after total cyst wall removal¹¹. For refractory cases, insertion of a cystoperitoneal shunt may be required¹²⁻¹⁴.

Conclusions

Symptomatic anterior cervical arachnoid cyst in pediatric patients is rare. Patients often present with pain followed by extremity weakness, gait instability and sphincter disturbances. Although spinal arachnoid cysts may be encountered at any spinal level, these are predominately found in the thoracic region.

Symptomatic cases, however, require surgical intervention. For long segment involvements, laminectomy or laminotomy is performed with subsequent cyst excision. Laminoplasty is strongly recommended in children in order to avoid post-laminectomy deformity. Neurological recovery depends on the size of the cyst, together with the degree and duration of the spinal cord compression. A long-standing spastic myelopathy is unlikely to have significant improvement. Overall outcomes following surgical management are excellent, especially if the arachnoid cysts are diagnosed early.

References

1. Mehta S, Dharmarajan S, Brzozowski M, Trojanowski T. Spinal arachnoid cysts—a report of two cases and a review of the literature. *Journal of Pre-Clinical and Clinical Research*. 2010;4(1):77-78
2. Bond AE, Zada G, Bowen I, McComb JG, Krieger MD. Spinal arachnoid cysts in the pediatric population: report of 31 cases and a review of the literature. *Journal of Neurosurgery: Pediatrics*. 2012;9(4):432-41
3. Goyal A, Singh AK, Singh D, Gupta V, Tatke M, Sinha S, Kumar S. Intramedullary arachnoid cyst: Case report. *Journal of Neurosurgery: Spine*. 2002;96(1):104-6
4. Lee HJ, Cho DY. Symptomatic spinal intradural arachnoid cysts in the pediatric age group: description of three new cases and review of the literature. *Pediatric neurosurgery*. 2001;35(4):181-7
5. Rahimizadeh A, Sharifi G. Anterior cervical arachnoid cyst. *Asian spine journal*. 2013;7(2):119-25
6. Kazan S, Ozdemir O, Akyuz M, Tuncer R. Spinal intradural arachnoid cysts located anterior to the cervical spinal cord: report of two cases and review of the literature. *J Neurosurg* 1999;91:211-5
7. Hoffman EP, Garner JT, Johnson D, Sheldon CH. Traumatic arachnoidal diverticulum associated with paraplegia: case report. *J Neurosurg* 1973;38:81-5
8. Muthukumar N. Anterior cervical arachnoid cyst presenting with traumatic quadriplegia. *Childs Nerv Syst* 2004;20:757-60
9. Chen HJ, Chen L. Traumatic interdural arachnoid cyst in the upper cervical spine. Case report. *J Neurosurg* 1996;85:351-3
10. Hyndman OR, Gerber WF. Spinal extradural cysts, congenital and acquired; report of cases. *J Neurosurg*. 1946; 3:474-486
11. Neo M, Koyama T, Sakamoto T, Fujibayashi S, Nakamura T. Detection of a dural defect by cinematic magnetic resonance imaging and its selective closure as a treatment for a spinal extradural arachnoid cyst. *Spine* 2004;29:E426- E430
12. Carrillo R. Lumbar cerebrospinal fluid drainage for symptomatic sacral nerve root cysts: an adjuvant diagnostic procedure and/or alternative treatment? Technical case report. *Neurosurgery* 1998; 42:952-953
13. James HE, Postlethwait R. Spinal peritoneal shunts for conditions other than hydrocephalus and pseudotumor cerebri: a clinical report. *Pediatr Neurosurg* 2007; 43:456-460
14. James HE, Tibbs PA. Diverse clinical applications of percutaneous lumboperitoneal shunts. *Neurosurgery* 1981; 8:39