

## Patent Foramen Ovale Device Closure in Cryptogenic Ischaemic Stroke: A Two Case Reports with Literature Review

AQM Reza<sup>1</sup>, Aparajita Karim<sup>2</sup>, Mahmood Hasan Khan<sup>3</sup>, Kazi Atiqur Rahman<sup>4</sup>, Md. Aliuzzaman Joarder<sup>5</sup>,  
Khondoker Mahbubur Rahman<sup>6</sup>, Shahab Uddin Talukder<sup>7</sup>, Shams Munwar<sup>8</sup>, M Atahar Ali<sup>9</sup>,  
Tamzeed Ahmed<sup>10</sup>, HM Waliul Islam<sup>11</sup>, Poppy Bala<sup>12</sup>, Nighat Islam<sup>13</sup>, Azfar Hossain Bhuiyan<sup>14</sup>

<sup>1</sup>Senior Consultant & Co-ordinator, Department of Clinical & Interventional Cardiology, Evercare Hospital, Dhaka, Bangladesh; <sup>2</sup>Associate Consultant, Department of Clinical & Interventional Cardiology, Evercare Hospital, Dhaka, Bangladesh; <sup>3</sup>Associate Consultant, Department of Clinical & Interventional Cardiology, Evercare Hospital, Dhaka, Bangladesh; <sup>4</sup>Senior Consultant, Department of Clinical & Interventional Cardiology, Evercare Hospital, Dhaka, Bangladesh; <sup>5</sup>Senior Consultant, Department of Neuro-surgery, Evercare Hospital, Dhaka, Bangladesh; <sup>6</sup>Senior Consultant, Department of Neuro-medicine, Evercare Hospital, Dhaka, Bangladesh; <sup>7</sup>Senior Consultant, Department of Clinical & Interventional Cardiology, Evercare Hospital, Dhaka, Bangladesh; <sup>8</sup>Senior Consultant, Department of Clinical & Interventional Cardiology, Evercare Hospital, Dhaka, Bangladesh; <sup>9</sup>Senior Consultant, Department of Clinical & Interventional Cardiology, Evercare Hospital, Dhaka, Bangladesh; <sup>10</sup>Senior Consultant, Department of Clinical & Interventional Cardiology, Evercare Hospital, Dhaka, Bangladesh; <sup>11</sup>Associate Consultant, Department of Clinical & Interventional Cardiology, Evercare Hospital, Dhaka, Bangladesh; <sup>12</sup>Senior Specialist, Department of Clinical & Interventional Cardiology, Evercare Hospital, Dhaka, Bangladesh; <sup>13</sup>Associate Consultant, Department of Clinical & Interventional Cardiology, Evercare Hospital, Dhaka, Bangladesh; <sup>14</sup>Associate Consultant, Department of Clinical & Interventional Cardiology, Evercare Hospital, Dhaka, Bangladesh

[Received: 22 October 2021; Accepted: 12 December 2021; Published: 1 January 2022]

### Abstract

A patent foramen ovale (PFO) is highly prevalent in patients with strokes of unknown cause or cryptogenic strokes (CSs). It has been remain an unsolved question as to whether a PFO should be closed or not to prevent recurrent strokes in patients diagnosed with CS. A paradoxical embolism through a PFO is pointed as a leading cause of CS, especially in younger patients with low risk factors for stroke. It also remains an unsolved matter on type of anti-coagulation therapy, which would be better for patients with CS and a PFO. In addition, surgical and trans-cutaneous closure of a PFO has been proposed for the secondary prevention of stroke in patients with CS with PFO. Several randomized controlled trials have been conducted in recent years to test whether a PFO closure gives a significant benefit in the management of CS. Many investigators believed that a PFO was an incidental finding in patients with CS. However, meta-analyses and more recent specific trials have eliminated several confounding factors and possible biases and have also emphasized the use of a shunt closure over medical therapy in patients with CS. Therefore, these latest studies can possibly change the treatment paradigm in the near future. [*Journal of National Institute of Neurosciences Bangladesh, January 2022;8(1): 90-99*]

**Keywords:** Cryptogenic stroke; paradoxical embolism; patent foramen ovale; trans-catheter closure

**Correspondence:** Prof. AQM Reza, Professor, Department of Clinical & Interventional Cardiology, Evercare Hospital Limited, Bashundhara R/A, Dhaka, Bangladesh; Email: [aqm.reza@evercarebd.com](mailto:aqm.reza@evercarebd.com); Cell no.: +8801711533907

**Conflict of interest:** There is no conflict of interest relevant to this paper to disclose.

**Funding agency:** This research project was not funded by any group or any institution.

**Contribution to authors:** Reza AQM, Karim A, Khan MH were involved in protocol preparation, data collection up to report writing. Rest are involved in designing, overall supervision and manuscript writing.

**How to cite this article:** Reza AQM, Karim A, Khan MH, Rahman KA, Joarder MA, Rahman KM, Talukder SU, Munwar S, Ali MA, Ahmed T, Islam HMW, Bala P, Islam N, Bhuiyan AH. Patent Foramen Ovale Device Closure in Cryptogenic Ischaemic Stroke: A Two Case Reports with Literature Review. *J Natl Inst Neurosci Bangladesh*, 2022;8(1): 90-99

**Copyright:** ©2022. Reza et al. Published by Journal of National Institute of Neurosciences Bangladesh. This article is published under the Creative Commons CC BY-NC License (<https://creativecommons.org/licenses/by-nc/4.0/>). This license permits use, distribution and reproduction in any medium, provided the original work is properly cited, and is not used for commercial purposes.

### Introduction

Stroke stands in the fifth position for causing death and in the top for causing preventable adult disability in the United States<sup>1</sup>. In 2013, stroke-related deaths worldwide touched the figure of 6.5 million accounting for 11.8% of

total deaths<sup>2</sup>. Strokes also cost USD 34 billion each year in the United States<sup>1</sup>. This includes the cost of healthcare, medications, and missed workdays.

Cryptogenic stroke is defined as brain infarction that is not attributed to definite large-vessel atherosclerosis,

small-artery disease, or embolism despite extensive vascular, serological, and cardiac evaluation<sup>3</sup>. Approximately one-third of all ischemic strokes are considered cryptogenic<sup>4</sup>. The causal relationship between patent foramen ovale (PFO) and cryptogenic stroke has historically been controversial. Approximately 25% of the adult population has a PFO, and the condition by itself has not been shown to increase the risk of ischemic stroke<sup>5-6</sup>. Yet, the prevalence of PFO is significantly higher in patients with cryptogenic stroke; up to 40% of ischemic strokes without an identifiable cause have a PFO<sup>7</sup>. This suggests that paradoxical embolism through a PFO may be implicated in a proportion of cryptogenic strokes.

The association of PFO with stroke was first described by Julius Friedrich Cohnheim, a German pathologist<sup>8</sup>. About 25.0% prevalence in the general population PFO, the risk of stroke appears to be higher when the PFO is associated with an atrial septal aneurysm, a Eustachian valve, or a large shunt. Although percutaneous ASD closure has been practiced since the mid-1970s. In Bangladesh, there was lack of documentation about this association of PFO with cryptogenic stroke. The first ever PFO device closure in a cryptogenic stroke patient of Bangladesh was first reported by Reza et al<sup>9</sup>. Consequently, we were able to successfully close another case and reporting this case series.

**Case Presentation**

**Case Report 1:** A 27 years old hypertensive & diabetic pleasant lady got herself admitted to Evercare Hospital Dhaka on September 2020 under Department of Neurosurgery with the complaints of headache followed by left sided weakness for 7 days. After admission,

proper evaluation and all necessary investigations including Covid19 RT-PCR which was found negative were done. On admission, her pulse 46 beats/ min & regular, blood pressure in 130/80 mm of Hg, Temperature in 98.40 F, respiratory rate in 20 breaths/min, SPO2: 98.0% in room air, GCS was 15 (E4V5M6), pupil was 2 mm PERL & physical examination revealed left sided hemiplegia. Initially the patient was on conservative treatment. Her initial imaging had revealed by CT-scan of brain (Figure I) with sub-acute right middle cerebral artery territory infarct involving right frontal lobe, insular region and lentiform nucleus. There was also cortical hyper-density suggesting mild petechial haemorrhage. Peri-lesional edema was noted causing regional mass effect and 0.4 cm midline shift to the left side. No hydrocephalus was noted.

**Carotid Artery Duplex Study:** No evidence of haemodynamically significant stenosis with bilateral patent vertebral arteries. Her blood results showed dyslipidaemia (TLC: 234 mg/dL, LDL-C: 164 mg/dl, HDL-C: 42 mg/dL, triglyceride: 141 mg/dL), raised ESR (60 mm in 1st hour) and CRP (18.5 mg/dL). All other routine blood tests including coagulation profile were within normal limit (Table 1).

Table 1: Coagulation Profiles of Patients

Coagulation Profiles	Results
ANA	Negative
Anti dsDNA Antibodies	Negative
Direct Coomb's Test	Negative
Anti-Cardiolipin Antibodies	Negative
Anti-Phospholipid Antibodies	Negative

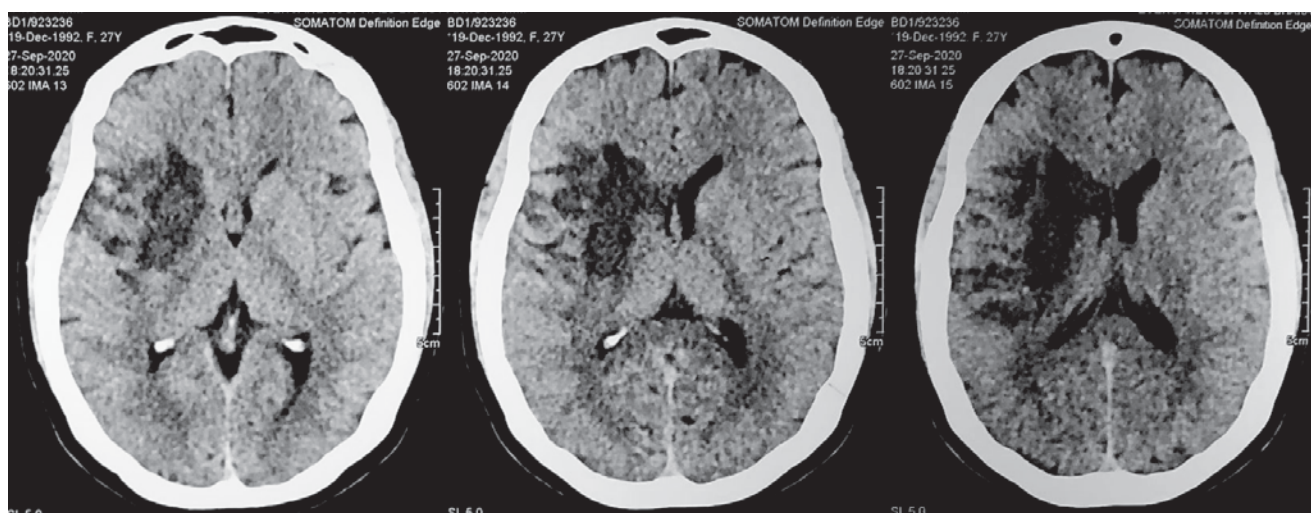


Figure I: CT-Scan of Brain Showing Large Acute Cerebral Infarct in Right MCA Territory

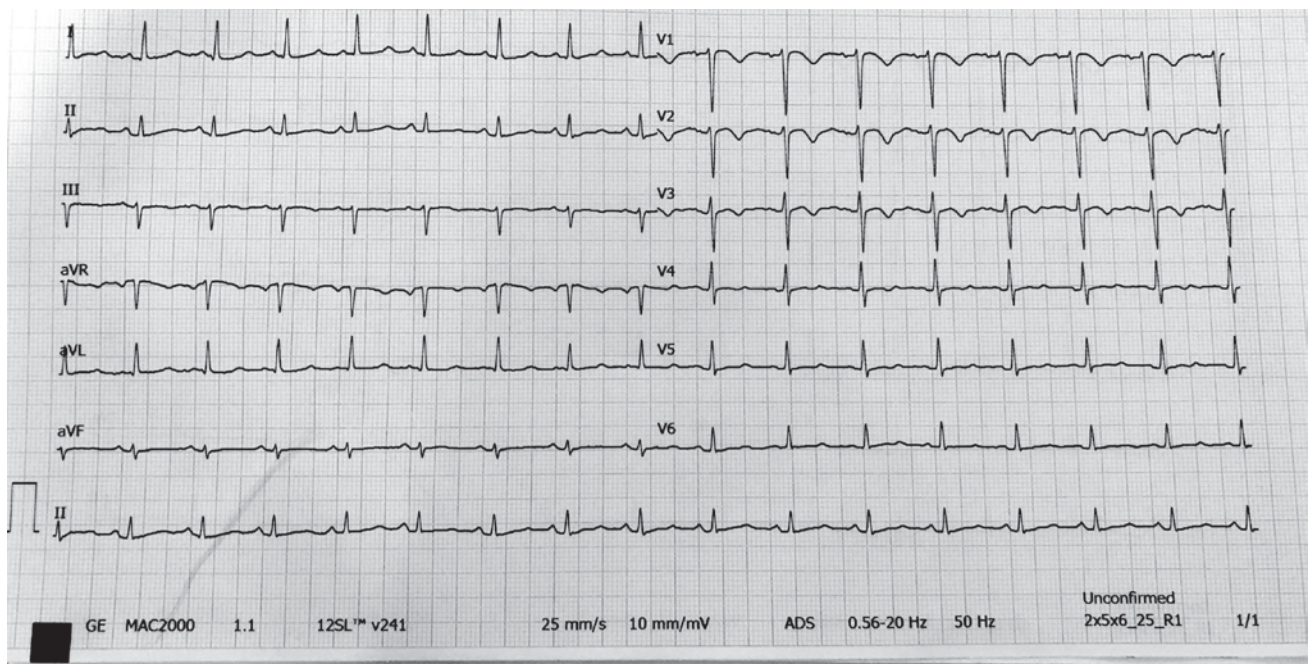


Figure II: ECG showing T inversion from V<sub>1</sub> to V<sub>4</sub>

As the patient was admitted under Department of Neurosurgery, cardiology consultation was made for cardiac evaluation for her large cerebral infarction. Cardiology evaluated the patient & advised to perform ECG, Chest X-ray and Echo 2D & M-mode. Her ECG showed normal sinus rhythm with T inversion in V<sub>1</sub> to V<sub>4</sub> (Figure II).

The chest X-ray of the patient had showed mild cardiomegaly with no other abnormality. The 2D & M-mode echocardiography revealed suspected PFO, dilated RA & RV, Paradoxical IVS (otherwise normal), Good LV systolic function with LVEF (60.0%), Mild TR with mild pulmonary hypertension. Revealing a suspected PFO, Cardiology advised for a

trans-oesophageal echocardiography. Trans-oesophageal echocardiography confirmed the presence of a long tunneled (3-4 mm) PFO without any shunt & recommended for a closure of the PFO with a device. The presence of the PFO was further confirmed with a contrast echocardiography (Figure III) which showed contrast passed from right atrium (RA) to left atrium (LA) through PFO & confirmed R-L shunt through PFO with more than 10 bubbles in LA.

Considering all the investigation reports this PFO was identified as the culprit for causing the large cerebral infarction and a decision to close the PFO with a device was made. Patient's condition, treatment plan, prognosis with cost all were explained in details. They

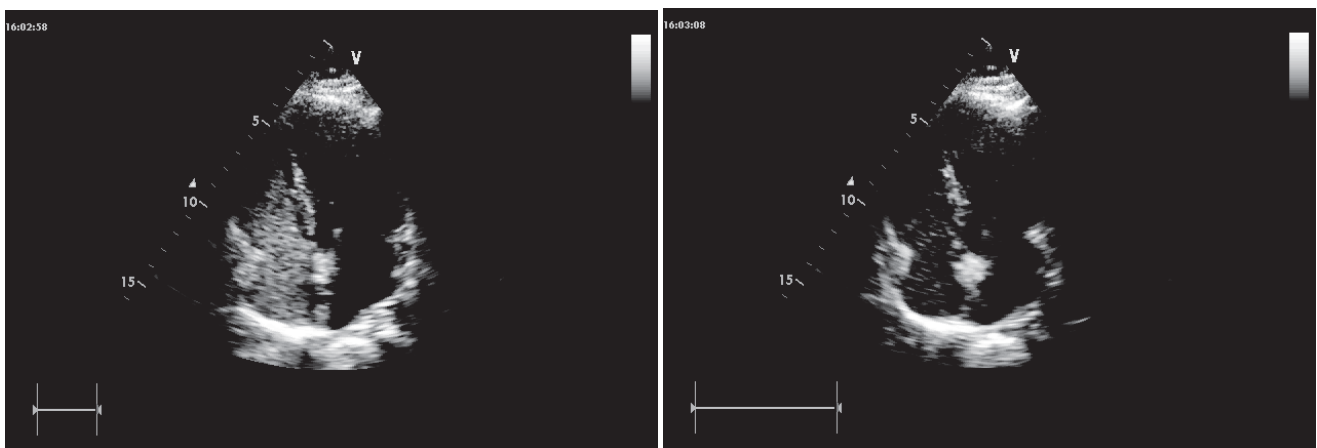


Figure III: Contrast Echocardiography Showing Presence of PFO



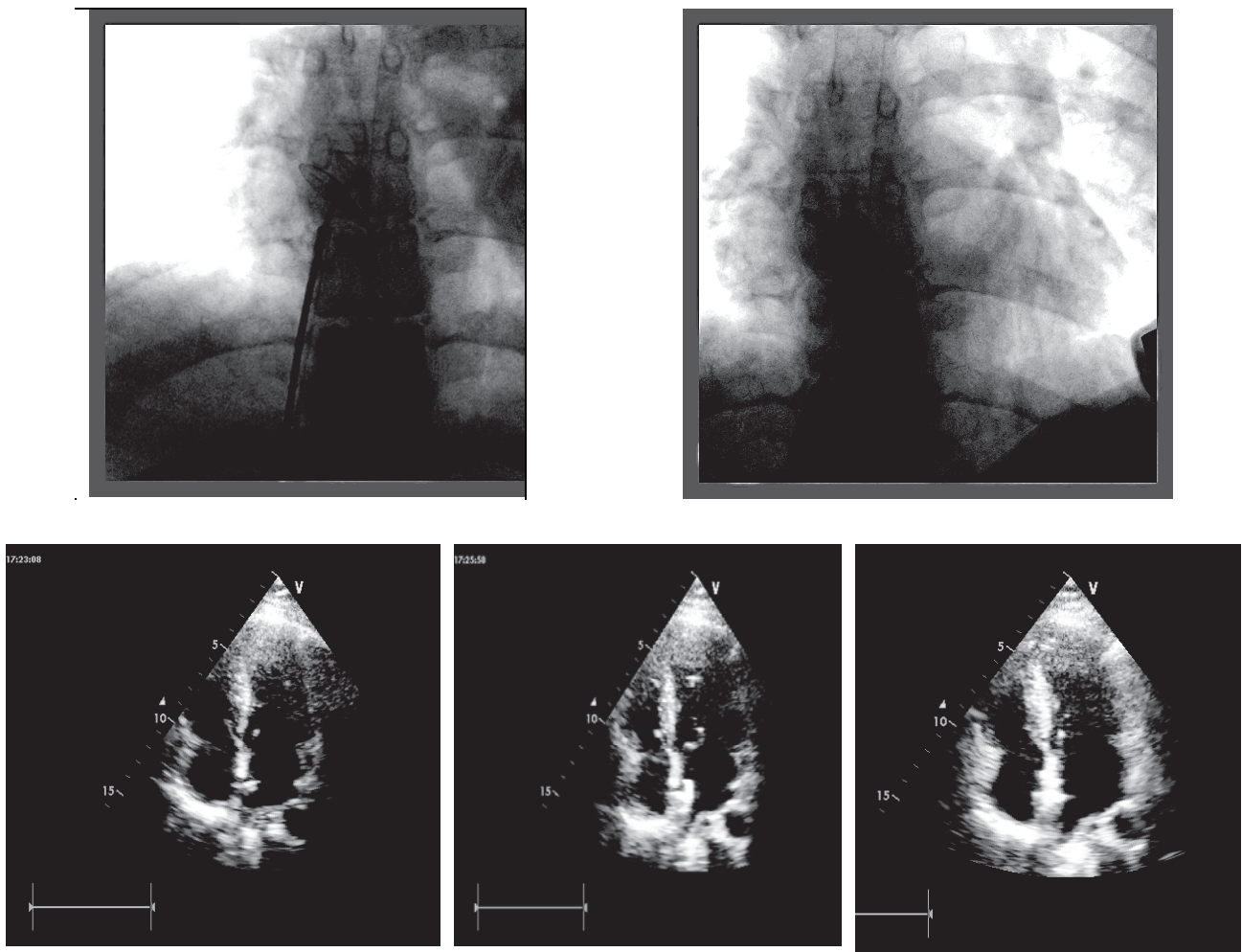


Figure IV: Fluoroscopic & Echocardiographic Schema Depicting PFO Device Closure

agreed to undergo for a device closure of the PFO. Then on 18<sup>th</sup> October 2020 a successful PFO device closure was done. The procedure was done without puncturing the inter-atrial septum which was the main challenge. We successfully negotiated the guide wire through the long tunneled PFO to LA. Then the delivery sheath was negotiated over the wire into the LA. The PFO closure device (Lifetech Patent Foramen Ovale Occluder 25 mm-18 mm) was then advanced through the delivery sheath to LA. The device position was ascertained under echocardiography guidance (Figure IV). But the total procedure was not as smooth as silk. After confirming the correct device position when we tried to unscrew the device we failed to do so. We tried for several times but were not successful. Then the whole assembly was taken out of the body, reassembled and reintroduced. Again the device positioned in the site under echocardiography guidance & deployed. This time we successfully unscrew the device. The position of the device then ascertained with different

fluoroscopic views. Then we declared to create the history as this was the first ever PFO device closure solely performed by a Bangladeshi interventional Cardiologist & his team in Evercare Hospital Dhaka. The patient is doing fine in her first follow-up after PFO device closure after 01 month.

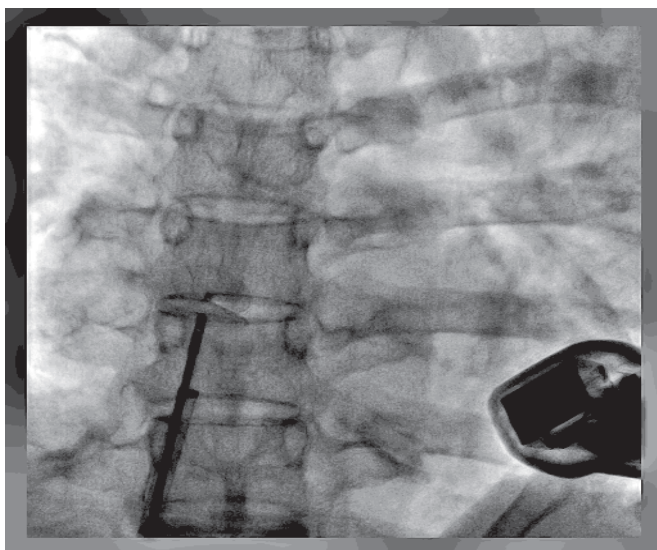
**Case Report 2:** A 37 years old normotensive & non-diabetic pleasant lady got herself admitted to Evercare Hospital Dhaka on 28<sup>th</sup> October 2020 for elective closure of a PFO. She had H/O acute cerebral infarction with left sided hemiparesis with meningo-encephalitis 02 weeks prior to admission. Then she was diagnosed to have a patent foramen ovale (PFO) and was advised to perform a device closure. At that time, the patient could not do the closure due to financial constraint. After 2 weeks she got herself admitted for the procedure. After admission, proper evaluation and all necessary investigations including Covid19 RT-PCR (which was found negative) were done. On admission, her Pulse: 80 beats/ min & regular, BP: 120/80 mm of Hg,

Temperature was in 98.3°F, respiratory rate was in 18 breaths/min, SPO2: 99% in room air, GCS: 15 (E4V5M6) & physical examination revealed left sided hemiparesis. Her initial imaging revealed by CT-scan of brain with acute right middle cerebral artery territory multiple infarcts involving right frontal lobe (Figure V). Peri-lesional edema was noted causing regional mass effect and 0.6 cm midline shift to the left side. No hydrocephalus was noted.

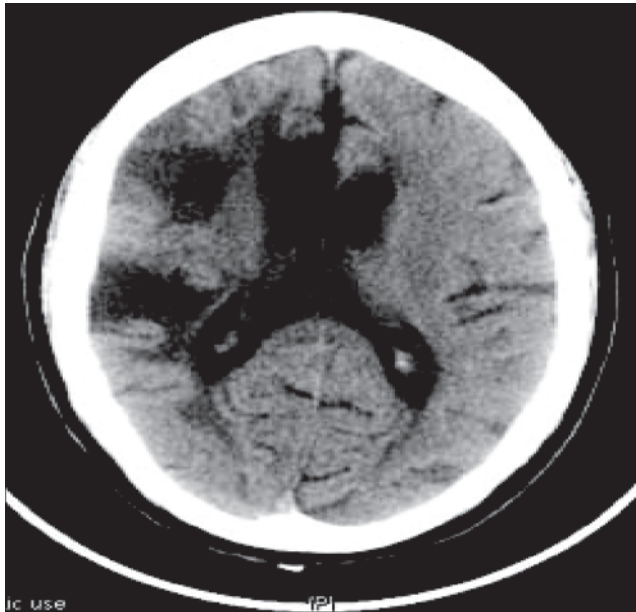

Figure V: CT-Scan of Brain Showing Multiple Acute Cerebral Infarct in right MCA territory

**Carotid Artery Duplex Study:** No evidence of haemodynamically significant stenosis with bilateral



patent vertebral arteries. Her routine blood tests including coagulation profile were within normal limit (Table 2).

Table 2: Coagulation Profiles of 2<sup>nd</sup> Patient

Coagulation Profiles	Results
ANA	Negative
Anti dsDNA Antibodies	Negative
Direct Coomb’s Test	Negative
Anti- Cardiolipin Antibodies	Negative
Anti- Phospholipid Antibodies	Negative

Her ECG (Figure VI) was within normal limit.

Her Chest X-ray showed normal chest skiagram. Her 2D & M-mode echocardiography revealed suspected PFO, No RWMA, Good LV and RV systolic function with LVEF 58%. Suspecting a PFO we advised her for a trans-oesophageal echocardiography. Trans-oesophageal echocardiography confirmed the presence of a short tunneled PFO with left to right shunt and recommended for a closure of the PFO with a device.

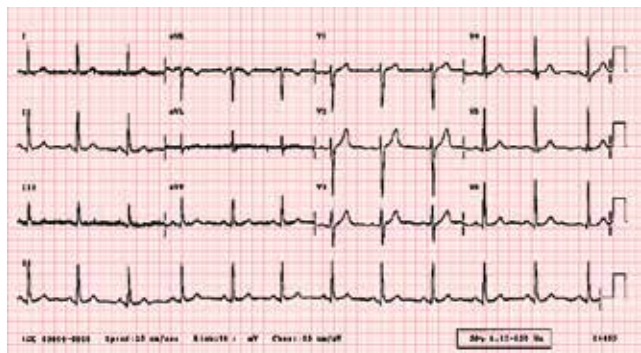
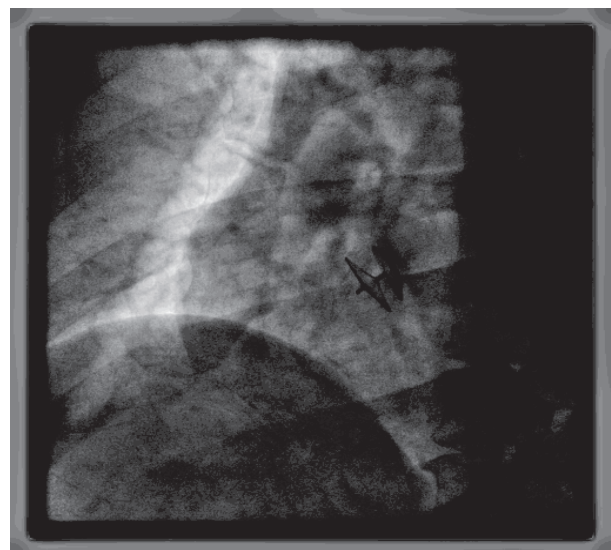


Figure VI: Within normal limit ECG



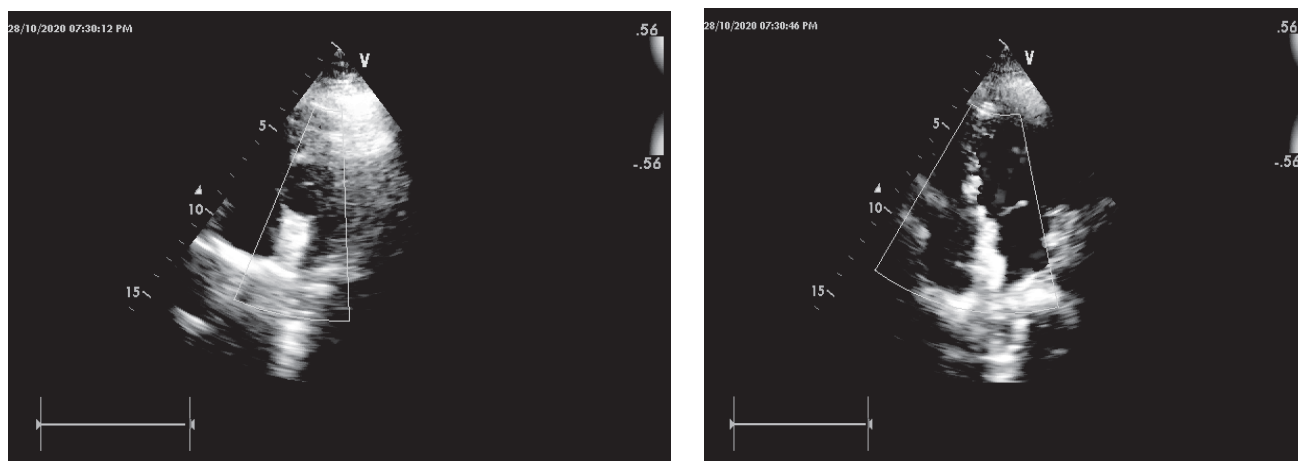


Figure VII: Fluoroscopic & Echocardiographic schema depicting PFO device closure.

identified as the culprit for causing the large multiple cerebral infarction and a decision to close the PFO with a device was made. Patient's condition, treatment plan, prognosis with cost all were explained in details. They agreed to undergo for a device closure of the PFO. Then on 28<sup>th</sup> October 2020 a successful PFO device closure was done. We successfully negotiated the guide wire through the short tunneled & small PFO quickly to LA. Then the delivery sheath was negotiated over the wire into the LA. The PFO closure device (Occlutech Patent Foramen Ovale Occluder 18 mm-16 mm) was then advanced through the delivery sheath to LA. The device position was ascertained under echocardiography guidance (Figure VII). After successful device closure of the PFO the patient was discharged on 30<sup>th</sup> October 2020. The patient is doing fine in her first follow-up after PFO device closure after 01 month. She can walk independently without any further neurological deficit.

### Discussion

Strokes account for approximately 1 of every 20 deaths in the United States. They are the fifth leading cause of death and a major cause of disability in adults. Every 40 seconds, someone in the United States has a stroke, and among those individuals, almost 87.0% of strokes are ischemic. On average, every 4 minutes, someone dies of a stroke<sup>1</sup>. Despite recent advances in diagnosis and treatment, approximately one-fifth of stroke survivors require institutional care 3 months after the index event, and 15.0% to 30.0% of these survivors are permanently disabled<sup>10</sup>. With approximately 795000 stroke events occurring each year, approximately 185000 are recurrent attacks. The highest number of recurrent attacks recorded at 4 years after the index event, accounted for almost 18.4% compared with only 1.8% in the first year, as evidenced in a cohort of 10 399 patients who were

discharged with a stroke in the state of South Carolina in 2002. Despite the use of antithrombotic agents, children who have experienced an arterial ischemic stroke remain at a high risk for recurrent events<sup>1</sup>.

There are numerous causes of ischemic stroke. Most of these causes can be categorized into 3 groups: atherosclerotic, cardio-embolic, and lacunar (a small vessel occlusion). Approximately, 25.0% to 39.0% of ischemic strokes do not have an identifiable cause and are termed as a stroke of unknown cause or a cryptogenic stroke (CS)<sup>11</sup>. The most commonly used classification for strokes is the TOAST (trial of ORG 10172 in acute stroke treatment) classification, and it defines a CS as a brain infarction that is not attributable to definite cardio-embolism, large artery atherosclerosis, or small artery disease, despite extensive vascular, cardiac, and serologic evaluations. However, it is obvious that no human disease is without a cause; hence, stroke classification depends on how extensive and rapid the diagnostic workup is performed<sup>12</sup>. A CS is more common in younger patients (less than 55 years of age), and the frequently considered causes are a cardiac embolism, followed by vasculopathy and coagulopathy. One of the most frequent causes of cardiac embolism in CS is a paradoxical embolus, which might originate from a venous source, such as a deep venous thrombosis (DVT), through an unidentified patent foramen ovale (PFO), either with or without an atrial septal aneurysm (ASA).

A PFO has been shown to be more prevalent in patients with a CS than in the general population<sup>13</sup>. However, the condition by itself has not been shown to increase the risk of an ischemic stroke. The true prevalence of a paradoxical embolus remains unknown because of the difficulty in the diagnosis of this phenomenon<sup>15</sup>. It has been a topic of debate as to whether the prevalence of a



PFO, or any other such shunt in patients with CS, represents a cause-effect relationship. Numerous studies have displayed a strong relationship between shunts and development of a CS. Some studies suggest that a PFO could be the major contributor of strokes in younger patients and those with a lower degree of atherosclerotic risk factors<sup>16</sup>. There is strong evidence that documents a physiological gradient that results in an increased risk of a paradoxical embolism, which is related to both the shunt size and the presence of an additional ASA<sup>17</sup>. Therefore, the issue of whether or not to close a PFO in patients with a CS is of great interest in both the neurology and cardiology communities.

To evaluate the effects of a PFO closure, several newer percutaneous device techniques were introduced. The Amplatzer PFO Occluder was approved by the Food and Drug Administration (FDA) on October 28, 2016. This device is indicated for the percutaneous trans-catheter closure of a PFO, to reduce the risk of a recurrent stroke in patients who have been determined by a neurologist and a cardiologist as having a CS via a paradoxical embolus. In the past 5 years, several trials have been conducted, to evaluate the benefit of a PFO closure<sup>18</sup>. Through the analysis of the results of these studies, we can gain a better understanding of this cause-effect relationship.

A paradoxical embolism refers to the mechanism in which an embolus, originating from the venous system, traverses to the systemic circulation via an intra-cardiac or pulmonary shunt. An intra-cardiac embolus via a PFO is hypothesized to be one of the possible mechanisms that lead to a CS. A PFO is a remnant of the fetal circulation and is by far the most common intra-cardiac shunt. During an autopsy, it has been identified in almost 27.0% of patients with normal hearts. It is formed by the left-sided inter-atrial septum primum and the right-sided inter-atrial septum secundum. The prevalence of a PFO appears to decrease with increasing age, with an incidence of 34.0% during the first 3 decades and an incidence of 25.0% in the third to seventh decades<sup>10,15</sup>. Under normal physiologic conditions, the mean left atrial pressure exceeds the right atrial pressure creating a pressure gradient that facilitates passive closure of the PFO. However, a transient increase in the right atrial pressure can occur during Valsalva maneuver, such as coughing, sneezing, squatting, defecation, or micturition, resulting in a right to left shunt and passage of particulate matter like thrombi into the systemic circulation. It was demonstrated in the SPARC study<sup>19</sup> that the prevalence of right-to-left shunting increases from 14.0% to 23.0% with the performance of these

maneuvers, whereas a permanent increase in the right cardiac pressure can occur in pathologic conditions, such as a pulmonary embolism or an increase in pulmonary artery pressure. These can result in a paradoxical embolus in the systemic circulation, which can then cause end organ damage, such as a stroke, transient ischemic attack (TIA), or peripheral thrombo-embolism. The estimated risk of a paradoxical embolism in patients with an acute pulmonary embolism is approximately 60.0% cases<sup>20</sup>. The important factors that determine the significance of a PFO are its size and the degree of a right-to-left shunt. Those patients with a PFO size of more than 4 mm are at a greater risk of a paradoxical embolism. It has also been noted that, in patients with CS, the PFOs are larger, have long tunnels, and are frequently associated with an ASA.

It is extremely difficult to establish the presence of a venous thrombus and/or a thrombus in transit through the PFO in most of the cases. Therefore, without a visualization of an entrapped thrombus in the defect, it can only be assumed that the cause could be a paradoxical embolus. In addition, clots that are less than 2 mm in size are beyond the resolution of the transesophageal echocardiography (TEE) transducers, and there is a higher chance of not detecting them. Thus, efforts to establish a cause-effect relationship between a PFO and a paradoxical embolism would be confounded by these multiple factors<sup>21</sup>. To overcome these drawbacks and to identify whether the PFO was related to a stroke or an incidental event, an index scoring system was proposed in the Risk of Paradoxical Embolism (RoPE) study<sup>22</sup>. The RoPE score was developed in patients of all ages, and it ranges from 0 to 10. A higher score indicates a greater probability that the stroke is secondary to a PFO. The score is higher for younger patients, with a score of up to 5 points for those patients who are less than 30 years old and a score of 1 point each for the absence of hypertension, diabetes, smoking, a history of a stroke or a TIA, and the presence of a cortical infarct on imaging<sup>23-24</sup>. This scoring system can guide clinicians and researchers in avoiding patients with incidental PFOs who are to be enrolled in clinical trials while also testing for the effectiveness of PFO closures on a CS.

Furthermore, it can be used for selecting appropriate candidates for a closure to prevent a CS. The preferred imaging modality used for the diagnosis of PFO is the TEE. Transesophageal echocardiography is considered superior to trans-thoracic echocardiography to better describe the morphologic characteristics of the lesion and can aid in better diagnosis. The presence of bubbles

within the left atrium may suggest a PFO or an intrapulmonary shunt. The appearance should occur within several cardiac beats. To assess the degree of right to left shunt across the PFO, agitated saline contrast is used. While asking the patient to perform the Valsalva maneuver, the saline contrast medium is injected into the peripheral vein and visualization of the atrial septum is performed at a 90° angle to a more vertical plane. To standardize and quantify the PFO, the number of contrast bubbles appearing in the left atrium is measured.

In the French PFO-ASA study, appearance of 3 contrast bubbles was considered positive for the presence of a PFO. If 3 to 9 bubbles appeared, the shunt was considered small and moderate if 10 to 30 bubbles present. The defect is considered large only if more than 30 bubbles were observed left atrium<sup>16</sup>. But according to the PFO in CS study (PICSS), a PFO was considered to be present if at least 1 or more contrast bubbles were noted in the left atrium. The defect was considered large if more than 10 bubbles were seen. Using this protocol, a PFO was identified by TEE in 33.8% of all patients enrolled in the PICSS with an age range of 30 to 85 years. Among them, around 39.2% were patients with CS with PFO and 29.9% of patients had a known cause of stroke ( $P < 0.02$ )<sup>10,25</sup>.

A similar cutoff point was also used for all the latest studies conducted for the evaluation of the effectiveness of PFO closure. When 30 micro-bubbles were needed in the CLOSE trial to render them as large defects, REDUCE trial divided it into 3 categories and those with more than 25 micro-bubbles were considered large and those with 6 to 25 bubbles observed in the left atrium were considered moderate. On the contrary, in the Randomized Evaluation of Recurrent Stroke Comparing PFO Closure to Established Current Standard of Care Treatment (RESPECT) trial, the shunt size of PFOs was graded on a standard scale, considering the presence of 10 to 20 micro-bubbles as grade 2 and the ones with more than 30 micro-bubbles to be defined as grade 3.

Anti-platelet therapy, along with a stroke risk factor modification, remains the mainstay of treatment in most patients who are diagnosed with a CS, with or without evidence of a PFO. Even though there is a growing interest in the use of anticoagulation therapies, there are insufficient data to establish whether oral anticoagulation (OAC) is equivalent to, or superior to, aspirin as a secondary prevention of a CS. In most cases, current practices are individualized according to patient risk factors and physician preferences. However, the

identification of atrial fibrillation (AF) in patients with CS makes OAC the preferred therapy over anti-platelet therapy<sup>10,25</sup>.

The major study to correlate the efficacy of anticoagulation therapy with anti-platelet therapy in patients with CS was derived from post hoc analyses of the Warfarin-Aspirin Recurrent Stroke Study (WARSS) trial<sup>18</sup> which included 2206 patients with stroke who were evaluated over a period of 24 months for recurrent stroke or death, while receiving either aspirin or warfarin. Even when the primary analysis of WARSS did not show any significant benefit of warfarin over aspirin in the secondary prevention of non-cardio embolic strokes, the use of warfarin was shown to be associated with one-third fewer recurrent strokes than the use of aspirin in patients with CS, compared with the use of aspirin with an embolic cause of stroke. However, the association did not reach a statistical significance<sup>26-28</sup>. The PICSS was performed in collaboration with the WARSS, to evaluate the efficacy of an antithrombotic therapy in a PFO-induced CS<sup>23</sup>. A total of 630 patients with stroke were randomly assigned to either warfarin or aspirin and evaluated for the presence of a PFO using TEE. Overall, 203 patients were found to have a PFO, which accounted for 33.8% of the population. However, no significant difference in the time to reach the primary end point was detected in those with or without a PFO. It should be noted that the primary end points included several subtypes of strokes, and among them, the lacunar infarcts accounted for approximately 244 (38.7%) of cases. It was shown in the PICSS that a larger PFO was associated with a CS. However, the rates of recurrence of a stroke or TIA in patients with or without a PFO were shown to be similar to medical therapies with either aspirin or warfarin. In the study, it was concluded that the presence or absence of a PFO does not affect outcomes over a period of 2 years regarding medical therapy. Therefore, it was necessary to identify the best treatment modality for preventing recurrent strokes in patients with a PFO. Aside from the traditional medical therapies with anti-platelet therapy and an OAC, a surgical closure and a percutaneous device closure attracted interest. Due to the risk of undergoing a major surgery for an uncertain cause, a percutaneous PFO closure gained in popularity<sup>26-29</sup>.

A percutaneous PFO closure is a catheter-based technique that uses atrial septal occlusion devices. It was initially recommended for the prevention of recurrent strokes in 1992. The safety and viability of these devices have been assessed in several studies<sup>30-33</sup>. These devices have also been safely used in the closure of ASDs in



several patients. The device-related complications that might occur are classified as major vascular complications and major adverse device events. The major vascular complications that could be associated with the closure devices include the following: a hematoma at the access site that is more than 5 cm, false aneurysm, an arterio-venous fistula, retroperitoneal bleed, peripheral ischemia/nerve injury, procedure-related transfusion, or a need for a vascular surgical repair. However, none of these complications were significant enough to cause a long-term morbidity in any of the patients, as evidenced in the trials.

### Conclusion

It is evident that PFO closure would be superior to anti-platelet therapy for the prevention of recurrent strokes in patients with a PFO and a CS. However, due to the high prevalence of PFOs in the general population, a comprehensive, clinical history for the exclusion of other possible causes of stroke is necessary to select candidates for closure. The presence of a large defect, a sizable inter-atrial shunt, and an associated ASA might be considered an indication for the closure of a PFO. The RoPE scoring system would be beneficial in selecting ideal candidates. A PFO closure may be considered as the initial therapy for those with a PFO, as well as those on aspirin and with a high RoPE score. Studies also suggest that anticoagulant therapy could have a significant benefit in the management of a CS compared with anti-platelet therapy alone and that anticoagulant therapy might be nearly or equally as effective as a PFO closure. However, due to limited head-to-head studies, the use of either anticoagulation or anti-platelet therapy might be considered based on individual factors. Again, the adherence to anticoagulant therapy and the bleeding complications associated with it favors PFO closure, especially in younger patients with lower risk factors. A PFO closure would also be a reasonable alternative for those with contraindications to oral anticoagulants. In Bangladesh, these are the device closure of PFO solely done by a Bangladeshi consultant & his team successfully in Evercare Hospital, Dhaka. We would also like to draw attention of our Neurologist colleagues from all over the country who are the first line physicians of these kinds of patients. Their helpful hands will lay the way to further success with confidence. Together we can help our distressed patients more and more.

### References

1. Benjamin EJ, Blaha MJ, Chiuve SE, et al. Heart disease and stroke statistics 2017 update: a report from the American Heart Association. *Circulation* 2017;135: e146–e603
2. Writing Group Members, Mozaffarian D, Benjamin EJ, Go AS, Arnett DK, Blaha MJ, Cushman M, Das SR, de Ferranti S, Despres JP, Fullerton HJ, Howard VJ, Huffman MD, Isasi CR, Jimenez MC, Judd SE, Kissela BM, Lichtman JH, Lisabeth LD, Liu S, Mackey RH, Magid DJ, McGuire DK, Mohler ER III, Moy CS, Muntner P, Mussolino ME, Nasir K, Neumar RW, Nichol G, Palaniappan L, Pandey DK, Reeves MJ, Rodriguez CJ, Rosamond W, Sorlie PD, Stein J, Towfighi A, Turan TN, Virani SS, Woo D, Yeh RW, Turner MB; American Heart Association Statistics Committee; Stroke Statistics Subcommittee. Heart disease and stroke statistics—2016 update: a report from the American Heart Association. *Circulation*. 2016;133: e38–e360.
3. Adams HP Jr, Bendixen BH, Kappelle LJ, Biller J, Love BB, Gordon DL, Marsh EE III. Classification of subtype of acute ischemic stroke. Definitions for use in a multicenter clinical trial. TOAST. Trial of Org 10172 in Acute Stroke Treatment. *Stroke*. 1993; 24:35–41.
4. Li L, Yiin GS, Geraghty OC, Schulz UG, Kuker W, Mehta Z, Rothwell PM; Oxford Vascular Study. Incidence, outcome, risk factors, and long-term prognosis of cryptogenic transient ischaemic attack and ischaemic stroke: a population-based study. *Lancet Neurol*. 2015; 14:903–913.
5. Hagen PT, Scholz DG, Edwards WD. Incidence and size of patent foramen ovale during the first 10 decades of life: an autopsy study of 965 normal hearts. *Mayo Clin Proc*. 1984; 59:17–20.
6. Overell JR, Bone I, Lees KR. Interatrial septal abnormalities and stroke: a meta-analysis of case-control studies. *Neurology*. 2000; 55:1172–1179.
7. Lechat P, Mas JL, Lascault G, Loron P, Theard M, Klimczak M, Drobinski G, Thomas D, Grosgeat Y. Prevalence of patent foramen ovale in patients with stroke. *N Engl J Med*. 1988; 318:1148–1152.
8. Lippmann H, Rafferty T. Patent foramen ovale and paradoxical embolization: a historical perspective. *Yale J Biol Med*. 1993; 66:11–17.
9. Reza AQ, Karim A, Khan MH, Rahman KA, Joarder MA, Talukder SU, et al. Patent Foramen Ovale Device Closure in a 27 Years Old Young Lady with Cryptogenic Ischaemic Stroke-First Case Report from Bangladesh. *Cardiovascular Journal*. 2021;13(2):227-34
10. O’Gara PT, Messe SR, Tuzcu EM, Catha G, Ring JC. Percutaneous device closure of patent foramen ovale for secondary stroke prevention. *Circulation* 2009; 119: 2743–47
11. Amarenco P, Bogousslavsky J, Caplan LR, Donnan GA, Hennerici MG. Classification of stroke subtypes. *Cerebrovasc Dis* 2009; 27: 493–501
12. Finsterer J. Management of cryptogenic stroke. *Acta Neurol Belg* 2010; 110: 135–47
13. Farb A, Ibrahim NG, Zuckerman BD. Patent foramen ovale after cryptogenic stroke—assessing the evidence for closure. *N Engl J Med* 2017;377:1006–9
14. Windecker S, Stortecky S, Meier B. Paradoxical embolism. *J Am Coll Cardiol* 2014; 64: 403–15
15. Overell JR, Bone I, Lees KR. Interatrial septal abnormalities and stroke: a meta-analysis of case-control studies. *Neurology* 2000;55:1172–79
16. Ropper AH. Tipping point for patent foramen ovale closure. *N Engl J Med* 2017;377:1093–95

17. Meissner I, Whisnant JP, Khandheria BK, et al. Prevalence of potential risk factors for stroke assessed by transesophageal echocardiography and carotid ultrasonography: the SPARC study. *Mayo Clin Proc* 1999; 74: 862–69
18. Loscalzo J. Paradoxical embolism: clinical presentation, diagnostic strategies, and therapeutic options. *Am Heart J* 1986; 112: 141–45
19. Wu LA, Malouf JF, Dearani JA, et al. Patent foramen ovale in cryptogenic stroke: current understanding and management options. *Arch Intern Med.* 2004; 164: 950–56
20. Kent DM, Thaler DE. The Risk of Paradoxical Embolism (RoPE) study: developing risk models for application to ongoing randomized trials of percutaneous patent foramen ovale closure for cryptogenic stroke. *Trials.* 2011;12:185
21. Kent DM, Ruthazer R, Weimar C, et al. An index to identify stroke-related vs incidental patent foramen ovale in cryptogenic stroke. *Neurology.* 2013; 81: 619–25
22. Prefasi D, Martínez-Sánchez P, Fuentes B, Díez-Tejedor E. The utility of the RoPE score in cryptogenic stroke patients 50 years in predicting a stroke-related patent foramen ovale. *Int J Stroke.* 2016; 11: NP7–NP8
23. Pinto FJ. When and how to diagnose patent foramen ovale. *Heart.* 2005; 91: 438–40
24. Homma S, Sacco RL, Di Tullio MR, Sciacca RR, Mohr JP. Effect of medical treatment in stroke patients with patent foramen ovale. *Circulation* 2002; 105: 2625–31
25. Sacco RL, Prabhakaran S, Thompson JL, et al. Comparison of warfarin versus aspirin for the prevention of recurrent stroke or death: subgroup analyses from the Warfarin-Aspirin Recurrent Stroke Study. *Cerebrovasc Dis* 2006; 22: 4–12
26. Zhang C, Kasner S. Diagnosis, prognosis, and management of cryptogenic stroke. *F1000Res.* 2016; 5: F1000
27. Montalvo MJ, Siket MS, Jayaraman MV, Yaghi S, Silver B. Advances in the management of transient ischaemic attack and stroke. *Euro Med J Neuro* 2016; 4:101–7
28. Windecker S, Wahl A, Nedeltchev K, et al. Comparison of medical treatment with percutaneous closure of patent foramen ovale in patients with cryptogenic stroke. *J Am Coll Cardio* 2004;44:750–8
29. Furlan AJ, Reisman M, Massaro J, et al. Closure or medical therapy for cryptogenic stroke with patent foramen ovale. *N Engl J Med* 2012; 366: 991–9
30. Bridges ND, Hellenbrand W, Latson L, Filiano J, Newburger JW, Lock JE. Transcatheter closure of patent foramen ovale after presumed paradoxical embolism. *Circulation* 1992; 86:1902–08
31. Martín F, Sánchez PL, Doherty E, et al. Percutaneous transcatheter closure of patent foramen ovale in patients with paradoxical embolism. *Circulation* 2002;106:1121–26
32. Bruch L, Parsi A, Grad MO, et al. Transcatheter closure of interatrial communications for secondary prevention of paradoxical embolism: single-center experience. *Circulation* 2002;105:2845–48
33. Pollice F, Pollice P, Jacob L. Percutaneous transcatheter closure of patent foramen ovale in patients with paradoxical embolism. *EJCM* 2013;2:3-8