

An Overview of Childhood Ocular, Orbital and Surface Tumor with Clinical Updates

Dr. Soma Rani Roy¹, Dr. Fahmida Huque²

Abstract

Childhood tumor is different from but has a wide range varieties in types and presentation due to its origin from different embryogenic layers. Pediatric patients mostly depend on their parent or caregiver for seeking medical attention thus many ocular tumor present with unnecessary delay. Most childhood ocular tumors are benign but there are also life threatening tumors. In this paper a variety of intraocular, orbital and surface tumors are reviewed with their key sign of diagnosis and current treatment modalities. Though most of these tumor present at tertiary eye hospital, the overall knowledge about these tumors can help ophthalmologists in diagnosis and proper referral.

Keywords: Childhood tumor, retinoblastoma, rhabdomyosarcoma, dermoid cyst, conjunctival nevus.

(*J.Natl.Inst.Ophthalmol.2022;5(1):51-68*)

Introduction

Though childhood cancer are rare, approximately 400,000 children (0-19 years) develop cancer each year.^{1,2} In USA the incidence rate of childhood cancer in 1975 was about 0.8% per year which showed an increasing trend from 1997 to 2018 and was 1%.³ Childhood cancer is the 2nd most common cause of child death under 15 years after accident.⁴ According to American

Cancer Society, in 2022 there will be about 3,360 new cases of eye cancer in USA.⁵ In UK, eye cancer is not among the 20 most common cancers and accounting for less than 1% of all new cancer cases (2016-2018).⁶ In India, the incidence of eye cancer is estimated to be <0.5%.⁷ Pediatric ocular tumor are less common in comparison to adult tumor and also varies in type. One study from UK showed the annual incidence of eye cancer under 15 years were 3.5/1,000,000 but it was 11.8 /1,000,000 in case of under 5 years.⁸ Benign tumors are more common in children than malignant one. Metastatic tumor also affect them and common site of deposition is orbit. Dermoid cyst, retinoblastoma and leukemia are the commonest benign, malignant and metastatic ocular tumor in children respectively.

In this paper, we reviewed the epidemiology, clinical manifestations and current treatment modalities of common childhood tumors.

Classification

There are variation in site of origin and time of presentation of ocular tumors between pediatric group and adults. Some tumors are congenital and may present in the first year of life and other may present on later life. Pediatric tumor can be classified as tumor or tumor like lesion of orbit, intraocular tumors and surface tumors. (Table 1,2, 3)

¹ Resident surgeon and Head of Oculoplastics & Ocular Oncology, Chittagong Eye Infirmery.

² Senior Assistant Surgeon, Chittagong Eye Infirmery

Address of correspondence:

Dr. Soma Rani Roy
MBBS, DCO, FCPS, FICO, MRCS (Glas), MRCS (Edin)
Resident Surgeon & Head of Oculoplastic &
Ocular Oncology dept.
Chittagong Eye Infirmery
Chattogram-4202, Bangladesh.
Phone: +8801711484534
Email: dr.somaroy2020@gmail.com
ORCID Id: 0000-0002-4495-4489

Table 1: Childhood intraocular tumor

Retinoblastoma Medulloepithelioma(Iris &ciliary body) Astrocytoma Xanthogranuloma of iris Congenital hypertrophy of retinal pigment epithelium Combined hamartoma of the retina and retinal pigment epithelium Congenital melanocytosis Retinal hemangioblastoma Retinal cavernous hemangioma Choroidal hemangioma

Adopted from: WHO classification 2018

Table 2: Childhood orbital tumor (Modified Schield classification)

<p>Cystic Dermoid cyst Epithelial cyst Mucocele Microphthalmos with cyst Lacrimal gland cyst Hematic cyst</p> <p>Rhabdomyosarcoma</p> <p>Inflammatory simulating tumor Inflammatory pseudotumor Myositis Sarcoid nodule</p> <p>Adipose containing Dermolipoma Liposarcoma</p> <p>Vasculogenic Capillary hemangioma Lymphangioma Cavernous hemangioma Orbital varix Arteriovenous malformation</p> <p>Lacrimal gland/fossa Dacryoadenitis Ectopic lacrimal gland Epithelial tumors Dacryopse</p>	<p>Optic nerve/meningeal Optic nerve glioma Orbital meningioma Peripheral nerve tumor Neurofibroma</p> <p>Secondary/metastatic Neuroblastoma Retinoblastoma with orbital extension</p> <p>Lymphoid tumor/leukemia Acute lymphatic leukemia Burkitt's lymphoma Granulocytic (myeloid) sarcoma</p> <p>Osseous, fibro-osseous, cartilaginous Osteoma Fibrous histiocytoma Fibro sarcoma Fibrous dysplasia Proliferative nodular fasciitis Solitary fibrous tumorb</p> <p>Histiocytic Infantile xanthogranuloma Histiocytosis x</p> <p>Melanocytic</p> <p>Miscellaneous Pilomatrixoma Malignant small cell tumor</p>
---	--

Adopted from: "A Demographics of Pediatric Orbital Lesions: A Tertiary Eye Center Experience in Saudi Arabia"⁹

Table 3: Childhood Ocular surface tumor

Epithelial	Stromal
<p>Non melanotic- Conjunctival epithelial cyst, Dacryoadenoma, Squamous papilloma, OSSN (Xeroderma pigmentosa)</p> <p>Melanotic Conjunctival melanocytic nevus, Congenital ocular melanosis</p> <p>Choriostoma Epibulbar dermoid, Dermolipoma</p>	<p>Vascular stromal pyogenic granuloma, Capillary hemangioma, Lymphangioma</p> <p>Histiocytic tumor Juvenile xanthogranuloma</p> <p>Myogenic Rhabdomyosarcoma</p> <p>Metastetic Leukemic infiltrate</p>

Adapted from: Tumors of the ocular surface: A review.¹⁰

Intraocular Tumor

Retinoblastoma

Retinoblastoma (RB) is the most common primary intraocular malignancy of children worldwide. It originated from the primitive retinoblasts which arises from the inner neuroepithelial layer of embryonic optic cup. The incidence rate is 1: 16000 to 1: 18000 live birth¹¹ and about 9000 new cases are detected every year. This tumor is found in all continents but 43% of global burden lives in 6 countries of Asia (India, China, Indonesia, Pakistan, Bangladesh & Philippines).¹²

The tumor may arise at any age but the median age at diagnosis is 1.5 year (18 months). According to Retinoblastoma Collaborative Study about 90% cases are detected before age of 6 years. This tumor occasionally detected as a congenital or even as intrauterine disorder¹³. It may be heritable or non-heritable and may present as bilateral (40%) or unilateral (60%), with multifocal or unifocal locality according to their heritance and penetration. Though improved treatment facilities has increased the survival rate more than 95% in developed countries¹⁴ but still retinoblastoma is a deadly cancer worldwide, with an estimated death rate of more than 40% and most are reported from Africa and Asia.

Retinoblastoma is an example where the genetic nature of cancer was revealed¹⁵. It arises due to inactivation of both the allele of Rb1 gene which is located 13q14 chromosome. Recent study shows that the retinoblastoma may differ in mutagenic pathway as example some retinoblastoma tumor can caused by mutation of Rb1 mutation¹⁵ and others by amplification of MYCN gene¹⁶.

The most common presenting sign of retinoblastoma is leucocoria (Fig-1). The others are strabismus, hyphema, hypopyon, secondary glaucoma, orbital cellulitis, proptosis, phthisis bulbi etc. Usually children from under developed countries present with more advanced stages. The heritable retinoblastoma usually presents at early age with bilateral or unilateral but multifocal tumors and non- heritable are at later age as unilateral and unifocal tumor. There are some other causes of leucocoria which may make confusion with this devastating cancer. The most common differentials are persistent hyperplastic primary vitreous (PHPV), coat's disease, ocular toxocariasis and retinopathy of prematurity (ROP)¹⁷. So complete ophthalmic examination with full mydriasis under general anesthesia is the first thing to do. Imaging study is needed for appropriate grouping and staging of tumor and for planning of management.

Following detailed examination of the eye under general anesthesia, the tumor is grouped. There are several classifications for grouping and staging but most commonly the International Retinoblastoma Classification (Group A to E) is followed. Ultrasonography (B-Scan), computed tomography (CT) and magnetic resonance (MRI) imaging are frequently used to support the diagnosis of RB as well as to rule out extraocular spread or the presence of intracranial metastasis or associated pinealoblastoma.

US (B-Scan) demonstrate RB as an intraocular mass with characteristic calcifications as indicated by high internal reflectivity (Fig-1). Demonstration of intraocular calcification is highly characteristic for retinoblastoma (Fig-1), especially in children below three years of age. Though CT scan causes low-dose radiation which is a risk for a second malignant neoplasm in heritable retinoblastoma, spiral CT can be considered over conventional CT, due to its less radiation exposure¹⁸. MR imaging with gadolinium enhancement and fat suppression is the preferred modality for evaluation of extraocular spread, optic nerve invasion, subarachnoid seeding, intracranial involvement and also for diagnosis of rare cases of trilateral RB (bilateral RB and pinealoblastoma).

Management plan of retinoblastoma depends on the presentation whether it is bilateral or unilateral; intraocular or extra ocular and its extent of metastasis. In recent years retinoblastoma are being treated with a multidisciplinary team approach comprising of ocular oncologist, pediatric oncologist, radiation oncologist, pediatrician, ocular pathologist, ophthalmologist and geneticist.¹⁹

There are different treatment modalities to treat retinoblastoma like¹⁹

- A) Local therapy
 - i) Laser photocoagulation (Argon/YAG laser),
 - ii) Trans pupillary thermo therapy (Diode laser),
 - iii) Cryo therapy.
- B) Chemotherapy
 - i) Local chemotherapy-, Periocular, Intravitreal and Intra cameral
 - ii) Systemic chemotherapy

- iii) Intra- arterial chemotherapy
- iv) Intrathecal chemotherapy
- C) Radiation therapy
 - i) Plaque radiation therapy (Brachytherapy)
 - ii) External beam radiation therapy
 - iii) Proton beam therapy
- D) Surgery
 - i) Enucleation (Intraocular)
 - ii) Exenteration (Extraocular)

Currently one of the main management protocols for retinoblastoma is intravenous chemotherapy in conjunction with local therapy and most oncology centers practice the three regimen therapy with Vincristine sulfate, Etoposide phosphate and Carboplatin for 6 cycles every 3-4 weeks²⁰ u for intraocular and 12 cycles for extraocular tumor. Intravenous chemotherapy is indicated in bilateral cases; unilateral case grouped as B, C and D; histopathological high risk cases and extraocular cases. These chemotherapeutic agents has some toxicities like cytopenias (89%), neutropenic fever (28%), infection (9%), gastrointestinal symptoms, dehydration, and vincristine neurotoxicity (40%)²¹.

Transpupillary thermo therapy (TTT) is currently the most commonly used adjuvant therapy. Treatment can be undertaken alone as a primary treatment (for a very small tumor of <3mm in diameter) or in combination with chemotherapy. Laser photocoagulation is infrequently using today as it coagulates the vascular supply decreasing the delivery of chemotherapeutic agents to eye. Cryotherapy is also frequently used for peripheral tumors under 3 mm greatest dimension and subretinal seeds and a triple freeze-thaw technique is used with a tumor control rate of up to 90%.¹⁹

Local chemotherapies are used to control the recurrent and residual vitreous seeds along with the systemic chemotherapy to increase the vitreous concentration without increasing the dose of systemic chemotherapy thus preventing some serious adverse effects. Intra-arterial chemotherapy is used as primary treatment or in intravenous chemo resistant cases. Carboplatin, topotecan, and melphalan are used as chemotherapeutic agent and need intervention radiologist for this procedure. Along with

toxicities of chemotherapeutic agents, its procedure can cause devastating ocular complication like central artery occlusion.

Plaque radiotherapy with I 125 and Ru 106 is a localized radiotherapy used as a primary or more commonly a secondary treatment modality for tumors that fail with other focal therapies. The mostly known external beam radiation (EBRT) therapy has less use now because of its local adverse effect on eye and associated high incidence of second cancers in the irradiated zone years after, in the hereditary forms of retinoblastoma. EBRT has been advocated in certain situations following enucleation for RB, most notably for orbital recurrence and involvement of surgical margin of the optic nerve²². A dose of 45 Gray is delivered to the target volume by two electron beams over 5 weeks. New modality radiation therapy that is proton beam radiotherapy (PBRT) shows better target volume coverage while sparing non target structures but is highly costly.

In recent years, the frequency of primary enucleation has decreased tremendously but in underdeveloped and developing countries, enucleation is still now the prime treatment modality. Enucleation is usually done in primary unocular Group-E retinoblastoma and non-responding or poorly responding tumor of bilateral disease. During enucleating, minimal manipulation and

'no-touch' surgical techniques is practiced with resection of a long optic nerve stump, preferably more than 10mm is recommended. The enucleated eye is examined macroscopically to any optic nerve abnormality and extra ocular extension. All specimen should be sent for histopathological examination and also need collaboration with histopathologist. The use of orbital implants (non-integrated or integrated) and prosthesis helps in achieving an acceptable cosmetic appearance following enucleation. Along with the treatment, routine follow up, screening of sibling and genetic counseling is mandatory. Following tumor regression, subsequent examination should be every 3 months for the 1st year, 4 months for the 2nd year, every 6 months until the child reaches 6 years of age, and yearly thereafter.¹⁹

Genetic screening for RB1 mutation by DNA analysis of the child's tumor and peripheral blood can help in the identification of patients with a germline mutation and aids in planning for better follow-up care, prevents unnecessary examination under general anesthesia and enables early tumor detection in predisposed individuals²³. Genetic counseling supports families to understand the medical diagnosis, disease prognosis and risk to transmission of disease to offspring. The RB survivors need both visual and psycho-social rehabilitation by spectacles, low vision aids, cataract surgery and custom made prosthesis.

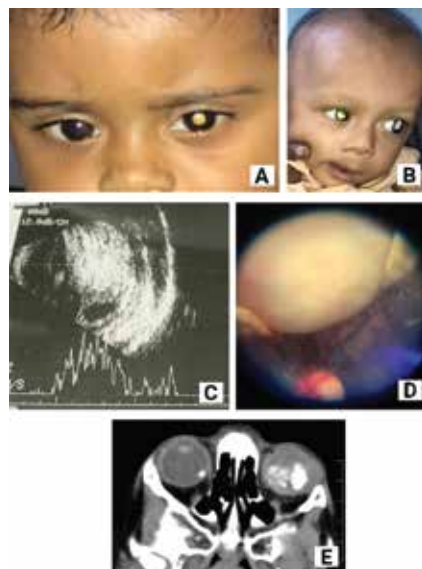


Figure 1: Retinoblastoma: A) Unilateral RB, B) Bilateral RB, C) B-Scan showing intraocular mass lesion with calcification D) Group C tumor E) CT scan showing bilateral intraocular RB with calcification.

Medulloepithelioma

Intraocular medulloepithelioma is a congenital tumor arises from primitive medullary epithelium especially from non-pigmented ciliary epithelium of ciliary body but rarely can arise from the optic disc, iris, and retinal stalk.²⁴

It usually presents unilaterally and in 75-90% cases by the first decade of life, though adult can also be affected.²⁴ This tumor is slow growing and histologically may be benign, malignant and teratoid or non teratoid.²⁵

Patients present with leucocoria and usually with secondary effects of large tumor like loss of vision, pain, cataract (sectoral or total), retrolental membrane and neovascular glaucoma. Slit lamp examination reveal medulloepitheliomas as irregularly shaped with smooth surfaces and gray-pink colored intraocular mass with conjunctival congestion, sentinel episcleral vessels subluxation of lens, iris deposits, corneal stromal haze, and ectropion uvea. Tumor contain intratumoral cyst in 50% of cases which may float in anterior chamber and highly suggestive of a medulloepithelioma. Rarely it, may be pigmented. Medulloepithelioma cytologically malignant but distance metastasis are rare and only nodal metastases can occur in neck with a predilection to parotid gland.^{24, 25}

Literature search showed some association of ciliary medulloepithelioma with Pleuropulmonary blastoma (PPB) which is a rare malignant neoplasm of the lung that manifests with seemingly innocuous lung cysts that arise from embryonal cells. Genetic mutation is found in DICER1 gene in both diseases.²⁶

Ultrasound B-scan, ultrasound biomicroscopy (UBM), anterior segment optical coherence tomography (AS-OCT), CT and MRI are used to diagnose this tumor. B-scan demonstrate heterogeneous, highly echogenic mass localized in ciliary body and also the irregular intratumoral cystic areas. AS OCT and UBM can detect the radial expansion and height of lesion in ciliary body with demonstration of cysts. Magnetic resonance imaging (MRI) is the standard preoperative investigative modality.²⁷ The tumor looks like heterogeneous mass containing both

solid and cystic components which arise behind the lens.

Treatment for ciliary body medulloepithelioma are cryotherapy, plaque radiotherapy, external beam radiotherapy, local resection, and enucleation. Enucleation is a standard treatment protocol in advance cases with large tumor and neovascular glaucoma. In cases with orbital extension, exenteration and extended enucleation is performed. All surgeries should be performed with minimal handling.

Smaller tumors (not exceeding 3-4 clock hours) may be treated with cryotherapy, radiotherapy, or local resection. Cryotherapy can also use in recurrent tumors. Local resection has tendency for recurrence. Plaque brachytherapy with I 125 and Ru 106 is also used to treat small to medium size tumors. In metastatic cases or tumor arises from optic nerve, combination of chemotherapy, brachytherapy, enucleation or exenteration may need. Chemotherapy includes combination of ifosfamide, carboplatin, and etoposide.^{24, 25}

Often medulloepithelioma is misdiagnosed as cataract, glaucoma or uveitis due to secondary manifestations of the disease and are treated for these conditions for a long time, and some patients even undergo surgical intervention. All these causes significant delay in diagnosis and create possible routes for extraocular extension of tumor that drastically alters the prognosis of these patients.

Retinal Astrocytic Hamartoma

It is a benign glial tumor arises from retinal astrocytes as multiple or solitary lesion. Appearance are creamy –white, elevated, well-circumscribed either small, smooth, flat, non-calcified or mulberry appearance which are yellow white calcified lesion. Fifty percent of tuberous sclerosis (TS) is associated with retinal astrocytoma and if astrocytoma is diagnosed there should be search for tuberous sclerosis. The incidence of TS is 1 in 10,000.²⁸ This may rarely associated with neurofibromatosis. Diagnosis is done clinically and optical coherence tomography can be used to evaluate the extent of the tumor and evaluate for macular edema or subretinal fluid.

Observation is enough in most case as these lesion create no clinical symptoms. They may resolve spontaneously or may become symptomatic by enlarging and creating macular oedema, lipid exudates or serous detachment and raised intraocular pressure. If macular oedema or exudative detachment does not resolve spontaneously within 6 weeks, treatment is indicated.²⁵

Retinal hemangioblastoma

It is a vascular hamartoma associated with Von Hippel-Lindau (VHL) syndrome. It was previously known as retinal capillary hemangioma. Age of presentation is in first two decades of life and are bilateral and multiple. Patients with retinal hemangioblastoma should be evaluated for brain and spinal cord hemangioblastoma, renal, pancreatic and ear lesion. This is genetically autosomal dominant disease due to mutation of vhl gene and family member should be screened. For detection and confirmation of retinal hemangioblastoma, fluorescent angiography (FA) is the best test as it shows rapid filling of the feeding artery, then the tumor, followed by rapid exit through the draining vein.²⁹ Management should include both systemic and ocular evaluation. Complete dilated funduscopic examination and FA should be done from 5 years of age and younger children to detect pinpoint tumor. Treatment of the tumor depends on the clinical situation.²⁹ If tumor is associated with VHL syndrome, it tend to be more aggressive and nearly all tumor must be considered for treatment. In small (<3 mm) lesion laser photocoagulation or photodynamic therapy (PDT); in medium (3-6 mm) lesion PDT or cryotherapy and in large (>6 mm) size PDT, plaque radiotherapy, or internal resection by pars plana vitrectomy route can be employed. In asymptomatic cases where tumor is small, without subretinal fluid and not associated with VHL syndrome, can be observed. Treatment should be commenced if leakage ensues. Patients need multidisciplinary management with ophthalmologist, neurosurgeon, internal medicine specialist and ENT specialist.

Rhabdomyosarcoma

Rhabdomyosarcoma (RMS) is a soft tissue sarcoma and highly malignant tumor originating

from pluripotent mesenchyme.^{30,31} This disease usually presents first to an ophthalmologist. It most commonly occurs in the head and neck, with 10% of cases occurring in orbit. Typically, these tumors appear in the first decade of life,³² however RMS has been described at birth and in the eighth decade³³. Primary orbital RMS is mainly a disease of young children, where 90% of cases are presented before the age of 16 years and the mean age of onset is 7–8 years. There is a slight male-to-female preference, with a male:female ratio of 5.^{34,34}

Primary orbital RMS involves the orbit, eyelid, conjunctiva, and rarely, the uveal tract. The typical presentation is a rapid onset of unilateral proptosis (Fig-4A1), which usually develops over weeks (80–100%) or globe displacement (80%), generally downward and outward^{30,31,32} eyelid edema with ptosis and sometimes atypical presentations such as eyelid nodule.³⁵ An orbital RMS can invade the orbital bones and extend intracranially³¹, especially in the adult group and even after treatment with radiochemotherapy.³⁶ In orbital RMS, the metastatic spread is unusual; recurrence or metastasis usually occurs within the first three years after treatment. The most common site of metastasis is the lung³⁷, which also happens in bone and bone marrow mainly via the hematogenous route.³²

It is essential to take a thorough history of any child under two years of age presenting with an orbital mass.³¹ Imaging is also necessary for diagnosis. A biopsy should be conducted if RMS is suspected. Immunohistochemical studies establish the primary method of diagnosis. C.T scan and MRI are essential for the preoperative evaluation, staging, and follow-up of orbital RMS.³⁸ C.T. is necessary for detecting bone involvement. MRI is vital for better spatial resolution, soft-tissue contrast, and detection of intracranial spread.³⁹ The CT scan of an Orbital RMS at an early stage appears as homogeneous, isodense, soft tissue mass, not deformed by bone, but in more advanced cases with bone destruction, there is calcification.^{38,39,40} The intergroup Rhabdomyosarcoma Study (IRMS) has currently staged RMS as Group 1 to Group 5. A multidisciplinary approach is essential for treating orbital RMS. Several studies have

introduced different techniques, and they suggested combining surgery to remove all or as much as tumor with adjuvant chemotherapy and radiotherapy according to the stage of the disease.⁴¹ Previously, orbital RMS was primarily treated by exenteration. The overall 5- years survival rate in children is about 70% while it is lower in adult.

Orbital dermoid

A dermoid cyst is a benign congenital choristoma formed by the sequestration of ectoderm during embryonic development⁴². The condition is the most common benign childhood tumor and accounts for 35 to 47% of all childhood orbital lesions and 89% of all cystic orbital lesions.⁴³ According to Sherman et al., superficial dermoid typically presents in infancy, but deep orbital dermoid usually presents at the age of about 18.⁴⁴ A dermoid cyst in orbit is usually associated with

the zygomaticofrontal and fronto-ethmoidal sutures.⁴⁵ Based on their relationship to the interzygomatic line on the C.T. scan, superficial and deep cysts are all classified according to their relationship with suture lines.⁴⁶⁻⁵⁰

In addition to cosmetic deformity, dermoid cysts cause mechanical ptosis and proptosis (Figure 2). A ruptured cyst can cause pain, swelling, and redness due to inflammation. Histologically, dermoid cysts are filled with keratin and are surrounded by stratified squamous epithelium. Dermoid cysts also contain hair follicles, sebaceous glands, and sweat glands.^{42,51} The definitive treatment is to complete surgical excision without disrupting the cyst wall to avoid recurrence.⁵² Incisions in the eyelid crease were recommended for the treatment of superficial superotemporal dermoid cysts. Cosmetic results are better with this incision.

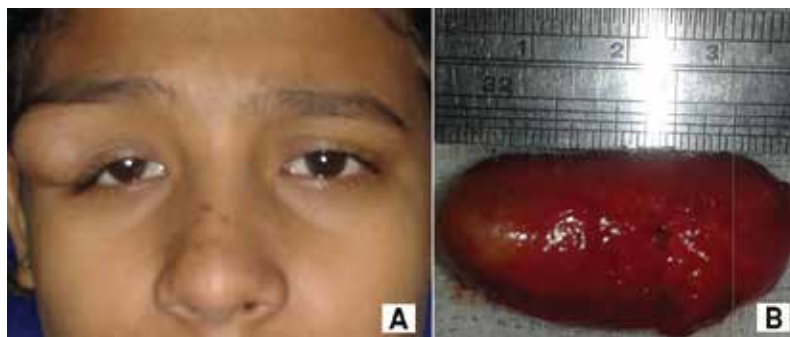

Figure 2: Dermoid cyst: A) & B) Pre and post- operative picture

Plexiform Neurofibroma

Plexiform neurofibroma (PNF) is a neuroectodermal hamartoma and represent 1-2% of all orbital tumor. PNF is diagnostic of neurofibrosis (NF)-1, genetically autosomal dominant and typically present in the first decade of life.⁵³

Any peripheral nerve is affected by the lesion but sensory nerves of orbit and eyelid are usually involved. Orbital lesion may cause proptosis, bony expansion and dysplasia of sphenoid bone which may cause temporal lobe herniation and pulsatile proptosis. Eyelid PNFs configured like 'S' due to thickening of nerve, fat deposition and

horizontal redundancy. The lesion feels soft and it is described as "a bag of worms".²⁵ There is gradual increase of lesion causing ptosis of variable degree and even facial disfigurement. Patients need regular ophthalmic examination as there is chance of amblyopia, anisometropia, strabismus, ipsilateral glaucoma and optic nerve glioma.(Figure 3). PNF has a 7 – 10% risk of malignant transformation to sarcoma.⁵⁴

Diagnosis is made by clinical examination and imaging like CT or MRI can help in determining the extent of tumor involvement, amount of bony dysplasia, and can aid in surgical planning.

Treatment is the surgery to relief the specific symptoms but only debulking can be done as complete removal of the tumor is not possible

due to its infiltrative nature. As PNF is progressive in nature, multiple surgical session may need.

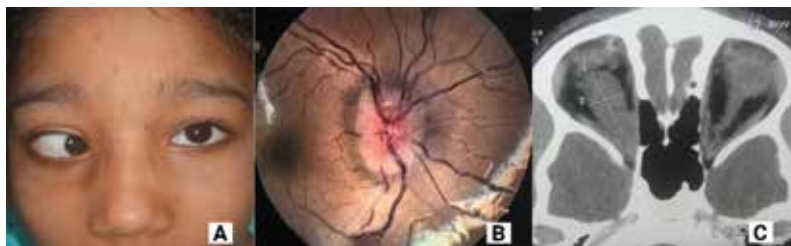

Figure 3 NF-1: A) Associated with right eye proptosis with squint, B) Disc swelling C) CT showing fusiform thickening of optic nerve.

Neuroblastoma Metastases

Neuroblastoma arises from neural crest cells of adrenal gland (most frequently) (Figure 4 C2), neck, chest, abdomen or spine and the most common primary childhood tumor that metastasize to orbit.⁵⁵ Children below 4 years are usually affected and incidence is approximately 1-3 in 100,000 cases. Neuroblastoma constitute 6-10% of all pediatric tumor and about 15% tumor related death in children.⁵⁶ In 1-2% cases, neuroblastoma may be inherited as autosomal dominant.⁵⁷ Orbital metastasis most commonly present as periorbital and eyelid ecchymosis which is known as raccoon eyes. Second common presentation is unilateral or bilateral proptosis (Figure 4 C1). Primary orbital presentation is found in 8% cases.⁵⁵ Periocular oedema, subconjunctival haemorrhage, vision loss or decrease ocular motility are some less common presentation. These symptoms may associated with pancytopenia, anaemia, fever, abdominal pain and hepatosplenomegaly. Patient may present with Horner's syndrome if tumor arises from sympathetic chain that is in thoracic neuroblastoma. Diagnosis is made on the basis of history, clinical examination and exclusion of recent trauma. Imaging (CT or MRI) of orbit and brain will show the preference of involvement for posterolateral orbital wall and metastasis appear as well circumscribed or ill-defined lesion. PET/CT now have been shown successfully staging and monitoring the disease by improve detection of smaller lesions and provide anatomic detail for surgical planning⁵⁸. Urinary and serum catecholamines including homovanillic acid (HVA) and vanillylmandelic

acid (VMA) were previously thought as more specific and sensitive but recent studies shows it not always present and not so much sensitive.⁵⁹ Treatment started by stratification depending on clinical features (age at presentation, staging) and specific tumor biological markers that include histopathological analyses, chromosomal abnormalities, and quantification of expression of the MYCN oncogene. Treatment consists of a combination of chemotherapy, radiation therapy, surgery, myeloablative therapy with stem cell transplant, immunotherapy such as anti-GD2 monoclonal antibody therapy.⁶⁰

These multimodality treatment has increased the survival rate. The prognosis of disseminated neuroblastoma is comparatively better in infants (80% 5-year survival) than children above one year of age (45% 5-year survival).

Leukemia

Leukaemia can present as pathology in any part of the eye like adnexae, conjunctiva, sclera, cornea, anterior chamber, iris, lens, vitreous, retina, choroid, and optic nerve. Ophthalmic involvement can be: (1) primary or direct leukaemic infiltration in orbit, anterior segment and central nervous system (Figure 4 B1&2) and (2) secondary or indirect involvement to retina and vitreous are due to anaemia, thrombocytopenia, hyperviscosity and immunosuppression.⁶¹

Acute lymphoblastic leukemia (ALL) is the commonest form of leukemia in children but in

case of ocular involvement (orbital or intraocular) acute myeloid leukemia (AML) found more (66.6%) than in those with ALL (15.1%).⁶² Granulocytic sarcoma is a rare solid tumor found with in orbit which is made up of primitive granulocyte precursors in AML. This mass may present prior to or after the diagnosis of AML and can be a sign of relapse in treated patients. Mean age of presentation is around 8-9 years with unilateral disease in 90% of cases.²⁵

The most common manifestation is leukemic retinopathy and presented with flame-shaped retinal hemorrhages, sometimes with white centers, in the nerve fiber layer. Others are intraocular presentation are perivascular infiltrations, microinfarctions, serous retinal detachments, hyphemas, pseudohypopyons, and iris masses. Optic nerve infiltration can present as papilledema secondary to CNS leukemia. Orbit is less commonly affected and present as a rapidly enlarging orbital mass, which can cause pain, eyelid swelling, ecchymosis, diplopia, and proptosis.²⁵ Previous reports have demonstrated that the presence of ocular involvement is associated with poor prognosis in acute

childhood leukaemias. Therefore, it is important to consider an ophthalmic evaluation at the time of diagnosis of acute leukaemia in adults and children.⁶¹

Diagnosis is made by history of systemic association, clinical examination and complete blood test with peripheral blood film give important clue in previously undiagnosed cases. Diagnosis is confirmed by bone marrow study. In Granulocytic sarcomas, blood examination usually show no clue and in such cases biopsy should be done. CT scan or MRI can be done to see the extent or to exclude other differentials. Treatment needs combination of pediatric oncologist, pediatrician, radiation oncologist and ophthalmologist. Usually systemic chemotherapy and bone marrow transplantation is the treatment customized based on specific genetic features of the malignancy. A leukemic infiltrate of the optic nerve is a medical emergency as there is chance of permanent loss of central vision if left untreated. The treatment in this case is low-dose radiation therapy often combined with intrathecal chemotherapy as soon as possible.

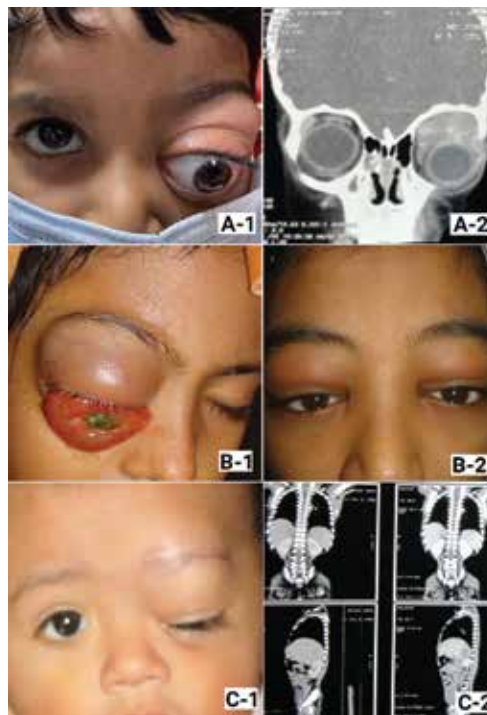

Figure 4: Orbital tumors: A1, A2) Rhabdomyosarcoma presented as proptosis with CT scan image B1, B2) Leukemic infiltration as proptosis and bilateral lid swell C1 C2) Neuroblastoma presented as unilateral proptosis and adrenal mass in CT scan.

Optic pathway glioma

Optic pathway glioma (OPG) is categorized as juvenile pilocytic astrocytomas and account for 4–6% of all brain tumors in children. It is a low-grade neoplasms arising from the pre-cortical optic pathways and can involve the optic nerve, optic chiasm, optic tracts, optic radiations, or the hypothalamus. Optic pathway gliomas most commonly affect children under ten years old (71%) and mean age at presentation is 8.8 years. These neoplasms may arise sporadically or in association with neurofibromatosis type 1 (NF1).⁶³ Approximately 15% to 20% of patients with NF-1 eventually develop an OPG, but only 30% to 50% of those patients will develop symptom.

As OPG is slow growing, it may unrecognized clinically for a long time. Patients typically present with complaints of decreased vision, due to growth of the glioma within the optic pathway nerves. Other signs are optic disc edema, pallor, atrophy, relative afferent pupillary defect, decreased color vision, pupil dysfunction, visual field defects, ocular motility problems, proptosis and even squint²⁵ (Fig-3 A,B). In 25% cases the OPG are confined to optic nerve but rest 75% show chiasm involvement and 40% of chiasm tumor will develop an extension to the hypothalamus or third ventricle.⁶⁴

CT and MRI is characteristic and specific for the disease process and MRI is more sensitive for detection of smaller lesions. The gliomas typically show fusiform enlargement of the optic nerve (Figure 3 C). Additional features include widening of the optic canal, variable contrast enhancement, and rarely eccentric enlargement of the nerve and cystic degeneration. MR imaging evaluates the intracranial disease better than CT and avoids radiation.²⁵ Optic nerve sheath meningioma is one of the differential which can be distinguished in MRI in T2W1. Meningioma are appear dark on T2WI, originate from the meninges, and avidly enhance on post-contrast images and OPG is hyperintense in T2W1 and post contrast show variable enhancement.⁶⁵

Treatment options are observation, chemotherapy and surgery. Gliomas which are in

stable stage and slow growing, can be kept in observation and sometimes there is spontaneous improvement. If tumors confined to the optic nerve at presentation, usually do not extend into the chiasm or develop extradural extension or metastases. In progressive disease, chemotherapy is the mainstay of treatment, usually with carboplatin and vincristine. Radiation therapy with fractionated gamma knife radiosurgery can be used if chemotherapy failed and retards or reverses progress in many cases but it has potential side effects. Surgery is also a therapeutic option, especially in patients with aggressive disease and no vision in the affected eye. Debulking of optic nerve glioma through a combined transcranial and orbital approach for en bloc resection of optic nerve gliomas is done in a proptotic blind eye.²⁵

Vascular lesion

Capillary hemangioma

Capillary hemangioma is one of the commonest benign vascular tumor and approximately 1 in 10 children are affected by this type of tumor of varying severity. It may present at birth and 90% of cases may become clinically obvious by age of two months. The tumor has a female predominance and more frequently affect premature or low birth weight infants.⁶⁶ Capillary haemangioma has many synonyms like strawberry haemangioma, strawberry nevus, capillary endothelioma, angioblastic haemangioma, hypertrophic haemangioma and benign haemangioma-endothelioma. Infantile haemangioma.

Classic superficial hemangioma appear as reddish lesion known as strawberry nevus, subcutaneous hemangiomas that appear bluish or purple and deep orbital tumors that present with proptosis without observable skin discoloration.⁶⁷ Sometimes capillary hemangioma may associate with systemic disease such as, a) Kasabach-Merrit syndrome associated with thrombocytopenic purpura; Consumptive coagulopathies associated with clotting factor defect; b) Microangiopathic hemolytic anemia (MAHA) where the erythrocytes are destroyed from coagulation, or are sheared or fragmented by high pressure forcing them through the abnormally small vessels of the hemangioma and c) PHACES Syndrome is a cutaneous condition

characterized by multiple congenital abnormalities like Posterior fossa malformations Hemangiomas, Arterial anomalies, Cardiac defects—eye abnormalities, Sternal cleft and supraumbilical raphe syndrome.⁶⁶

The natural history of capillary hemangioma shows manifestation within the first few weeks of life which grows rapidly in the first year of life called proliferative phase which is followed by the involutinal phase with intermediate stages of varying duration. The literature review showed, most cases of capillary hemangiomas involute spontaneously without intervention and with good cosmesis.⁶⁸ Diagnosis is based on clinical examination but Imaging is indicated to assess for the depth of the lesion and its relationship with adjacent structures in any atypical features on physical exam or presentation, or an associated underlying syndrome. Ultrasonography is a useful and inexpensive initial exam which typically demonstrates a well circumscribed mass with a vessel density of greater than 5 vessels/cm² with variable echogenicity. If more information is needed, MRI offers more sensitive evaluation of deeper lesions and their relationship to adjacent structures.²⁵

Small-sized tumors required regular follow-up and observation but treatment is needed to prevent the complications like amblyopia, squint, facial disfigurement, proptosis, exposure keratitis due to proptosis and rarely optic atrophy. Many treatment options are available for treating capillary hemangioma like systemic and intra-lesional corticosteroid, radiotherapy, laser therapy, vincristine, bleomycin, interferon alfa, cyclophosphamide, imiquimod, etc. But all of these have a variable degree of complications and results.⁶⁶ Nowadays, most ophthalmologists and physicians are using propranolol either oral, local application as gel and even topical drops as a first therapy to treat capillary hemangioma. Oral preparation showed successful outcomes with doses ranging from 1 mg/kg to 5mg/kg body weight (Figure 5A & B).⁶⁹ Propranolol causes a change in color and decrease in size. Early effects are vasoconstriction due to decreased release of nitric oxide and the result is color change within 1-3 days. Intermediate effects are due to the blocking of proangiogenic signals like vascular endothelial growth factor, basic fibroblast growth factor, matrix metalloproteinase and result in growth arrest. Long-term effects are induction of apoptosis in proliferating endothelial cells which results in tumor regression.⁷⁰

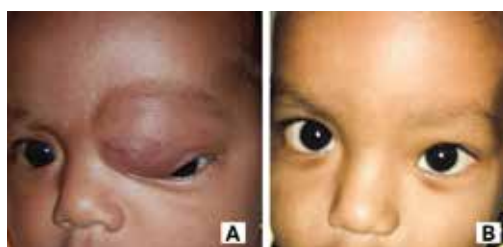

Figure 5: Capillary hemangioma: A) & B) Pre and post treatment picture with oral propranolol

Venous- Lymphatic malformation (VLMs)

It is a complex congenital lesion due to malformation of lymphatic and vascular structures during embryogenic period. The ratio of composition of venous and lymphatic component very according to location of lesion such as superficial lesions contain more lymphatic components where venous components are more in deeper lesions. About

4% of orbital masses are venous-lymphatic lesions. Forty three percent of the lesion are diagnosed before the age of 6 years and 60% before the age of 16 years.⁷¹

Proptosis and ptosis are the most frequent presentation (Figure 6 A). Proptosis may be fluctuating and sometimes acute painful proptosis occur secondary to hemorrhage, or

acute enlargement with concomitant upper respiratory tract infection.⁷² When hemorrhage occurs, variable-sized chocolate colored cysts may be identified. Other presentations are periocular mass and physical disfigurement, restriction of extraocular movements, mechanical blepharoptosis, amblyopia, astigmatism, strabismus and compressive optic neuropathy usually due to deeper lesion. Superficial lesions are detected earlier and can extend to the forehead and cheek.²⁵ Growth of these tumors may be accelerated due to hormonal changes during puberty and pregnancy.⁷³

In imaging these lesions appear as non – capsulated, irregular, lobulated lesion with ill-defined margin which infiltrate different ocular structure involving intraconal, extraconal, pre or post septal portion of the orbit (Figure 6 B). Both macrocyst and microcyst may present and macrocyst within the lesion may measure up to 2 cm. In MRI, various components of the malformation are seen better such as with lymphatic/proteinaceous fluid best seen on T1WI, blood products best seen on T1 fat-suppressed images, and non-hemorrhagic fluid best seen on T2W. Fluid-fluid levels that are

nearly pathognomonic for the diagnosis of a VLM that represent the various ages of hemorrhage within the cysts and absence of flow voids helps distinguish it from hemangiomas. In CT scan any associated bony changes of the orbit including widening of the orbital fissures and remodeling of the orbital walls can be better seen. In up to 70% of patients VLMs may associate with intracranial vascular anomalies and brain imaging should be performed concurrently.²⁵

Treatment occasionally need multidisciplinary management including interventional radiologists, craniofacial surgeons and ophthalmologists. Treatment options are observation, sclerosing agents, medical treatment and surgery. Medical management are not allowed in small children and surgery is the most challenging. Different agents are using as serotherapeutic agent such as sodium tetradecyl sulphate (3%), OK-432 (Picinibil), doxycycline, ethanol, pingyangmycin, and bleomycin (Figure 6C). This treatment, however, generates a significant local inflammatory reaction, which can include bleeding of the lesion and an increase in size, which resolves over weeks.²⁵

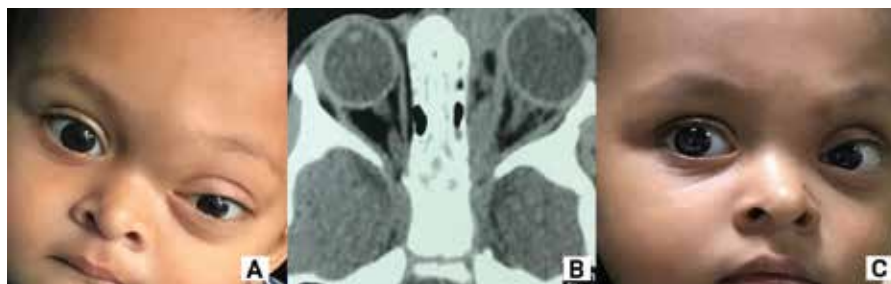


Figure 6: Veno – lymphatic malformation (Lymphangioma): A) Pre- treatment presentation as proptosis and periocular swelling, B) CT Scan showing multiple microcyst, C) Post treatment picture with intralesional Inj. Bleomycin.

Dermolipoma or lipodermoid

A lipodermoid or a dermoid is the most common type of orbital or epibulbar tumour in children (Figure 8 A&D). These are choristomas containing epithelium-derived tissues. ⁷⁴A conjunctival dermolipoma typically occurs near the lacrimal gland and lateral rectus muscle in the lateral canthus and superotemporal fornix. A dermolipoma, also known as a lipodermoid, is characterized by a deep fatty layer that gives it a

yellow clinical appearance.⁷⁵ On the surface, fine hairs are often visible. On histological examination, dermolipoma has layers of stratified squamous epithelium with a subepithelial stroma containing collagenous connective tissue and adipocytes. Furthermore, cartilage and glandular acini may be present in the stroma.⁷⁶ It is essential to consider Goldenhar-Gorlin syndrome in cases of lipodermoids and other ocular abnormalities.⁷⁷

Unlike many congenital syndromes, it occurs sporadically and cannot be inherited. However, autosomal dominant inheritance, as well as chromosomal abnormalities, have been reported.⁷⁸ Dermolipoma should be surgically resected with a limited debulking of the tumor because a complete or wide excision of the tumor may result in complications such as ptosis, diplopia, and lacrimal gland injury, which are unacceptable for an essentially cosmetic issue.⁷⁹ To avoid complications, it is important to isolate the lacrimal gland, levator and Müller's muscle complex, and lateral rectus muscle carefully.⁷⁶

Conjunctival melanocytic nevus

This lesion is benign in nature and usually appear in the first to second decade of life. Initially it remain superficial and as time passes the nest of pigmented epithelium migrate to stromal layers. This lesion is more prominent in Caucasian (89%) than Asian (5%).⁸⁰ Conjunctival nevi is mostly pigmented (84%) (Figure 8B) but may also be amelanotic or partially pigmented (16%).

Though size, color, and location can vary, most nevi (72%) are found in the interpalpebral area near the limbus. Other locations are caruncle, semilunar folds, fornix, tarsus, and cornea. These nevus has characteristic clear cysts with in lesion which strongly support the diagnosis.⁸¹ These tumor sometimes also demonstrate feeder vessels (64%) and intrinsic vascularity (77%). Conjunctival nevus can increase in size in growing young children, during puberty, pregnancy, and sun exposure.⁸¹ Chance of malignant transformation is <1%.⁸²

Periodic observation is the main stay of treatment. Observation is done annually with slit lamp measurement and serial photograph. Lesion is excised when any suspicion or cosmetic purpose and it is advisable not leave any residual lesion. The lesion should be suspected if lesion is more than 10 mm, exuberant feeder vessels, exuberant intrinsic vascularity and hemorrhage, lesions without cysts, lesions with dark uniform pigmentation, and corneal epithelial invasion >3 clock hours and 3 mm from the limbus.⁸³

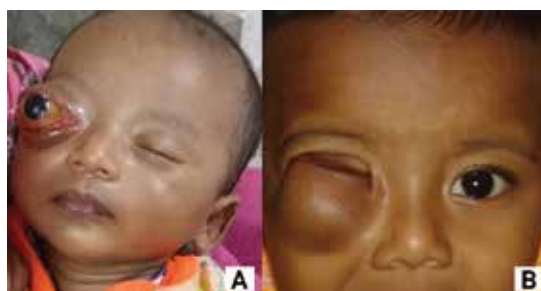

Figure 7: Congenital tumor: A) Rhabdomyosarcoma, B) Orbital cystic eye ball

Conjunctival epithelial inclusion cyst

Conjunctival epithelial cyst or inclusion cysts may spontaneous or posttraumatic. These cysts are smooth translucent and containing clear fluid (Figure 8C). The contents may be turbid, containing epithelial debris seen layered like pseudohypopyon. The cysts may remain stable and asymptomatic and rarely undergo spontaneous resolution. Excision is the treatment of choice for a cyst that enlarges or becomes symptomatic.⁸³

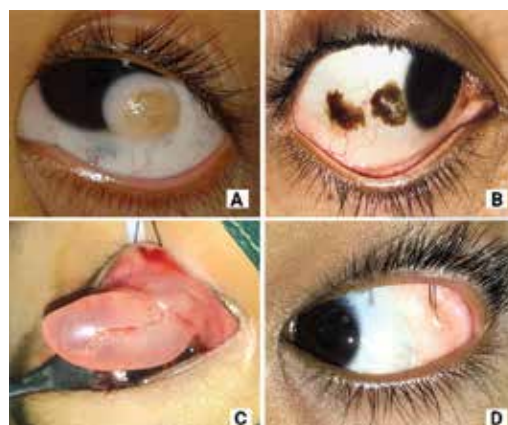


Figure 8: Surface tumors: A) Limbal dermoid B) Conjunctival nevus C) Conjunctival inclusion cyst D) Dermolipoma

Pyogenic granuloma

Pyogenic granuloma is a misnomer actually exuberant granulation tissue. This is fibrovascular response of a tissue may be tissue insult by surgical or nonsurgical trauma or inflammation. The onset is rapid and progressive. It presents as fleshy, elevated, red, richly vascular mass and may be ovoid, typically pedunculated, rarely broad based, and even mushroom shaped. It may be seen in any part of the conjunctiva, limbus, and the cornea.⁸⁴ Histopathologically, it is composed of granulation tissue with lymphocytes, plasma cells, scattered neutrophils, and numerous small caliber vessels. Topical steroid works well if diagnosis is earlier. For larger, unsightly, symptomatic or bleeding pyogenic granuloma, excision at the base followed by cauterization or cryotherapy is the choice.⁸³

Discussion

Child can be affected by primary, secondary or metastatic tumors. The primary tumors can be benign or malignant. The benign tumors are not always innocent, such as neurofibromatosis (NF 1), vascular tumors and retinal capillary hemangioblastoma. In case of NF 1, several surgical approaches may be needed for cosmetic reason as well as vision. It may also be associated with optic nerve glioma, and other retinal tumor. Retinal capillary hemangioblastoma is associated with Von Hippel Lindu disease which may be life threatening. In most time patients present when vision is lost in one eye. Early and prompt treatment can save the residual vision and systemic work up can save life also. The family members need proper counseling regarding the disease so that other member can be screened. Vascular tumor can also be vision threatening due sudden hemorrhage and need urgent management with admission and prompt treatment to reduce the orbital volume, to stabilize the blood vessel and plan for immediate surgical drainage. Some benign tumor are not aggressive and observation is enough, such as dermolipoma and conjunctival nevus. In regular ophthalmological practice, ophthalmologist often faces the demand of parents to remove these lesions. Counseling and regular follow up can reduce the unnecessary surgery and surgery can be done in indicated situation.

The childhood tumors are distinct form of tumor

that occur in adults. Many tumors are congenital and present earlier. As the general people do not have idea about childhood tumor, some life threatening tumor which start at early life usually presents with complications. Even some physicians are not so much aware that some tumors like retinoblastoma and rhabdomyosarcoma (Figure 7) can present at birth or few months after birth. Careful examination and proper referral can start prompt treatment and life can be saved. In case of metastatic tumor, choroid is the prime site for adult but in case of children orbit is the location of first deposit. So any rapid onset proptosis should be taken care by history evaluation, clinical examination of both ocular and systemic along with ancillary test such as complete blood count and peripheral blood film. In suspected cases biopsy should be done.

Tumors has some age preference of presentation such as orbital tumors that are commonly found between birth to 4 years of age and common tumors are capillary hemangioma, dermoid cyst, lymphangioma, neuroblastoma and teratoma; between 4 to 10 years lymphangioma, rhabdomyosarcoma, leukemic deposits, optic nerve glioma and dermoid cyst predominant; after 10 years dermoid, leukaemic deposits are commonly found. Retinoblastoma is the most common intraocular tumor worldwide and can present from intrauterine life to old age with median age of presentation is 18 months. Retinoblastoma is also an example of congenital, hereditary, genetic and familial disease. There is a big list of differentials of white pupillary reflex, and these can be identify by precise history, ocular examination under general anesthesia and imaging with B-Scan, CT Scan or MRI. Though B-Scan and CT scan shows calcification in retinoblastoma, other different vascular tumors and chronic ocular disease may also cause calcification. It should be in mind that, any calcification under age of three years should be suspect a case of retinoblastoma¹⁹. In suspected cases serial monthly B-scan can be done or for 2 to 3 months or enucleation is the choice of treatment where there is no visual potentials. The parents need actual understanding of disease, information regarding treatment facilities, outcome if being untreated, genetic nature of the disease and availability of the treatment which will increase the compliance of treatment.

Childhood tumor is a very wide spectrum of diseases. It is difficult to discuss all the tumors in one set up. The overall knowledge of ophthalmologist can diagnose the most of the childhood tumor. High suspicion is needed in atypical cases.

Conclusion

Childhood tumors are rare and different from adults. Proper knowledge and high suspicion of ophthalmologist along with counseling and timely referral can reduce morbidity and save life as well as vision.

Conflict of interest – None

Financial disclosure – Not funded.

Reference

1. Steliarova-Foucher E, Colombet M, Ries LAG, et al. International incidence of childhood cancer, 2001-10: a population-based registry study. *Lancet Oncol.* 2017;18(6):719-731.
2. World Health Organization. (2021). Cure All framework: WHO global initiative for childhood cancer: increasing access, advancing quality, saving lives. World Health Organization. <https://apps.who.int/iris/handle/10665/347370>
3. Coalition Against Childhood Cancer, utilizing statistics from 2021
4. Seigel R, et al.: *Cancer Statistics 2022*. CA: A Cancer Journal for Clinicians. 2022 Jan; 72(1):7-33. doi/full/10.3322/caac.21708.
5. American Cancer Society. *Cancer Facts & Figures 2022*. Atlanta, Ga: American Cancer Society; 2022.
6. Cancer Registration Statistics, England: 2017
7. Kaliki S, Das AV. Ocular and Periocular Tumors in India: An EyeSmart Electronic Medical Record Analysis of 9633 Cases from a Referral Center. *Middle East Afr J Ophthalmol.* 2021 Jan 19;27(4):199-203.
8. Juanarta P, Dahlan MR, Rezano A. Characteristics of Eye Tumor in Children Diagnosed at the National Eye Center Cicendo Eye Hospital. *Althea Medical Journal.* 2017;4(1):6-10.
9. Alkatan HM, Marek FA, Elkhamary S. A Demographics of Pediatric Orbital Lesions: A Tertiary Eye Center Experience in Saudi Arabia. *Journal of Epidemiology and Global Health* Vol. 9(1); March (2019), pp. 3-10.
10. Honavar SG, Manjandavida FP. Tumors of the ocular surface: A review. *Indian J Ophthalmol.* 2015 Mar;63(3):187-203. doi: 10.4103/0301-4738.156912. PMID: 25971163; PMCID: PMC4448231.
11. Broaddus E, Topham A, Singh AD. Incidence of retinoblastoma in the USA: 1975-2004. *Br J Ophthalmol.* 2009;93:21-3.
12. Jain M, Rojanaporn D, Chawla B, Sundar G, Gopal L, Khetan V. Retinoblastoma in Asia. *Eye (Lond).* 2019 Jan;33(1):87-96.
13. Salim A, Wiknjosastro GH, Danukusumo D, Barnas B, Zalud I. Fetal retinoblastoma. *J Ultrasound Med.* 1998;17:717-20
14. Kivela T. The epidemiological challenge of the most frequent eye cancer: Retinoblastoma, an issue of birth and death. *Br J Ophthalmol.* 2009;93:1129-31.
15. Friend SH, Bernards R, Rogelj S, Weinberg RA, Rapaport JM, Albert DM et al. A human DNA segment with properties of the gene that predisposes to retinoblastoma and osteosarcoma. *Nature.* 1986;323:643-6.
16. Rushlow DE, Mol BM, Kennett JY, Yee S, Pajovic S, Thériault BL et al. Characterisation of retinoblastomas without RB1 mutations: Genomic, gene expression, and clinical studies. *Lancet Oncol.* 2013; 14:327-34.
17. Shields JA, Shields CL, Parsons HM. Differential diagnosis of retinoblastoma. *Retina.* 1991;11:232-43.
18. Kaufman LM, Mafee MF, Song CD. Retinoblastoma and simulating lesions. cRole of CT, MR imaging and use of Gd-DTPA contrast enhancement. *cRadiol Clin North Am.* 1998;36:1101-17.
19. Roy SR, Kaliki S. Retinoblastoma: A Major Review. *Mymensingh Med J.* 2021 Jul;30(3):881-895. PMID: 34226484.
20. Shields CL, De Potter P, Himelstein BP, Shields JA, Meadows AT, Maris JM. Chemoreduction in the initial management of intraocular retinoblastoma. *Arch Ophthalmol.* 1996;114:1330-8.
21. D. L. Friedman, B. Himelstein, C. L. Shields et al., "Chemoreduction and local ophthalmic therapy for intraocular retinoblastoma," *Journal of Clinical Oncology*, vol. 18, no. 1, pp. 12-17, 2000.
22. Shield JA, Shield CL. *Intraocular tumor: a text and atlas*. WB Saunders Company. 1992.
23. Pradhan MA, Ng Y, Strickland A et al. Role of genetic testing in retinoblastoma management at a tertiary referral centre. *Clin Experiment Ophthalmol.* 2010;38:231-6.
24. Tadeballi SH, Shields CL, Shields JA, Honavar SG. Intraocular medulloepithelioma – A review of clinical features, DICER 1 mutation, and management. *Indian J Ophthalmol* 2019;67:755-62.
25. Ajay A. Rao AA, John H. Naheedy JH, Chen JY, Shira L. Robbins SL, Ramkumar HL. A Clinical Update and Radiologic Review of Pediatric Orbital and Ocular Tumors. *Journal of Oncology* Volume 2013, Article

- ID 975908, 22 pages
<http://dx.doi.org/10.1155/2013/975908>.
26. Sahm F, Jakobiec FA, Meyer J, Schrimpf D, Eberhart CG, Hovestadt V, et al. Somatic mutations of DICER1 and KMT2D are frequent in intraocular medulloepitheliomas. *Genes Chromosomes Cancer* 2016;55:418-27.
 27. Sangsiri RK, Wilson M, McCarville MB, Helton KJ. Imaging features of medulloepithelioma: Report of four cases and review of the literature. *Pediatr Radiol* 2013;43:1344-56
 28. K. Martin, V. Rossi, S. Ferrucci, and D. Pian, "Retinal astrocytic hamartoma," *Optometry*, vol. 81, no. 5, pp. 221-233, 2010.
 29. Shields CL, Douglass A, Higgins T, Samara WA, Shields JA. Retinal Hemangiomas: Understanding Clinical Features, Imaging, and Therapies. *Retina Today*. 2015, July/August 201:61-67.
 30. Rootman J., editor. Neoplasia. Vol. 54. Lippincott Williams and Wilkins; Philadelphia: 2003. pp. 262-268. (Diseases of the orbit: a multidisciplinary approach).
 31. Shields J.A., Shields C.L. Rhabdomyosarcoma: review for the ophthalmologist. *Surv Ophthalmol*. 2003;48:39-57.
 32. Turner J.H., Richmon J.D. Head and neck rhabdomyosarcoma: a critical analysis of population-based incidence and survival data. *Otolaryngol Head Neck Surg*. 2011;145:967-973
 33. Koopman J.H., van der Heiden-van der Loo M., van Dijk M.R., Bijlsma W.R. Incidence of primary malignant orbital tumours in The Netherlands. *Eye (Lond)* 2011;25:461-465.
 34. M.F. Mafee, E. Pai, B. Philip Rhabdomyosarcoma of the orbit. Evaluation with M.R. imaging and C.T. *Radiol Clin*, 36 (6) (1998), pp. 1215-1227 xii
 35. Frayer WC, Enterline HT. Embryonal rhabdomyosarcoma of the orbit in children and young adults. *AMA Arch Ophthalmol*. 1959;62:203-10.
 36. Kaliaperumal S, Tiroumal S, Rao V. Orbital rhabdomyosarcoma: A case series. *Indian J Cancer*. 2007;44:104-7
 37. Jurdy L, Merks JH, Pieters BR, Mourits MP, Kloos RJ, Strackee SD, et al. Orbital rhabdomyosarcomas: A review. *Saudi J Ophthalmol*. 2013;27:167-75.
 38. Terezakis S.A., Wharam M.D. Radiotherapy for rhabdomyosarcoma: indications and outcome. *Clin Oncol (R Coll Radiol)* 2013;25:27-35.
 39. Sohaib S.A., Moseley I., Wright J.E. Orbital rhabdomyosarcoma-the radiological characteristics. *Clin Radiol*. 1998;53:357-362
 40. Conneely M.F., Mafee M.F. Orbital rhabdomyosarcoma and simulating lesions. *Neuroimaging Clin N Am*. 2005;15:121-136.
 41. Jurdy L, Merks JH, Pieters BR, Mourits MP, Kloos RJ, Strackee SD, et al. Orbital rhabdomyosarcomas: A review. *Saudi J Ophthalmol*. 2013;27:167-75.
 42. New GB, Erich JB. Dermoid cysts of the head and neck. *Surg Gynecol Obstet* 1937;65:48-55.
 43. Shields JA, Bakewell B, Augsburger JJ, et al., "Space-occupying orbital masses in children: a review of 250 consecutive biopsies," *Ophthalmology*, vol. 93, pp. 379-384, 1986
 44. Sherman RP, Rootman J, and Lapointe JS, "Orbital dermoids: clinical presentation and management," *Br J Ophthalmol*, vol. 68, pp. 642-652, 1984.
 45. Chawda SJ, and Moseley IF, "Computed tomography of orbital dermoids: a 20-year review," *Clin Radiol*, vol. 54, pp. 821-825, 1999
 46. Bonavolontà G, Tranfa F, de Conciliis C, and Strianese D, "Dermoid cysts: 16-year survey," *Ophthal Plast Reconstr Surg*, vol. 11, pp. 187-192, 1995.
 47. Grove AS Jr, "Giant dermoid cysts of the orbit," *Ophthalmology*, vol. 86, pp. 1513-1520, 1979.
 48. Lane CM, Ehrlich WW, and Wright JE, "Orbital dermoid cyst," *Eye*, vol. 1, pp.504-507, 1987.
 49. Nugent RA, Lapointe JS, Rootman J, et al., "Orbital dermoids, features on C.T.," *Radiology*, vol. 165, pp. 475-478, 1987.
 50. Shields JA, and Shields CL, "Orbital cysts of childhood—classification, clinical features, and management," *Survey of Ophthalmology*, vol. 49, pp. 281-299, 2004.
 51. Reissis D, Pfaff MJ, Patel A, Steinbacher DM. Craniofacial dermoid cysts: histological analysis and inter-site comparison. *Yale J Biol Med* 2014;87(3):349-357.
 52. Lane CM, Ehrlich WW, and Wright JE, "Orbital dermoid cyst," *Eye*, vol. 1, pp.504-507, 1987.
 53. J. J. Dutton and G. K. Escaravage, *Ophthalmic Oncology*, edited by B. Esmaeli, Springer, Boston, Mass, USA, 2011.
 54. C. G. Filippi, A. Bos, J. P. Nickerson, M. B. Salmela, C. J. Koski, and K. A. Cauley, "Magnetic resonance diffusion tensor imaging (MRDTI) of the optic nerve and optic radiations at 3T in children with neurofibromatosis type I (NF-1)," *Pediatric Radiology*, vol. 42, no. 2, pp. 168-174, 2011.
 55. D'Ambrosio, J. Lyo, R. Young, S. Haque, and S. Karimi, "Common and unusual craniofacial manifestations of metastatic neuroblastoma," *Neuroradiology*, vol. 52, no. 6, pp. 549-553, 2010.
 56. Yang WJ, Zhou YY, Zhao F, Mei ZM, Li S, Xiang Y. Orbital neuroblastoma metastasis: A case report and literature review. *Medicine (Baltimore)*. 2019 Sep;98(36):e17038.

57. Mosse, et al. Identification of ALK as the Major Familial Neuroblastoma Predisposition Gene. *Nature*. 2008; 455 (7215): 930-935.
58. T. Pfluger, I. Schmid, E. Coppenrath, and M. Weiss, "Modern " nuclear medicine evaluation of neuroblastoma," *The Quarterly Journal of Nuclear Medicine and Molecular Imaging*, vol. 54, no. 4, pp. 389-400, 2010.
59. Ahmed S, et al. Neuroblastoma with orbital metastasis: Ophthalmic presentation and role of ophthalmologists. *Eye*. 2006; 20:466-470.
60. Johnson, et al. Antibody-based immunotherapy in high-risk neuroblastoma. *Expert Rev Mol Med*. 2007; 9(34): 1-21.
61. Sharma, T., Grewal, J., Gupta, S. et al. Ophthalmic manifestations of acute leukaemias: the ophthalmologist's role. *Eye* 18, 663-672 (2004).
62. Russo V, Scott IU, Querques G, Stella A, Barone A, Delle Noci N. Orbital and ocular manifestations of acute childhood leukemia: Clinical and statistical analysis of 180 patients. *Eur J Ophthalmol* 2008;18:619-623.
63. Robert-Boire V, Rosca L, Samson Y, Ospina LH, Perreault S. Clinical Presentation and Outcome of Patients With Optic Pathway Glioma. *Pediatr Neurol*. 2017 Oct;75:55-60.
64. Huang M, Patel J, Patel BC. Optic Nerve Glioma. [Updated 2022 May 24]. In: *StatPearls* [Internet]. Treasure Island (FL): StatPearls Publishing; 2022 Jan-. Available from: <https://www.ncbi.nlm.nih.gov/books/NBK557878/>
65. E. M. Chung, C. S. Specht, and J. W. Schroeder, "From the archives of the AFIP: pediatric orbit tumors and tumor like lesions: neuroepithelial lesions of the ocular globe and optic nerve," *Radiographics*, vol. 27, no. 4, pp. 1159-1186, 2007.
66. Roy SR, Nuruddin M. Periocular capillary hemangioma treated with low dose oral propranolol - presentation and outcome of 30 patients. *Arch Pathol Clin Res*. 2021; 5: 037-041.
67. Haik BG, Jakobiec FA, Ellsworth RM, Jones IS. "Capillary hemangioma of the lids and orbit: an analysis of the clinical features and therapeutic results in 101 cases." *Ophthalmology*. 1979;86(no. 5):760-792.
68. Bang G M, Setabutr P. Periocular Capillary Hemangiomas: Indications and Options for Treatment. *Middle East Afr J Ophthalmol*. 2010; 17(2): 121-128.
69. Pope E, Krafchik BR, Macarthur C, Stempak D, Stephens D, Weinstein M, et al. Oral versus high-dose pulse corticosteroids for problematic infantile haemangiomas: a randomized, controlled trial. *Pediatrics*. 2007; 119:e1239-47. Epub 2007 May 7.
70. C.H. Storch and P.H. Hoeger. Propranolol for infantile haemangiomas: insights into the molecular mechanisms of action. *British Journal of Dermatology*. 2010 Aug; 163(2):269-74.
71. Nassiri N, Rootman J, Rootman DB, et al: Orbital lymphaticovenous malformations: Current and future treatments. *Surv Ophthalmol* 60:383-405, 2015
72. E. M. Chung, J. G. Smirniotopoulos, C. S. Specht, J. W. Schroeder, and R. Cube, "From the archives of the AFIP: pediatric orbit tumors and tumorlike lesions: nonosseous lesions of the extraocular orbit," *Radiographics*, vol. 27, no. 6, pp. 1777- 1799, 2007
73. P. Dhellemmes, G. M. Breviere, C. Degrugillier-Chopinnet, ` and M. Vinchon, "Vascular lesions of the orbit in children," *Neurochirurgie*, vol. 56, no. 2-3, pp. 271-280, 2010
74. Balogh M. Lipodermoid: A case report. *Clin Eye Vis Care*. 1995;7:79-82
75. Jakobiec FA, Pineda R, Rivera R, Hsu-Winges C, Cherwek D. Epicorneal polypoidal lipodermoid: Lack of association of central corneal lesions with goldenhar syndrome verified with a review of the literature. *Surv Ophthalmol*. 2010;55:78-84.
76. McNab AA, Wright JE, Caswell AG. Clinical features and surgical management of dermolipomas Australian and New Zealand. *Journal of Ophthalmology* 1990;18(2):159- 62.
77. Mansour AM, Wang F, Henkind P, Goldberg R, Shprintzen R. Ocular findings in the facioauriculovertebral sequence (Goldenhar-Gorlin syndrome) *Am J Ophthalmol*. 1985;100:555-9
78. Choong YF, Watts P, Little E, Beck L. Goldenhar and cri-du-chat syndromes: A contiguous gene deletion syndrome? *J AAPOS*. 2003;7:226-7.
79. Kim E, Kim HJ, Kim YD, et al. Subconjunctival fat prolapse and dermolipoma of the orbit: differentiation on C.T. and M.R. *Imaging AJNR. Am J Neuroradiol* 2011;32(3):465-7
80. Cervantes G, Rodríguez AA Jr, LealAG. Squamous cell carcinoma of the conjunctiva: Clinicopathological features in 287 cases. *Can J Ophthalmol* 2002;37:14-9.
81. Shields CL, Belinsky I, Romanelli Gobbi M, Guzman JM, Mazzuca D Jr, Green WR, et al. Anterior segment optical coherence tomography of conjunctival nevus. *Ophthalmology* 2011;118:915-9.
82. Shields CL, Demirci H, Karatza E, Shields JA. Clinical survey of 1643 melanocytic and nonmelanocytic conjunctival tumors. *Ophthalmology* 2004;111:1747-54
83. Honavar SG, Manjandavida FP. Tumors of the ocular surface: A review. *Indian J Ophthalmol*. 2015 Mar;63(3):187-203.
84. Ferry AP. Pyogenic granulomas of the eye and ocular adnexa: A study of 100 cases. *Trans Am Ophthalmol Soc* 1989;87:327-43.