

Clinical Profile of Patients with Bilateral Optic Disc Swelling Attending in an Apex Eye Hospital in Bangladesh

Ershadul H. Rahat¹, Shayamal K. Sarkar², Mujtahid M. Hossain³, Farjana S. Shimu⁴, Shafiul Mostafiz,⁵ Farzana Hossain⁶

Abstract

Background: Patient with optic disc swelling demands thorough ophthalmic as well as systemic evaluation as it may reflect intraocular as well as systemic diseases. Early diagnosis and proper management of bilateral disc swelling is important, as it can save vision as well as life. This study is aimed to determine the socio-demographic and clinical profile of patients with bilateral optic disc swelling in a tertiary eye hospital of Bangladesh. **Methods:** This cross sectional study had been conducted over 102 patients with bilateral disc swelling at the Neuro-ophthalmology clinic of National institute of ophthalmology and Hospital, Dhaka between April 2019 and March 2020. Patients were selected purposively based on specific selection criteria. Detail history was taken, ocular examinations like visual acuity, color vision, field of vision, pupillary light reaction, fundus examination were done and relevant investigations included color fundus photograph, visual field analysis, Computed tomography scans and Magnetic Resonance Imaging were performed. All the information's were recorded in a pre-designed data collection sheet. **Results:** The mean age of the patients was 30.2±10.8 years where 37.3% patients were from 18-27 year age group. Females (67.7%) were commonly presented with bilateral disc swelling than male (33.3%). Most of the patients commonly presented with the symptoms like headache (71.6%), dimness of vision (62.8%), nausea & vomiting (42.2%), ocular pain (21.6%) etc. Best corrected visual acuity of the study population was within 0-0.3 log MAR unit in the right eye in 55.9% cases and in the left eye in 59.8% cases. Majority of the patients (Right eye: 60.8%, Left eye: 63.7%) could read all plates while color vision assessment. About 20% patient had RAPD. About 17% patients had field defect in their right eyes whereas about 15% had visual field defect in left eyes. Other than disc swelling, 14 patients had diplopia (13.7%), 12 patients had uveitis (11.8%). Out of 102 patients, 36 patients were clinically diagnosed as IIH (35.3%). Others were diagnosed as ICSOL (24.5%), bilateral optic neuritis (12.7%), VKH (12.7%), grade-IV hypertensive retinopathy (8.8%). The analysis of neuro imaging findings among the patients showed 72 patients (70.6%) had no space occupying lesions, 9 patients (8.8%) had meningioma, 6 patients had CP angle tumor (5.9%), 5 patients had empty sella (4.9%) **Conclusions:** Most of the Bangladeshi patients with bilateral disc swelling report to neuro-ophthalmology clinic in NIO&H are female and belong to 18-37 years age group. Among them headache is the most common presenting complaint and IIH is the most common clinical diagnosis.

Keywords: Bilateral disc swelling, clinical profile, demographic profile, papilloedema.

(*J.Natl.Inst.Ophthalmol.2022;5(1):39-45*)

¹ Assistant Registrar, National Institute of Ophthalmology and Hospital, Dhaka.

² Assistant Professor and Head of Department, Department of Neuro Ophthalmology, National Institute of Ophthalmology and Hospital, Dhaka.

³ Associate Professor, Community Ophthalmology, Deputy Director (Government and Private Medical College), Director General of Medical Education

⁴ Assistant Surgeon, National Institute of Ophthalmology and Hospital, Dhaka.

⁵ Assistant Professor, National Institute of Ophthalmology and Hospital, Dhaka

⁶ Epidemiologist, National Institute of Ophthalmology and Hospital, Dhaka.

Correspondence

Dr. MD. Ershadul Haque Rahat
Assistant Registrar
National Institute of Ophthalmology & Hospital, Dhaka.
Mobile: 01717431795
Email: rahatmsnio@gmail.com

Received: 07 Sept. 2022

Accepted: 15 Dec. 2022

Introduction

The optic disc is the intra-ocular portion of the optic nerve that can be visible with indirect and direct ophthalmoscope. It consists of optic cup and neural rim.¹ The neuro-retinal rim is the orange pink tissue in between the outer edge of the cup and the optic disc margin.² The color of optic disc is derived from peripapillary capillaries and the nerve fiber layer as well as lamina cribrosa. It measures about 1.5 mm in diameter.³ Optic disc swelling is termed differently in different pathological process such as swollen optic disc, disc edema, papilledema, papillitis, choked disc and elevated optic nerve are terms to describe swelling of optic disc.¹ A swollen optic disc implies axonal distension and elevation of the optic disc. Disc edema suggests axonal swelling and increased fluid surrounding the axons.⁴

Papilloedema means disc swelling secondary to the raised intracranial pressure and therefore carries specific etiologic connotations. Papillitis has traditionally been used to denote inflammation of optic disc due to demyelination or infection. Choked disc refers to axoplasmic stasis at the level of the lamina cribrosa, where the scleral canal is too narrow. Disc swelling can occur both unilaterally and bilaterally. Cases with bilateral optic disc swelling are often associated with papilloedema, infiltrative optic neuropathy, malignant hypertension and toxic optic neuropathy.¹

Patients having visual disturbance associated with bilateral disc swelling often encountered with by neuro-ophthalmologist as well as neuro-surgeon or neurologist depending on the severity of presenting signs & symptoms such as headache, vomiting, loss of vision, unconsciousness etc. The important ophthalmological examinations include visual acuity, relative afferent pupillary defect (RAPD), visual field, color vision analysis etc. Blood count, blood sugar level, parameters of acute inflammation (ESR, CRP), ANA, ANCA etc. are some important serological investigations. Neurological examinations especially cranial nerve examination, CSF parameter including various important neuro-radiological examinations are very important in case of optic disc swelling.⁵ Inadequate neuro- ophthalmological evaluation and not considering the important differentials of bilateral disc swelling may cause delay in diagnosis or misdiagnosis. As for example, many intracranial space occupying lesion patients or patients with idiopathic intracranial hypertension (IIH) are often misdiagnosed as a case of headache or migraine and treated accordingly. This can be life threatening, whereas early and precise neuro-ophthalmological evaluation can do early diagnosis and can ensure timely referral of the patient to a concerning neurologist or neurosurgeon.

Different causes of bilateral disc swelling have different demographic and clinical presentation such as age and sex distribution, mode of onset of various ocular symptoms, duration, various important fundus findings, associated neurological and systemic features etc. It is very important to know the clinical features of a disease precisely

for accurate diagnosis, timely referral and prompt management.

Therefore, the present study had been conducted to evaluate the clinical profile and radiological findings of patients with bilateral disc swelling. This study would provide necessary information to develop a general guideline on how to conduct ophthalmological examination in a bilateral optic disc swelling patient. It can also be an important tool for them regarding quick diagnosis, prompt management and timely referring the patients of bilateral disc swelling in those areas of Bangladesh where neuro-ophthalmology clinic and neuro-imaging is not available.

Methodos

This cross sectional study was conducted in the Department of Neuro-ophthalmology, National Institute of Ophthalmology & hospital, Dhaka from April 2019 to March 2020. One hundred and two patients with bilateral disc swelling were selected as study population where bilateral disc swelling due to congenital disc anomaly, pseudo disc edema or need emergency medical care had been purposively excluded from the study. Informed written consent was obtained from the patients or their attendants after full explanation of purpose of the study and the ultimate outcome. The necessary data regarding patient's age, gender, occupation, presenting ocular and systemic complaints, any relevant drug history were collected in a pre-designed data sheet. Full ocular, systemic, neurological and fundus examination and related systemic and neurological evaluation were done.

Optic nerve function mainly evaluated by four commonly used test like BCVA, color vision test, pupillary light reaction and RAPD assessment, examining visual field. Visual acuity was tested by using Snellen visual acuity wall chart and converted into Log MAR unit. Pinhole visual acuity test and subjective refraction was done in case of visually impaired patients. Color vision was tested by Ishihara Pseudo-isochromatic color plates. Pupillary light reaction was examined by penlight torch and RAPD was tested if required by swinging a flashlight from the asymptomatic eye to symptomatic one in a room with dim illumination. The visual field was assessed subjectively by confrontation method. Ocular motor nerve functions were examined by

assessing the ocular motility test. Other cranial nerves were also examined if required. Necessary general examinations like pulse rate, blood pressure, body weight, lymph nodes palpation, thyroid gland palpations etc. were done. Relevant systemic examinations especially neurological evaluation was when required.

Relevant ocular (color fundus photograph, fundus fluorescein angiography, optical coherence tomography, B-scan ocular ultrasound, Humphrey visual field analysis etc.), systemic investigations and neuro-imaging (CT scan, MRI with or without contrast, MRV, MRA) were done to establish the clinical diagnosis.

Statistical analysis of the results was done by using computer based software, SPSS version 25. The research protocol was approved by the Ethical Review Committee of NIO&H. Informed written consent (English/Bengali version) was taken from each patient or their attendance.

Results

The mean age of patients was 30.22 ±10.84 years where 68 patients (67.7%) were female and 34 (33.3%) were male. The main presenting complaints was headache (n=73, 71.6%) followed by dimness of vision (n=62, 62.8%). Nausea/ vomiting were present in 43 (42.2%) patients and ocular pain had 22 (21.6%) patients. Few (4.9%) had transient loss of vision (figure I).

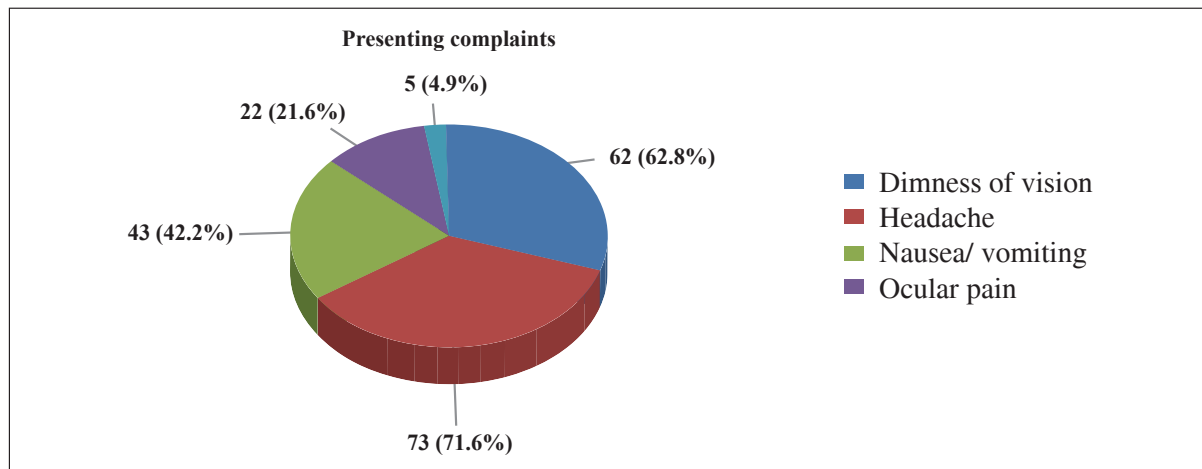


Figure I: Distribution of the patients by presenting complaints(n=102)

Among the patients who had IIH, 30 (83.3%) were female while among the patients who had ICSOL and grade 4 Hypertensive retinopathy, 12 and 5 (48.0% and 55.6% respectively) were male. Among the patients who had bilateral optic neuritis and VKH majority of them (69.2% and 69.2%) were female (figure II).

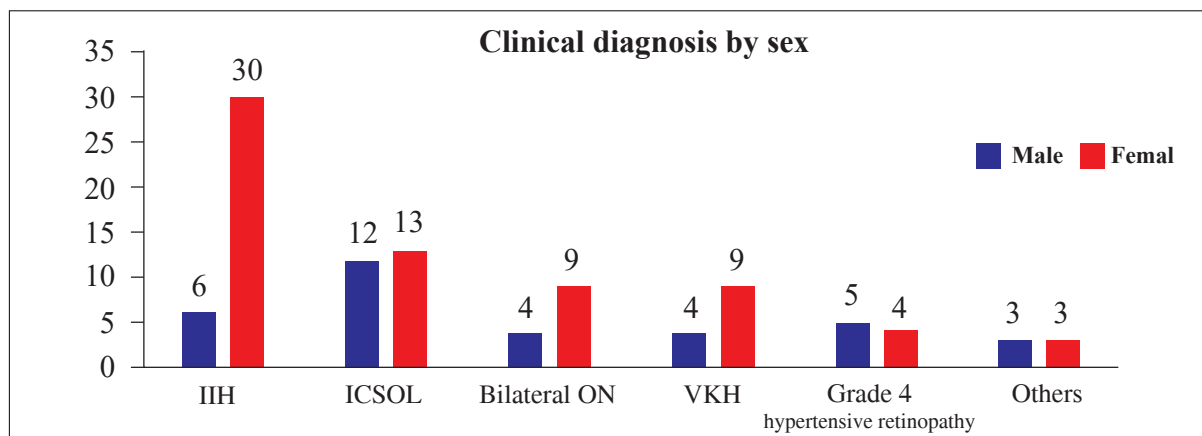


Figure II: Distribution of the patients by clinical diagnosis and sex (n=102)

IIH: Idiopathic Intracranial Hypertension, ICSOL: Intra-Cranial Space Occupying Lesion, ON: Optic Neuritis, VKH: Vogt-Koyanagi-Harada disease

Table I: Clinical findings of the patients(n=102)

Clinical findings	Right f (%)	Left f (%)
Visual acuity (>0.3)	45 (44.1)	41 (40.2)
Sluggish pupillary response	34 (33.3)	34 (33.3)
Non-reacting pupillary response	4 (3.9)	3 (2.9)
Dyschromatopsia	40 (39.2)	37 (36.3)
Only disc swelling	69 (67.6)	65 (63.7)
Disc swelling with other findings (hemorrhage or exudate, detachment)	33 (32.3)	37 (36.3)
Restricted ocular motility	13 (12.7)	14 (13.7)
Relative Afferent Pupillary Defect (RAPD)	13 (12.7)	7 (6.9)
Field defect present	17 (16.7)	15 (14.7)

In right eye, 45 (44.1%) had Visual acuity >0.3 while in left eye, 41 (40.2%) had Visual acuity >0.3. One third had (33.3%) sluggish pupillary response in both eye. Majority of the patients (right: 67.6%, left: 63.7%) had only disc swelling. Restricted ocular motility was present in 13 (12.7%) patients in right eyes and 14 (13.7%) patients in left eyes. In right eye, 17 patients (16.7%) had visual field defect while in left eyes, 15 patients (14.7%) had visual field defect (table I).

Table II: Distribution of the patients by ocular manifestation other than disc swelling(n=102)

Ocular manifestation	Frequency (f)	Percentage (%)
No	75	73.5
Diplopia	14	13.7
Uveitis	12	11.8
Ptosis	1	1.0
Total	102	100.0

Seventy-five patients (73.5%) did not have any ocular manifestation other than optic disc swelling while 14 (13.7%) had diplopia, 12 (11.8%) had uveitis and 1 (1.0%) had ptosis (table II).

Table III: Distribution of the patients by findings of neuroimaging (n=102)

Radiographic finding	Frequency (f)	Percentage (%)
No space occupying lesion	72	70.6
Meningioma	9	8.8
CP angle tumor	6	5.9
Empty sella	5	4.9
Pituitary adenoma	3	2.9
Craniopharyngioma	3	2.9
Others (Glioma, Neurofibroma, Astrocytoma, Metastatic lesion)	4	3.9
Total	102	100.0

CP: Cerebellopontine

Out of 102 patients, 72 patients (70.6%) did not have any space occupying lesion while 9 (8.8%) had meningioma and 6 (5.9%) had Cerebellopontine (CP) angle tumor (table III)

Discussion

Bilateral optic disc edema is a clinical finding that can be caused by benign or permanent visual impairment or life-threatening conditions. The present cross sectional study had been conducted to find out clinical profile of Bangladeshi patients with bilateral optic disc swelling and their causes, reporting in Neuro-ophthalmology unit of NIO&H.

The mean age of the patients was 30.22 ± 10.84 (SD) years where majority of them were from 18-37 years age group and majority of them were female (67.7%). IHH is the major cause (36 patients) of optic disc swelling in this study, which occurs commonly in women of reproductive age. This result was consistent with the hospital based study conducted in India which also reported that the mean age of the patients was near about 30 years⁶ where majority were female⁷.

In this study, the presenting complaints of the patients were headache (71.6%), dimness of vision (62.8%), nausea and/or vomiting (42.2%), transient loss of vision (4.9%). Study done by Solanki et al.⁷ showed that the presenting complain was headache in 70% cases followed by diminution of vision in 50% cases, nausea and vomiting in 48% cases, lateral rectus palsy and diplopia in 4% of cases. Another study done by Rukmangathan et al.⁸ on clinical profile of papilledema showed that 95% patient presented with headache which is followed by transient obscuration of vision, field defects, vomiting, diplopia, neck pain and giddiness. These findings correspond to the present study findings. In all the above mentioned studies raised intracranial pressure was detected as the main cause of disc swelling and headache is the first presenting complain of this condition.

The ocular manifestations other than dimness of vision was diplopia (13.7%), uveitis (11.8%) and drooping of upper eyelid (1.0%). Raised intracranial pressure often leads to 6th nerve palsy resulting in diplopia in the direction of action of that muscle. Patients whose clinical diagnosis was VKH had complaints of floaters, ocular pain, redness, watering that means features of uveitis and cerebral venous thrombosis patients accompanied with features of cranial nerve palsy like drooping of eyelids. Study done by Iijima et al.⁹ showed

that 70% of bilateral uveitis patients of the study population were diagnosed as VKH patients and presented with inflammation of anterior chamber, macular oedema, as well as redness and swelling of optic nerves and serous retinal detachment. This features also correspond to the ocular findings of VKH patients in this study. In this study, the mean best-corrected visual acuity of the study subjects in Log MAR unit was 0.64 ± 0.73 in right eye and 0.69 ± 0.75 in left eye, of them 55.9% had visual acuity ranges from 0-0.3 Log MAR unit in right eye which was 59.8% in left eye. The study of Rukmangathan et al.⁸ found most of the patients had visual acuity within 0-0.3 log MAR unit, which is similar and consistent with this study finding.

According to Selhorst & Chen¹⁰ relative afferent pupillary defect (RAPD) is a sensitive and important test for evaluating optic nerve function. This is the only objective test of optic nerve dysfunction; all other tests are depended upon subjective responses from the patient. In this study, regarding evaluation of pupillary reaction to light reveals that most of the patients (80.4%) had no relative afferent pupillary defect (RAPD). The rest 19.6% patients had RAPD where ICSOL, optic neuritis and VKH were the main clinical diagnosis. Number of patients with RAPD was less, as this study was conducted over patients of bilateral disc swelling.

Out of 102 patients with 102 pairs of eyes, all the color plates were read by 62 right eyes (60.8%) and 65 left eyes (63.7%). Study done by Shah¹¹ on clinical and etiological profile of disc edema shows that 52% of participants had no color vision defect. Which was consistent with this study finding. Theoretically, in early and established stages of disc edema has little effect on visual acuity and color vision. About one fourth of the eyes of the study subjects of this study failed to read all plates, where the main clinical diagnosis was optic neuritis. This feature is consistent with the study of Anuradha et al.¹² on evaluation of the causes of optic disc oedema where they showed that, the patients with optic neuritis, NAION and other causes had color vision defects.

In this study, 7.8% patients give the history of intake of oral contraceptive pill (OCP) which is an associated factor of IHH¹³.

In the current study, the clinical diagnosis was idiopathic intracranial hypertension (IIH) in 35.3% of patients, intracranial space occupying lesion (ICSOL) in 24.5% of patients, 12.7% had bilateral optic neuritis, 12.7% had Vogt-Koyanagi-Harada (VKH) disease and 8.8% had grade- IV hypertensive retinopathy. Others causes were cerebral venous sinus thrombosis (2.94%), diabetic papillopathy and bilateral nonarteritic anterior ischemic optic neuropathy (NAION). So, among the study population, 71.56% patients had bilateral disc swelling due to raised intra cranial pressure. Study conducted by Iijima et al.⁹ found that the most common causes of the bilateral disc swelling was increased intracranial pressure (ICP) (59%) which was consistent with the present study. They also reported that 5% patients had grade 4 hypertensive retinopathy. Another study done by Hata & Miyamoto¹⁴ reported that causes of bilateral disc swelling was papilloedema in near about half of the patients and optic neuritis in 12.5% patients which coincide the present study. In India, Anuradha et al.¹² found that out of 50 patients, 26 cases of the bilateral disc swelling were due to increased intracranial pressure (ICP). However, they did not found any diabetic papillopathy and bilateral nonarteritic anterior ischemic optic neuropathy (NAION) patient. They enrolled 47 patients with bilateral optic disc swelling in their study while the present study had been conducted among 102 patients with bilateral optic disc swelling which might be the cause of variations of clinical diagnosis. In Nepal, Vaidya et al.⁶ found papilloedema was the most frequent cause of disc oedema followed by papillitis, pseudopapilledma and ischemia, respectively.

Most of the patients (30 patients) with Idiopathic intracranial hypertension (IIH) were female (83.3%) in this study. IIH predominantly affects obese women of childbearing age.¹⁵ Female predominance was also observed in case of bilateral optic neuritis and VKH. Nakao et al.¹⁶ evaluated the factors associated with, optic disc swelling in Vogt-Koyanagi-Harada disease (VKH) where they also found female predominance. Optic neuritis universally shows a female preponderance. Three quarters of optic neuritis patients are women.¹⁷

Findings of the neuroimaging showed that majority of the patients (70.65%) were suffering from non-space occupying lesions. However, the study of Solanki et al.⁷ reported that one third of the patients with optic disc edema had non-space occupying lesions. The dissimilarity might be due the fact that their study was conducted in a multidisciplinary hospital and many of their study subjects were referred from the department of neuro-surgery where most of the patients were clinically diagnosed as intracranial space occupying lesion. Among the 102 patients, the most common site of intra cranial space occupying lesion in this study was cerebellopontine angle (5.9%) though meningioma is the most common radiologically diagnosed lesion (8.8%). This finding is consistent with the study conducted by Raju & Khader¹⁸ on ocular manifestations of intracranial space occupying lesions, where cerebellopontine angle was the most common site of intra cranial tumors.

It was mentionable here, the study included patients who attended in the neuro-ophthalmology clinic, those who attended in the other discipline (neurology, neurosurgery) were not included which may change the existing profile.

Conclusion

It may be summarized that the most of the patients with bilateral disc swelling belongs to 18-37 years age group where number of females were more than males among the Bangladeshi patients. Headache was the most common presenting complaint followed by dimness of vision and nausea or vomiting. Raised intra cranial pressure was the most common etiology for bilateral disc swelling where IIH is the main clinical diagnosis. All the important clinical diagnosis was very much consistent with the various findings of ocular, systemic, neurological evaluations and neuro-imaging findings. So, a systemic and methodical neuro-ophthalmological work up is very important in case of patients even with a simple headache. This can ensure early detection and timely referral of various vision or life threatening conditions. Also a similar study can be done involving other disciplines who also deal with bilateral disc swelling patients which can give a better epidemiological outcome.

Conflict of Interest: Nothing to declare.

References

1. Van Stavern GP. Optic disc edema. In: *Seminars in neurology* 2007;27(03):233-43.
2. Bowling B. Glaucoma. In: *Kanski's clinical ophthalmology: a systematic approach*. 8th ed, 2016. Edinburgh: Elsevier Health Sciences. 306-94.
3. Khurana AK, Khurana I. Retina, visual pathway and physiology of vision. In: *Anatomy and physiology of eye*. 2nd edition, 2006. New Delhi: CBS Publishers & Distributors Pvt Limited. 140-270.
4. Digre KB, Corbett JJ. *Practical viewing of the optic disc*. Butterworth-Heinemann; 2003.
5. Stammen J, Unsöld R, Arendt G, Vester EG, Heering P, Freund HJ, Strauer BE, Grabensee B. Etiology and pathogenetic mechanisms of optic disc swelling with visual loss. *Ophthalmologica*. 1999;213(1):40-7.
6. Vaidya K, Bhandari S, Gurung R. Etiologies of optic disc edema in tertiary eye care centre in Nepal. *NEPJOPH*. 2018;10(2):139-42.
7. Solanki D, Meena V, Sharma U, Agrawal S. Optic disc edema/papilledema: a clinical profile. *J. Evol. Med. Dent. Sci*. 2016;5(16):795-801.
8. Rukmangathan K, Chandrasekaran R, Savichandran R. Clinical profile and yield of neuroimaging in papilledema. *IntJ Medical Health Researh*. 2017;10:66-71.
9. Iijima K, Shimizu K, Ichibe Y. A study of the causes of bilateral optic disc swelling in Japanese patients. *ClinOphthalmol(Auckland, NZ)*. 2014;8:1269-74.
10. Selhorst JB, Chen Y. The optic nerve. In: *Seminars in neurology* 2009; 29 (01): 29-35.
11. Shah RK. Clinical and etiological profile of patients with optic disc edema in tertiary care centre of Nepal. *JIOM NEPAL*. 2019;41(1):24-30.
12. Anuradha TR, Venkatesh S, Radhakrishnan B, Raajeseharan T, Aparna R. Evaluation of the causes of optic disc oedema- An observational study. *J. evid. based med*. 2017; 4(87):5082-5.
13. Bowling B. Neuro-ophthalmology. In: *Kanski's clinical ophthalmology: a systematic approach*. 8th ed, 2016. Edinburgh: Elsevier Health Sciences. 774-849.
14. Hata M, Miyamoto K. Causes and prognosis of unilateral and bilateral optic disc swelling. *Neuroophthalmology*. 2017;41(4):187-91.
15. Dhungana S, Sharrack B, Woodroffe N. Idiopathic intracranial hypertension. *Actaneurologicascandinavica*, 2010: 121(2):71-82.
16. Nakao K, Abematsu N, Mizushima Y, Sakamoto T. Optic disc swelling in Vogt-Koyanagi-Harada disease. *Invest Ophthalmol Vis Sci*. 2012;53(4):1917-22.
17. Martin TJ, Corbett J. *Optic nerve disorders*. In: *Practical Neuroophthalmology*. 2013. New York: McGraw Hill Professional. 85-138.
18. Raju KV, Khader AA. Ocular manifestations of intracranial space occupying lesions-A clinical study. *Kerala J Ophthalmol*. 2009;21(3):248-52.