

Orbital lymphatic-venous malformation: A Review on the Management Strategies

Syed Mehbub Ul Kadir¹, Sadia Sultana², Nishat Parveen³, Riffat Rashid⁴,
Rajendra Prakash Maurya⁵, Golam Haider⁶

Abstract

Still, there is no ideal guideline for managing orbital lymphatic-venous malformations. Significant advances have been made in the treatment of lymphatic-venous malformation. Here, we attempt to review the current and recent evidence on management strategies, including sclerotherapy agents, systemic medications, and techniques. The orbital lymphatic-venous malformation is notorious for being very difficult to treat due to risks of morbidity, loss of vision and periocular disfigurement. Management depends on lymphangioma size, cyst type, and location. One option is carefully watching patients without doing any treatment (Observation). The option of surgery has typically been delayed until necessary because of the high recurrence rate, a high risk of morbidity because of injury to the globe, extraocular muscles, vessels, and optic nerve, and it is difficult to remove the entire lesion. Sclerotherapy is famous for reducing the size of orbital lymphangioma. Systemic medication can reduce the size and improve the clinical symptoms where the lesions are difficult to access surgically or with injections. These treatment modalities aim to reduce the size of the lesions, and cosmetic disfigurement and free from pain caused by these lesions, also avoid vision-threatening complications.

(*J.Natl.Inst.Ophthalmol.2022;5(2):45-51*)

<https://doi.org/10.3329/jnio.v5i2.66792>

Introduction

Orbital lymphatic-venous malformation (previously called lymphangioma) is a localized congenital benign anomaly that involves the lymphatic and vascular systems, also known as lymphatic malformations. Lymphangiomas are usually multi-cystic, localized malformations most commonly involving the head and neck region of pediatric patients. These lesions are

usually not present at birth but can become apparent after episodes of trauma or bleeding to the region of the lesion.^{1,2} Lymphangiomas represent around 1% to 4% of all orbital lesions, 4% of all vascular tumours, and approximately 25% of benign pediatric vascular tumours and typically present spontaneously as an orbital haemorrhage in children under the age of 16.^{2,3} Orbital lymphatic-venous malformation has a prevalence of 1.1 to 5.3 per 10,000 live births with an equal distribution in males and females.^{3,4} We attempt to review the articles on lymphatic-venous malformation, and sclerosing agents through google scholar, academia Edu., research gate, and PubMed to summarize the current and recent management strategies for these diseases.

1. Assistant Professor, Sheikh Fazilatunnesa Mujib Eye Hospital and Training Institute, Gopalganj
2. Associate Professor, Ispahani Islamia Eye Hospital and Institute, Dhaka, Bangladesh
3. Associate Professor, National Institute of Ophthalmology and Hospital, Dhaka, Bangladesh
4. Associate Professor, Ispahani Islamia Eye Hospital and Institute, Dhaka, Bangladesh
5. Associate Professor, RIO, IMS, Banaras Hindu University, Varanasi, India
6. Professor, Bangladesh Eye Hospital and Institute, Dhaka

Address of correspondence:

Syed Mehbub Ul Kadir,
Email: mehbubkadir@gmail.com

Received: 21 December 2021

Accepted: 4 April 2022

Published: 18 June 2022

Classification

Lymphangiomas are classified in three ways: a) blood flow type, b) vascular lesion type, and c) cyst size and depth.⁵

The International Orbital Society classified the orbital vascular lesions according to blood flow into three categories:

- Type 1 (No Flow Malformation), e.g., lymphangioma
- Type 2 (Venous Flow Malformation), e.g., Orbital Varices
- Type 3 (Arterial Flow Malformation), e.g., Carotid Cavernous Fistula

Orbital lymphangiomas having minimal flow and little or no connection to the vascular system are classified as type 1 (no flow malformation) lesions.⁶ Lymphangiomas can also be classified based on the type of vascular lesion and the predominant vascular component (venous dominant vs lymphatic dominant).⁷ Along with flow characteristics, orbital lymphangiomas are further classified based on depth and anatomical location:

- superficial (presenting as a subcutaneous/conjunctiva)
- deep (characteristics of orbital infiltration)
- combined (both superficial and deep components)
- Complex (intracranial or head and neck infiltration).^{8,9}

Finally, the classification of orbital lymphangioma can be made based on the cyst size into three categories 1. Microcystic (<2cm), 2. Macrocystic (>2cm cysts), and 3. Mixed (both microcystic and macrocystic).¹⁰

Pathophysiology

Lymphangiomas can occur either congenital or acquired. The congenital pattern is due to an improper connection of lymphatic channels to the central lymphatic duct. Acquired lesions can occur following the interruption of lymphatic drainage due to mechanisms like surgery, trauma, malignancy, or radiation therapy.¹¹

Clinical Presentation

Orbital lymphatic-venous malformations (Orbital lymphangiomas) are benign orbital lesions producing myriad symptoms.

Clinically, most patients present with symptoms in children in the first decade of life; 43% are diagnosed before six and 60% before 16 years of age.⁷ Lymphangiomas with deeper lesions may become asymptomatic until a haemorrhage into the lesion leads to proptosis.^{4,7,8,12} Proptosis and ptosis of the affected eye are the most frequent features of Orbital lymphangioma. Other presenting features include periocular lesion,

dystopia, strabismus, restricted ocular motility, and rarely compressive optic neuropathy if left untreated after an acute haemorrhage into the lesion. Upper respiratory tract infection (URTI) patients may cause a sudden increase in swelling or proptosis of the affected eye.^{2,7-9,13} A study reported 26 patients with orbital lymphangioma; 85% of patients had proptosis, 73% had ptosis, and 46% had restricted ocular motility.¹⁴ Other studies reported on 12 patients; proptosis was the most common presenting feature (56%), followed by lid swelling (44%).¹⁵ Sudden intralesional bleeding after a minor trauma may cause chocolate cysts like lesions, acute painful proptosis and may also risk of optic nerve compression.^{15,16} These symptoms are often not clinically present until an inciting factor causes an increase in the size of the lesion. It is essential to monitor the patient with ptosis and physical disfigurement due to periocular swelling, which can obstruct visual development and enhance amblyopia.²

Diagnostic Procedure

Diagnosis is based on clinical features and radiologic findings. The radiologic study helps in the proper diagnosis of lymphangioma. Radiology imaging allows assessment of the size of the lesion and the extent of involvement of surrounding tissues. CT scan reveals cyst-like lesions with varying degrees of enhancement (Fig. 1) along with cysts' rim enhancement that indicates cysts' haemorrhage. CT scan may show the calcifications within the cystic lesion.^{2,17,18} MRI demonstrates orbital lymphangiomas are often isointense on T1-weighted images and hyperintense on T2-weighted images, generally presenting with internal septa within the lesion. The characteristic findings include multiple cystic lesions with air-fluid levels. As mentioned above, these lesions are described as no-flow [H3] lesions. Therefore, there is typically a lack of flow voids and enlarged feeder vessels.^{2,19} Radiologic imaging study also guides the management of orbital lymphangiomas, such as the intervention of superficial lesion is more accessible than a deeper one. Typically, larger cysts of more than 2 cm are a better sclerotherapy option.¹⁹ Imaging study helps the lesion by assessing the depth, location, and extent.

[H3] lesions. Therefore, there is typically a lack of flow voids and enlarged feeder vessels.^{2,19} Radiologic imaging study also guides the management of orbital lymphangiomas, such as the intervention of superficial lesion is more

accessible than a deeper one. Typically, larger cysts of more than 2 cm are a better sclerotherapy option.¹⁹ Imaging study helps the lesion by assessing the depth, location, and extent.

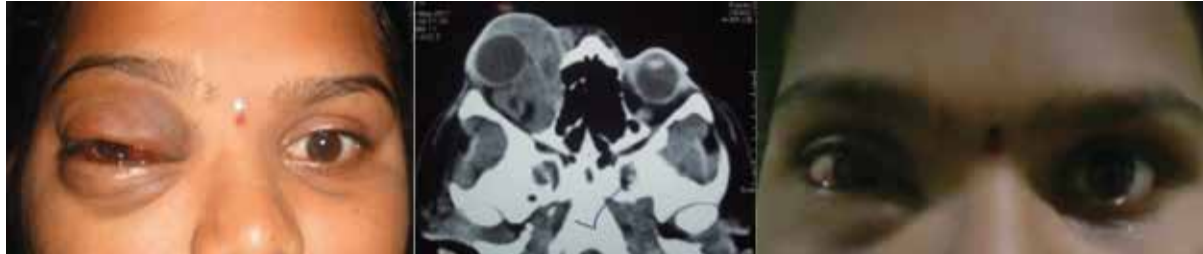


Figure 1 (a-c): a 14-year-old girl presented with painful proptosis, ptosis, and chocolate cyst-like lesions of the conjunctiva. The axial CT image of the orbit shows a heterogenous cystic lesion in the right eyelids extending extraconal to intraconal space of the right orbit with varying degrees of enhancement suggestive of orbital lymphatic-venous malformation. The lesion was reduced after surgical excision with an intraoperative injection of triamcinolone acetonide.

Management

The primary management options fall into four categories: observation, sclerotherapy (intralesional sclerosant injection), systemic medication, and surgery. There is no clear gold standard treatment protocol, and there are risks and benefits to all four treatment options.^{19,20} Early and effective treatment, especially in children, is a crucial step to preserving vision and preventing amblyopia.²

a. Observation is the treatment of choice if the lesion is not causing pain, physically disfiguring, or vision-threatening complications. Observation may be needed for a deep, asymptomatic lesion over a more superficial one, which can potentially be treated with less risk of morbidity to surrounding tissues.^{8,20}

b. sclerotherapy:

Sclerotherapy is a procedure where sclerosing agents are injected into the cystic spaces of the lesion, leading to scar formation and reducing the size of the lesion.²⁰ The first reported attempt for sclerotherapy was attempted by D Zollikofer in Switzerland, 1682, who injected acid into a vein to induce thrombus formation.²¹ Debout and Cassaignac reported success by injecting perchlorate of iron for treating the varicose veins in 1853.²² For orbital lymphangioma, Intralesional injection of sclerosants has been used for the past three decades.²³ Specific sclerosing agents include

OK-432 (Picibanil), sodium tetradecyl sulfate, doxycycline, ethanol, pingyangmycin, and bleomycin are commonly used in the treatment of orbital lymphangioma.²⁴

Sclerotherapy procedure can be performed under ultrasound guidance/image (CT scan) guided by puncturing the cystic cavity, aspirating the fluid, and injecting the sclerosing agent. After aspirating the fluid, a cytological analysis can confirm the diagnosis. Increasing space for the sclerosant is created, and the surface area in contact with the agent increases. Literature reported that sclerotherapy is effective in treating and resolving the macrocystic (size >2 cm) lymphatic malformations, with less effectiveness for microcystic lesions.²⁰ An interventional study resulted on 29 patients with macrocystic orbital lymphangiomas who underwent sodium tetradecyl sulfate injection as sclerotherapy with 21.8 months average follow-up time. The complete imaging resolution was found in 51.7% of patients, and a 50% or more reduction in maximal lesion diameter occurred for all patients, with improved visual acuity in 78.2% of patients.²⁵ Intralesional injection of sodium tetradecyl sulfate under CT scan guidance is effective sclerotherapy for patients with orbital lymphangioma without vision-threatening complications.^{26,27}

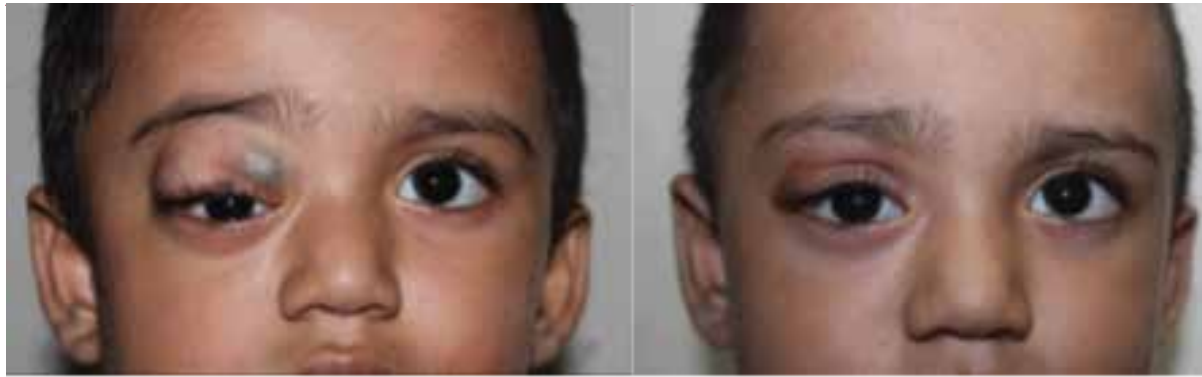

Figure 2 (a-b): a 4-year-old boy presented with mechanical ptosis, lobulated lesions of right antero-superior orbit with bluish discoloration of the right upper eyelid. The lesion was almost disappeared after 3 doses of sclerotherapy.

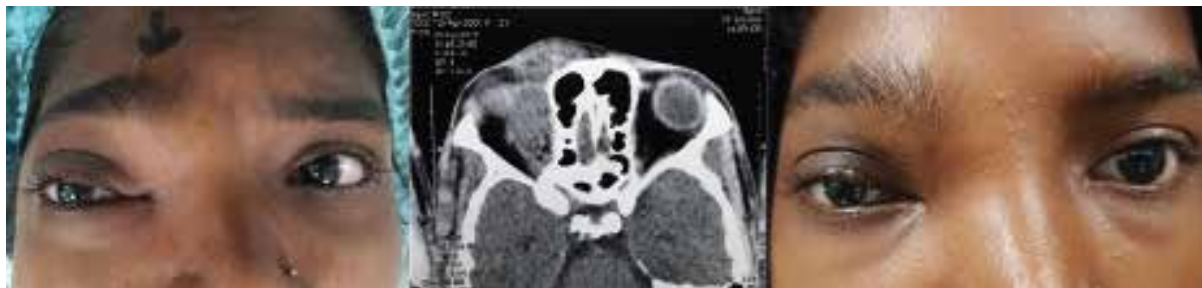

Figure 3 (a-c): a 10-year-old girl presented with right periocular lymphangioma, Axial CT images showing the heterogenous lesion within an internal septation involving the right upper eyelid and extraconal space of the right orbit. Post bleomycin injection resulted satisfactory outcome.

A study reported 13 patients with orbital lymphangiomas who underwent sclerotherapy injection with bleomycin with an average follow-up time of 19.69 months. 92% of patients showed more than 60% reduction in the maximal lesion diameter.² A study reported on 12 patients treated with bleomycin sclerotherapy, 50% showed complete resolution, and the other 50% showed more than 70% without any systemic and ophthalmic side effects.¹⁵ Hill RH et al. described safe and effective treatment modalities with dual drug sclerotherapy intralesional sodium tetradecyl sulphate and ethanol for macrocystic lesions and injection doxycycline for treating microcystic lesions.¹⁰ The efficacy of intralesional injection of OK-432 (Picibanil) was studied on 12 patients with orbital lymphangiomas, 89% of patients presented with regression of tumour size, and 87.5% of patients improved their vision, decreased pain or proptosis in an average of 64 months follow up.²⁸ The OK-432 intralesional injection is effective alternative sclerotherapy that may require one to four injections over a month to 12

months.^{29,30} The sclerotherapy procedure is usually performed under general anaesthesia for children and with topical anaesthesia with sedation for adults. Risks of the sclerotherapy procedure include infection, bleeding, damage to adjacent structures during injection, post-injection reactive inflammation, increasing intraorbital pressure due to the volume of injecting fluid and resulting oedema from inflammation due to inflammation of the sclerosing agents.² Despite of few risks of complication, sclerotherapy is a promising treatment modality for orbital lymphangioma (Fig. 3), which may prevent the need for surgery or minimize the surgical excision.³¹

Bleomycin is the most used and effective sclerosing agent in Bangladesh. Bleomycin is first isolated from the soil fungus *Streptomyces verticillus*. Umezawa first reported that bleomycin could act as an anti-tumour, anti-viral and anti-bacterial agent in 1966. The mechanism of action of bleomycin is to inhibit DNA synthesis; It also has a sclerosing effect on the

vascular endothelium.³² Bleomycin is commercially available as a freeze-dried powder form in vials containing 15 international units (IU) of bleomycin. 1 IU of bleomycin is equivalent to 1 mg of bleomycin.

The recommended dose of bleomycin is 0.25-0.5 mg/kg body weight. Still, the maximum does not exceed 15 mg.^{2,33} Bleomycin solution is reconstituted by adding sterile water/normal saline and 2% lignocaine at the ratio of 1: 1. The presence of lignocaine in the solution reduces discomfort and facilitates the entry of the drug into the cell by making more permeable the cellular membranes. The injected volume, preferably 20% of the aspiration volume from the lesion, is 5:1 but does not exceed 4 ml at one session. A large volume of bleomycin poses the danger of compressive effects and extravasation of the drug. Multiple punctures are often required. Care must take to keep the needle outside the muscle cone, and soon after injection, local pressure is applied to prevent leakage of bleomycin. Pupillary reactions should be monitored for a couple of hours following injection. There is an exact guideline regarding the number of doses of bleomycin injections while treating orbital lymphangiomas. 2 to 6 doses are required, according to the reported article, depending on satisfactory outcomes.^{2,15}

A cure rate of 86.5% without any recurrence in 2 years of follow-up was reported with head and neck lymphangiomas of 200 patients treated with intralesional bleomycin injection.³⁴ Treated 16 patients with orbital lymphangiomas with intralesional bleomycin injection. It resulted in a volume reduction from 50% to 80% in all cases with no recurrence in the six weeks to 6 months of follow-up.³⁵ Bleomycin is a safe and effective sclerosing agent for lymphatic-venous malformation (Fig. 3).³⁵⁻³⁸

Common side effects include pain, erythema, swelling and occasionally fever, local skin necrosis, and eschar formation may also occur at the site of injection.^{37,38}

c. Systemic medication: Systemic sildenafil and Systemic sirolimus are used to treat the lymphatic malformations that result from the positive response in both orbital and nonorbital lymphatic lesions. Sildenafil is a phosphodiesterase 5 (PDE-5) inhibitor, which raises the levels of cyclic guanosine monophosphate in smooth muscles, causing a vasodilation effect.²⁴ A low dose of oral sildenafil citrate (1 mg/kg/day and increased up to 3 mg/kg/day) with more prolonged use (seven months) has been reported to be a safe and effective approach to decreasing the volume of macrocystic or mixed lymphatic malformations in children.^{24,39} Systemic Sirolimus targets rapamycin (mTOR), which prevents cell growth and proliferation by blocking the integration of signals from the PI3K/AKT pathway. The blocking of this pathway leads to a reduction of vascular endothelial growth factor production, along with a reduction of cytokine IL-2 and angiogenesis. The recommended dose is 0.8 mg/ml, with optimal trough levels reducing within 10-15 ng/ml. Trough levels should be taken every 5-7 days after starting the treatment. Sirolimus is highly responsive to arterio-venous malformations, and venous-lymphatic malformation.⁷ systemic medication has revolutionized the medical management of lymphatic-venous malformations. Future treatment modality involves targeting lymphangiogenic pathways, which aids in the inhibition of vascular endothelial growth factors and the phosphatidylinositol 4,5-bisphosphate 3-kinase catalytic subunit.⁴⁰

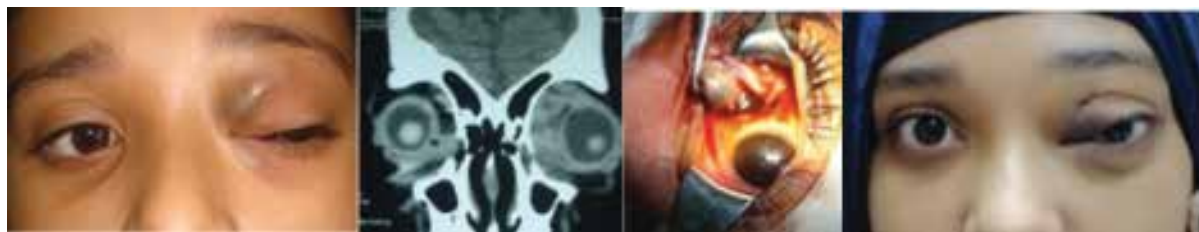


Figure 4 (a-d): A 9-year-old-girl showing swelling in the superomedial quadrant of the left orbit with bluish discoloration of eyelid skin. Coronal CT image of the orbit showing a moderate enhancement of cystic lesion infiltrating the medial rectus muscle. Intraoperative image showing the lesion infiltrated with extraocular muscles. Postoperative photograph after six months of surgical debulking of the lesion.

cd. Surgery: Surgical excision and debulking (Fig. 4) is the mainstay of treatment but crucial due to their proximity to vital structures like the globe, optic nerve, and extraocular muscles.^{8,13} Surgical excision is always challenging due to the unencapsulated and infiltrative nature of orbital lymphangiomas paired with accompanied vascular tufts.⁸ The lesion can surround vital structures of the orbit, increasing the risks of harm to these vital structures while excision of the lesion completely. There is a risk of high recurrence due to incomplete excision and scarring and damage to adjacent structures may be happened.¹⁹ Reported recurrence rate is 71% over an average of 7 years.⁴¹ To help with hemostasis and handling the lesion and structures, surgical excision or debulking is usually accompanied by or follows initial sclerotherapy or injection of fibrin glue. Fibrin glue is injected into the lesion, which causes the lesion to become solidified, allowing the surgeon to mobilize and excise the lesion. Complete surgical excision or exenteration may be a reasonable surgical option for a deep orbital lymphangioma lesion in a blind eye and severely painful eye.⁸ Our observation is that injection triamcinolone acetonide is used as an intraoperative sclerosing agent, preventing the

risk of recurrence, especially after incomplete excision or debulking. A few techniques with good surgical debulking or removal outcomes have been documented. The surgical approaches to the orbit depend on the location of the lymphatic-venous malformation (lymphangioma).

Conclusion

The management of Orbital lymphatic-venous malformation (lymphangioma) depends on the lesion's size, depth, and location. The surgery remains the mainstay of treatment though the more profound and complex lesion is difficult to excise entirely because of the diffuse and infiltrative nature of the lesion. Sclerotherapy is using isolated or in combination with surgery with variable outcomes. The development of new sclerosing agents and systemic medication allows multimodality treatment to achieve more successful outcomes.

Competing interests

The authors declare no competing interests regarding the publication of this article

Source of Funding

There was no financial support in terms of grants or funds for this study from any source.

References

1. Forrester MB, Merz RD: Descriptive epidemiology of cystic hygroma: Hawaii, 1986 to 1999. *South Med J* 97:631-6, 2004
2. Raichura ND, Alam MS, Noronha VO, Mukherjee B. A prospective study of the role of intralesional bleomycin in Interventions for orbital lymphangioma (Protocol) 6 Copyright © 2018 The Cochrane Collaboration. Published by John Wiley & Sons, Ltd. orbital lymphangioma. *Journal of AAPOS* 2017;21(2): 146–51.
3. Grasso DL, Pelizzo G, Zocconi E, et al: Lymphangiomas of the head and neck in children. *Acta Otorhinolaryngol Ital* 28:17-20, 2008
4. Lally SE. Update on orbital lymphatic malformations. *Current Opinion in Ophthalmology* 2016;27(5):413–5.
5. Nassiri N, Rootman J, Rootman DB, Goldberg RA. Orbital lymphaticovenous malformations: current and future treatments. *Survey of Ophthalmology* 2015;60(5):383–405.
6. Harris GJ. Orbital vascular malformations: a consensus statement on terminology and its clinical implications. *Orbital Society. American Journal of Ophthalmology* 1999; 127(4):453–5.
7. Adams DM, Trenor CC 3rd, Hammill AM, Vinks AA, Patel MN, Chaudry G, et al. Efficacy and safety of sirolimus in the treatment of complicated vascular anomalies. *Pediatrics* 2016;137(2):e20153257.
8. Saha K, Leatherbarrow B: Orbital lymphangiomas: a review of management strategies. *Curr Opin Ophthalmol.* 2012;23 (5):433-8.
9. Bailey ST, Wojno TH, Shields CL, Grossniklaus HE. Late-onset presentation of orbital lymphangioma. *Ophthalmic Plastic and Reconstructive Surgery.* 2007; 23(2):100-3.
10. Hill RH, 3rd, Shiels WE, 2nd, Foster JA, et al: Percutaneous drainage and ablation as first line therapy for macrocystic and microcystic orbital lymphatic malformations. *Ophthalmic Plast Reconstr Surg* 28:119-25, 2012
11. Miceli A, Stewart KM: Lymphangioma, StatPearls. Treasure Island (FL), 2019
12. Jafari N, Jafari R. Orbital Lymphangioma: A Case Report and Review of Management Modalities. *J. Pediatr. Rev.* 2021; 9 (4) :321-328

13. Kalisa P, Van Zielegheem B, Roux P, Meire F. Orbital lymphangioma: clinical features and management. *Bulletin de la Societe Belge d'Ophthalmologie* 2001, (282):59–68.
14. Tunc M, Sadri E, Char DH: Orbital lymphangioma: an analysis of 26 patients. *Br J Ophthalmol* 83:76-80, 1999
15. Nuruddin M, Roy S, R, Singh Mudhar H: Results of Intralesional Bleomycin Sclerotherapy for Treatment of Orbital Lymphangiomas at a Tertiary Eye Care Centre in Bangladesh. *Ocul Oncol Pathol* 2019;5:412-417.
16. Graeb DA, Rootman J, Robertson WD, Lapointe JS, Nugent RA, Hay EJ. Orbital lymphangiomas: clinical, radiologic, and pathologic characteristics. *Radiology*. 1990 May;175(2):417–21.
17. Bilaniuk LT. Vascular lesions of the orbit in children. *Neuroimaging Clinics of North America*. 2005; 15(1):107-20.
18. Pahwa Sh, Sharma S, Das CJ, Dhamija E, Agrawal S. Intraorbital cystic lesions: An imaging spectrum. *Current Problems in Diagnostic Radiology*. 2015; 44(5):437-48.
19. Patel SR, Rosenberg JB, Barmettler A. Interventions for orbital lymphangioma. *Cochrane Database Syst Rev*. 2019 May 15;5(5):CD013000.
20. Bagrodia N, Defnet AM, Kandel JJ. Management of lymphatic malformations in children. *Current Opinion in Pediatrics* 2015;27(3):356–63.
21. Goldman, M., *Sclerotherapy Treatment of varicose and telangiectatic leg vein*, Hardcover Text, 2nd Ed, 1995
22. Sharmi S, Cheatle T. *Fegan's Compression Sclerotherapy of Varicose Veins*, Hardcover Text, 2003.
23. Bloom DC, Perkins JA, Manning SC: Management of lymphatic malformations. *Curr Opin Otolaryngol Head Neck Surg* 12:500-4, 2004
24. Gandhi NG, Lin LK, O'Hara M. Sildenafil for pediatric orbital lymphangioma. *JAMA Ophthalmology* 2013;131(9): 1228–30.
25. Barnacle AM, Theodorou M, Maling SJ, et al: Sclerotherapy treatment of orbital lymphatic malformations: a large single-centre experience. *Br J Ophthalmol* 100:204-8, 2016
26. Poonyathalang A, Preechawat P, Jiarakongmun P, Pongpech S. Sclerosing therapy for orbital lymphangioma using sodium tetradecyl sulfate. *Jpn J Ophthalmol*. 2008 Jul-Aug;52(4):298-304.
27. Wojno TH. Sotradecol (sodium tetradecyl sulfate) injection of orbital lymphangioma. *Ophthalmic Plast Reconstr Surg*. 1999 Nov;15(6):432-7.
28. Chaudhry IA, Fahad Al-Saikhan F, Al-Sheikh O, Al-Rashed W, Shamsi FA, Arat YO; Boniuk M. Intralesional OK-432 (Picibanil) Sclerosing Agent in the Treatment of Orbital Lymphangiomas. *Investigative Ophthalmology & Visual Science* April 2014, Vol.55, 4081.
29. Yoon JS, Choi JB, Kim SJ, Lee SY. Intralesional injection of OK-432 for vision-threatening orbital lymphangioma. *Graefes Arch Clin Exp Ophthalmol*. 2007; 245:1031-5.
30. Lagrèze W, Metzger M, Rössler J. Sclerotization of orbital lymphangioma with OK-432. *Ophthalmologie*. 2014;111(5):479-81.
31. Patel KC, Kalantzis G, El-Hindy N, Chang BY. Sclerotherapy for orbital lymphangioma-case series and literature review. *In Vivo* 2017;31(2):263–6.
32. Umezawa H. Recent study on biochemistry and action of Bleomycin. In: Carter SK, Crook ST, Umezawa H, editors. *Bleomycin: Current Status and New Developments*. New York (NY): Academic Press; 1978. pp. 15–20.
33. Rozman Z, Thambidorai RR, Zaleha AM, Zakaria Z, Zulfiqar MA. Lymphangioma: is intralesional bleomycin sclerotherapy effective? *Biomed Imaging Interv J*. 2011 Jul-Sep; 7(3):e18
34. Zhong PQ, Zhi FX, Li R, Xue JL, Shu GY. Long-term results of intratumorous bleomycin-A5 injection for head and neck lymphangioma. *Oral Surg Oral Med Oral Pathol Oral Radiol Endod*. 1998 Aug;86(2):139–44. 22
35. Paramasivam S, Fay A, Fifi J, Berenstein A. O-015 image guided bleomycin sclerotherapy for orbital lymphatic malformation. *J Neuro Intervent Surg*. 2014;6 Suppl 1:A8–9
36. Bothra N, Panda L, Sheth J, Tripathy D. Role of intralesional bleomycin sclerotherapy as the sole or adjunct treatment of superficial ocular adnexal lymphatic malformations. *Eye (Lond)*. 2018;32(1):152-155.
37. Kumar V, Kumar P, Pandey A, Gupta DK, Shukla RC, Sharma SP, et al. Intralesional bleomycin in lymphangioma: an effective and safe non-operative modality of treatment. *J Cutan Aesthet Surg*. 2012 Apr;5(2):133–6.
38. Mathur NN, Rana I, Bothra R, Dhawan R, Kathuria G, Pradhan T. Bleomycin sclerotherapy in congenital lymphatic and vascular malformations of head and neck. *Int J Pediatr Otorhinolaryngol*. 2005 Jan;69(1):75–80.
39. Wang S, Zhang J, Ge W, Liu Y, Guo Y, Liu Y, et al. Efficacy and safety of oral sildenafil in treatment of pediatric head and neck lymphatic malformations. *Acta Oto-Laryngologica* 2017;137(6):674-8.
40. Lam SC, Yuen HKL. Medical and sclerosing agents in the treatment of orbital lymphatic malformations: what's new? *Curr Opin Ophthalmol*. 2019 Sep;30(5):380-385.
41. Russin JJ, Rangel-Castilla L, Kalani MY, Spetzler RF. Surgical management, outcomes, and recurrence rate of orbital lymphangiomas. *Journal of Clinical Neuroscience* 2015;22(5):877–82.