

## Association of Serum IgE with Keratoconus

Mohammad Hussain Raihan<sup>1</sup>, Md Kamrul Hasan Khan<sup>2</sup>, Natasha Kajmina<sup>3</sup>, Md Mahbubur Rahman<sup>4</sup>,  
Md. Shoeb-Ur-Rashid<sup>5</sup>, Tarzeen khadiza Shuchi<sup>6</sup>

### Abstract

**Purpose:** Keratoconus is an ectatic corneal disease characterized by regional thinning and protrusion that leads to irregular astigmatism and, ultimately, substantial vision impairment. The aim of this study was to see if there was a link between serum IgE levels and keratoconus. **Methods:** At the Combined Military Hospital Dhaka, a prospective observational study was conducted in the general Eye OPD and Cornea clinic. The study involved 60 participants who were divided into 2 groups. Thirty people with keratoconus were assigned to Group A, while 30 healthy people were assigned to Group B. All 60 patients had their serum IgE levels checked. **Results:** The mean age of the study subjects in Group A and group B were 19.60±5.28 (SD), and 20.23±5.62 (SD) respectively; 13 were male and 17 were female in Group-A, and 10 were male and 20 were female in Group-B. Serum IgE was 243.183±143.059 (SD) in group-A and 86.067±77.065 (SD) in group-B. There was a significant rise in serum IgE in Group-A (p value <0.0001). **Conclusion:** Elevated serum IgE levels are strongly associated with keratoconus. Measuring serum IgE could be an important parameter in the management of Keratoconus.

**Key words:** Keratoconus, Allergy, Serum IgE

(*J.Natl.Inst.Ophthalmol.2022;5(2):21-24*)

<https://doi.org/10.3329/jnio.v5i2.66793>

### Introduction

Keratoconus is the commonest ectatic corneal disease. Thinning and forward protrusion are common symptoms. As the cornea takes on a conical shape, irregular astigmatism develops. Within 16 years, around 50 % of people with normal fellow eyes will develop keratoconus. In

almost all cases, both eyes are affected at some point, at least on topographic imaging.<sup>1</sup> In certain circumstances, advanced keratoconus can result in a considerable loss of vision due to progressive ectasia and even a corneal scar.<sup>2,3,4</sup> Keratoconus is a condition that can progress or spontaneously stabilize.<sup>5</sup> In its early stage, keratoconus can be managed with spectacles or hard contact lenses. Corneal collagen cross linking with or without an intracorneal ring segment is used to treat progressive instances. Keratoplasty is needed to restore vision in advanced keratoconus. As a result, detecting this condition early and treating it with known risk factors may increase the chances of the disease stabilizing without causing further damage. Ocular allergies, atopy, and eye rubbing are all important factors in keratoconus pathogenesis.<sup>6,7</sup> IgE (Immunoglobulin E) is a key driver for allergic response, with reference to the pathogenesis and management of keratoconus.<sup>8</sup> IgE is a crucial modulator of the major risk factors (allergy, atopy, and eye rubbing) linked with keratoconus. The signs and symptoms of allergy and atopy, including ocular manifestations, are well known to be predominantly driven by an IgE-mediated

1. Classified Eye Specialist and Cornea Fellow, Combined Military Hospital, Dhaka.
2. Advisor Eye Specialist, Combined Military Hospital, Dhaka.
3. Classified Eye Specialist, Combined Military Hospital, Dhaka.
4. Classified Eye Specialist, BMC to Kuwait.
5. Junior Consultant, Surgery, UHC, Mirpur, Kushtia, Bangladesh.
6. Assistant Professor, National Institute of Ophthalmology & Hospital, Dhaka.

### Address of correspondence:

Dr. Mohammad Hussain Raihan,  
Cornea and Refractive Surgeon,  
CMH, Dhaka.  
E-mail: mhraihaan2003@yahoo.com.  
Cell No: 01711275797

Received: 24 December 2021

Accepted: 15 April 2022

Published: 18 June 2022

cellular response.<sup>9,10,11</sup> The objective of this study was to find out association between serum IgE and keratoconus.

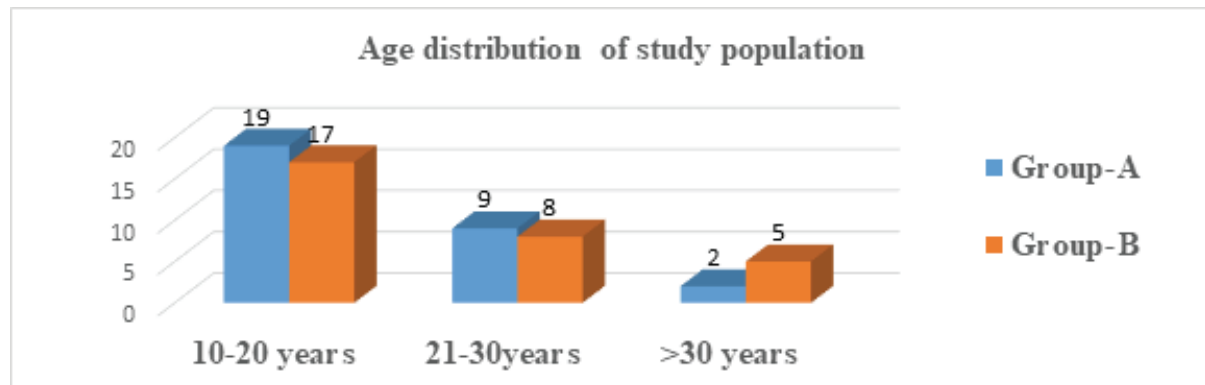
## Material and methods

This observational study was conducted at General Ophthalmology OPD and Cornea OPD, CMH, Dhaka from July 2021 to December 2021. Patients with keratoconus and an age-matched normal population were taken as study populations irrespective of gender. Age ranged from 10 to 40 years. Patients with history of ocular trauma were excluded from the study. Serum IgE levels were measured at the Armed Forces Institute of Pathology (AFIP). A total of 60 cases were included in the study. They were divided into two groups. Group-A contains 30 keratoconus patients and Group-B contains an age-matched normal population. Informed written consent was taken from each patient. A

detailed history was taken. A clinical examination was performed and properly recorded. The data were analyzed with SPSS 26 version. The categorical data were presented as frequency (%) and the continuous data as mean (SD). The two groups were compared by Chi-square test for categorical variables and Student t test for continuous variables. A p-value less than 0.05 was considered statistically significant in two tailed test. This protocol was approved by the Ethical Review Committee of Combined Military Hospital, Dhaka.

## Results

The average age of Group-A was  $19.60 \pm 5.28$  (SD) and Group-B was  $20.63 \pm 5.62$  (SD). In Group-A, 19 (63.3%) of them were aged between 10-20 years. In Group-B, the 17 (56.7%) of people were between the ages of 10 and 20 (figure 1).



**Figure-1:** Age distribution of study population (n=60)

There were 13 (43.3%) males and 17 (56.7%) females in Group A, and 10 (33.3%) males and 20 (66.7%) females in Group B ( $p=0.426$ ) (table 1).

**Table 1:** Sex distribution of study population (n=60)

Sex	Group A	Group B	p value
Male	13 (43.3%)	10 (33.3%)	0.426*
Female	17 (56.7%)	20 (66.7%)	

The average serum IgE was  $243.183 \pm 143.059$  (SD) in Group-A and  $86.067 \pm 77.065$  (SD) in Group-B respectively which was statistically significant ( $P$  value  $<0.001$ ) (table 2).

**Table 2:** Serum IgE level of study population (n=60)

Serum IgE level	Group A	Group B	p value
Raised	25 (83.3%)	7 (23.3%)	<0.001*
Normal	5 (16.7%)	23 (76.7%)	
Mean $\pm$ SD	243.183 $\pm$ 143.059	86.067 $\pm$ 77.065	<0.001**

SD=Standard deviation, \*Chi-square test, \*\* Student t test

## Discussion

Keratoconus is a progressive, non-inflammatory condition marked by corneal thinning and protrusion, progressive myopia, and irregular astigmatism. It damages the structural integrity of collagen material within the corneal stroma, resulting in corneal thinning and bulging over time.<sup>12</sup> Keratoconus, which causes alterations in the collagen and keratocytes in the ectatic region, could be linked to a local (ocular surface) manifestation of an IgE-based systemic immunological imbalance typical in allergies or atopy.<sup>13,14,15</sup> Several degranulating mast cells and inflammation of inflammatory cells can be seen in conjunctival biopsies from ocular allergy patients.<sup>16</sup> Because mast cell activation leads to the synthesis of cytokines, which aid immune-cell trafficking and the release of protein inflammatory mediators.<sup>17-19</sup> The eye rubbing in response to itchy eyes has been suggested as an important link between Keratoconus and IgE.<sup>20</sup>

In our study, we discovered that the mean serum IgE in Group-A (Keratoconus Patients) and Group B (Normal Population) were 243.183 $\pm$ 143.059 and 86.067 $\pm$ 77.065 respectively ( $p < 0.001$ ). So, this study found a strong association between elevated serum IgE and Keratoconus. We also found that, 83% of keratoconus patients had elevated serum IgE. On the other hand, only 23% of the normal

population group had elevated serum IgE. Peyman et al.<sup>21</sup> performed a clinical trial and found that 92.7% keratoconus patients exhibit a history of allergic disorders that is more serum IgE. Millodot et al.<sup>22</sup> also found that Keratoconus patient exhibit more atopy and elevated IgE (OR 3.0, 95% CI 1.2-7.6). Weed et al.<sup>23</sup> in their study concluded that atopic conditions and elevated IgE were found in 77% of keratoconus patients. There were potential limitations to our approach. The study was conducted in a short period of time, with small sample size and limited resources and facilities. It was conducted in a selected hospital, So the study population might not represent the whole community. A multi-centered study with large sample size would have given a better result.

## Conclusion

This study concludes that there is a strong association between elevated serum IgE and keratoconus. So, measuring serum IgE could be an important parameter in the management of keratoconus.

**Conflict of Interest:** Nothing to declare.

## References

1. Salmon, J., 2019. Kanski's Clinical Ophthalmology: A Systematic Approach. 9th edition. Philadelphia: Elsevier Health Sciences, p.248.
2. Rabinowity YS. Keratoconus. Surv ophthalmol 1998;42:297-313.
3. Naderan M, Rajabi MT, Zarrinbaksh P, et al. Effect of allergic diseases on keratoconus severity. Ocul Immunol Inflamm 2017;25:418-423.
4. Krachmer JH, Feder RS, Belin MW. Keratoconus and

- related noninflammatory corneal thinning disorders. *Surv Ophthalmol* 1984;28:293-322.
5. Romero-Jimenez M, Santodomingo-Rubido J, Wolffsohn JS. Keratoconus: A review. *Ophthalmol* 2010;33:157-166.
  6. Shetty R, Sureka S, Kusumgar P, et al. Allergen specific exposure associated with high Immunoglobulin E and eye rubbing predisposes to progression of Keratoconus. *Indian J Ophthalmol* 2017;65:399-402.
  7. Rahi A, Davies P, Ruben M, et al. Keratoconus and co-existing atopic disease. *Br J Ophthalmol* 1977;61:761.
  8. Prema A, Zeldi D, Rohit S, et al. Relevance of IgE, allergy and eye rubbing in the pathogenesis and management of keratoconus. *Indian J Ophthalmol* 2020;68:2067-74.
  9. Leonardi A, Bogacka E, Fauguert JL, et al. Ocular allergy: Recognizing and diagnosing hypersensitivity disorders of the ocular surface. *Ophthalmol* 2012;67:1327-37.
  10. Stone KD, Prussian C, Metcalfe DD. IgE, mast cells, Basophils and eosinophils. *J Allergy Clin Immunol* 2010;125:73-80.
  11. Leonardi A, Motterca L, Bortolotti M. Allergy and the eye. *Clin Exp Immunol* 2008;153:17-21.
  12. Zakia S, Shamima M, Ahmed R, et al. Changes of topographic status after corneal collagen crosslinking in keratoconus. *J Natl. Inst. Ophthalmol.* 2020;3(1): 29-34.
  13. Leonardi A, Motterca L, Bontolotti M. Allergy and the eye. *Clin Exp Immunol* 2008;153 (suppl 1):17-21.
  14. Untersmayr E, Bises G, Starkl P, et al. The high affinity IgE receptor Fc epsilon RI is expressed by human intestinal epithelial cells. *PLOS one*, 2010;5:9023.
  15. Liu F, Xu L, Chen N, et al. Neuronal Fc epsilon receptor 1 contributes to antigen evoked pruritus. *Brain Behav Immun* 2017;61:165-75.
  16. Easty DL, Birkenshaw M, Merrett T, et al. Immunological investigations in vernal eye diseases. *Trans Ophthalmol Soc UK* 1980;100:98-107.
  17. Wakamatsu TH, Satake Y, Igarashi A, et al. IgE and ECP as markers of severity in the diagnosis of atopic keratoconjunctivitis. *Br J Ophthalmol* 2012;96:581.
  18. Grazino FM, Stahl JL, Cook EB, et al. Conjunctival mast cells in ocular allergic disease. *Allergy Asthma Proc* 2001;22:121.
  19. Elieh Ali Komi D, Rambasek T, Bielory L. Clinical implication of mast cells involvement in allergic conjunctivitis. *Allergy* 2018;73:528-39.
  20. Balasubramanian SA, Pyc DC, Willcox MD. Effects of eye rubbing on the levels of protease, protease activity and cytokines in tears: Relevance in keratoconus. *Clin Exp Optom* 2013;96 :214-18.
  21. Peyman A, Kamali A, Khusabi M, et al. Collagen crosslinking effect on progressive keratoconus in patients younger than 18 years of age : A clinical trial. *Adv Biomed Res* 2019;4:245.
  22. Millodot M, Shneor E, Albou S, et al. Prevalence and associated factors of keratoconus in Jerusalem: A cross sectional study. *Ophthalmic Epidemiol* 2011;18:91-7.
  23. Weed KH, Makewen CJ, Giles T, et al. The Dundee University Scottish Keratoconus Study: Demographics, corneal signs, associated disease and eye rubbing. *Eye (Lond)* 2008;22:534-41.