

Clinical Image

Fatal Intra-Abdominal Hemorrhage in a Middle Aged Lady with Severe COVID-19

Mohammad Mahfuzul Hoque¹, Ponkaj Kanti Datta¹

Abstract

Contrast enhance CT scan of Abdomen showing a large encysted collection at the left of the abdomen extending from lumbar region to left iliac region pushing the surrounding viscera forward. Collection was due to retro-peritoneal hemorrhage in a Middle aged Lady with COVID-19 who was on therapeutic dose of anticoagulation with Low Molecular Weight Heparin.

Key word: Anticoagulation, Bleeding and COVID-19



DOI: <https://doi.org/10.3329/jom.v22i1.51401>

Copyright: © 2021 Haque MM. This is an open access article published under the Creative Commons Attribution-NonCommercial-NoDerivatives 4.0 International License, which permits use, distribution and reproduction in any medium, provided the original work is properly cited, is not changed in any way and it is not used for commercial purposes.

Received: 18 December, 2020;

Accepted: 28 December, 2020

A 48 – year – old lady presented to emergency department with history of fever, loss of appetite, bodyache, cough for 8 days and dyspnea for 2 days. She was non-diabetic and normotensive and was not on any regular medication. Her oxygen saturation was found 82 percent in room air, pulse was 124 beats/minutes, BP was 110/70 mm of Hg and

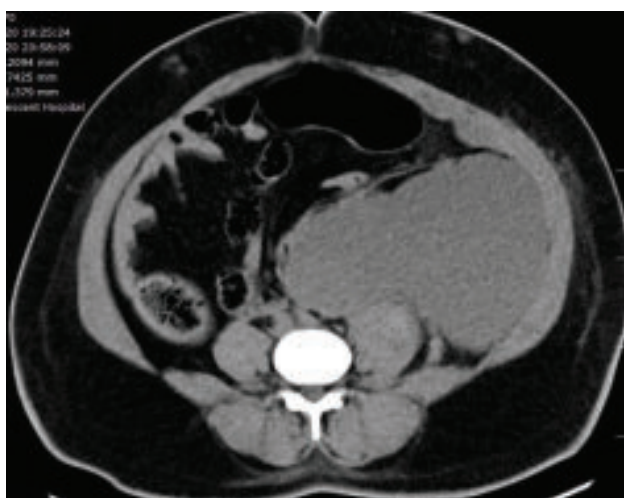


Figure 1 : Axial view

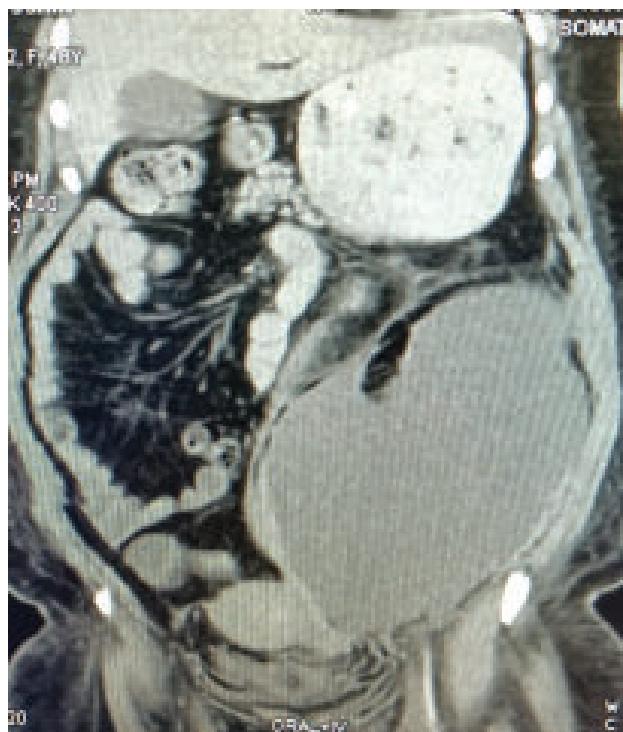

Figure 2 : Coronal view

Figure 1 and 2: Contrast CT scan of Abdomen showing large collection involving left side of abdomen from left lumbar region to iliac region.

1. Assistant Professor of Medicine, Dhaka Medical College, Dhaka

Corresponding author: Mohammad Mahfuzul Hoque, Department of Medicine, Dhaka Medical College. Email: mahfuzdmc55@gmail.com
Mobile: 01922803474

respiratory rate was 32 breaths / minutes. A chest CT scan was done which showed bilateral ground glass appearance with crazy paving appearance consistent with COVID-19 pneumonia and she was immediately hospitalized in dedicated covid unit of the hospital. She was given high flow oxygen with face mask, prophylactic dose of low molecular weight heparin, remdesivir, antibiotic and intravenous dexamethasone 7.5 mg daily. Her condition deteriorated and she could not maintain saturation with 15 liter of oxygen with non-rebreathing mask. She was shifted to intensive care unit and put on High Flow Nasal Cannula with 50 liter of oxygen with FIO₂ 60%. Gradually condition of lady improved and did not require High Flow Nasal Cannula and shifted to ward with 6 Liter of oxygen with face mask. During ICU stay she was started with Enoxaparin 1 mg/Kg body weight which was being continued. Her oxygen requirement was decreasing with improving inflammatory markers. While patient was on 2 liter oxygen with nasal cannula, she was found hypotensive (BP-90/70 mm of Hg) and tachycardic. She had diffuse abdominal pain, did not moved her bowel for last 6 days and mild abdominal distension was found but her bowel sound was present. Intravenous fluid challenge was given which failed to raise the blood pressure of the patient. Her hemoglobin was 6 gm/dl and CT scan of Abdomen (Figure) showed hemorrhagic collection. She developed anuria. Along with crystalloid fluid resuscitation, blood transfusion was started and during third unit of blood transfusion she developed cardiac arrest from which the patient could not be rescued.

Incidence of thrombotic events in patients with COVID-19 depends on severity of disease and is very high in critically ill patients.¹ Venous thromboembolism being the most common form can occur in 27% of ICU patients.³

Anticoagulant therapy has been found to be associated with reduction of mortality in patients with severe COVID-19³ and considered as standard of care in acute ill and severe patients in absence of contraindication.⁴ Double edged sword effect of anticoagulation has to be carefully adjusted with condition of patients because hemorrhagic events also can occur in 21% of critically ill patient specially who are on anticoagulation in therapeutic dose.⁵

References

1. Helms J, Tacquard C, Severac F, Leonard-Lorant I, Ohana M, Delabranche X, et al. High risk of thrombosis in patients with severe SARS-CoV-2 infection: a multicenter prospective cohort study. *Intensive Care Med* [Internet]. 2020;46(6):1089–98. Available from: <https://doi.org/10.1007/s00134-020-06062-x>
2. Klok FA, Kruip MJHA, van der Meer NJM, Arbous MS, Gommers DAMPJ, Kant KM, et al. Incidence of thrombotic complications in critically ill ICU patients with COVID-19. *Thromb Res* [Internet]. 2020;191(April):145–7. Available from: <https://doi.org/10.1016/j.thromres.2020.04.013>
3. Tang N, Bai H, Chen X, Gong J, Li D, Sun Z. Anticoagulant treatment is associated with decreased mortality in severe coronavirus disease 2019 patients with coagulopathy. *J Thromb Haemost*. 2020;18(5):1094–9.
4. Moores LK, Tritschler T, Brosnahan S, Carrier M, Collen JF, Doerschug K, et al. Prevention, Diagnosis, and Treatment of VTE in Patients With Coronavirus Disease 2019: CHEST Guideline and Expert Panel Report. *Chest* [Internet]. 2020;158(3):1143–63. Available from: <https://doi.org/10.1016/j.chest.2020.05.559>
5. Fraissé M, Logre E, Pajot O, Mentec H, Plantefève G, Contou D. Thrombotic and hemorrhagic events in critically ill COVID-19 patients: A French monocenter retrospective study. *Crit Care*. 2020;24:1–4.