

## Short Reports

# Coronary Angioplasty : Case Report of the First Regular Percutaneous Coronary Intervention in a Newly Established Cathlab with Experiences

ABDUL WADUD CHOWDHURY,<sup>1</sup> AEM MAZHARUL ISLAM,<sup>2</sup> H I LUTFUR RAHMAN KHAN,<sup>3</sup> MA SALAM,<sup>1</sup> MAHIBUR RAHIM,<sup>1</sup> M SHOMSER ALI,<sup>2</sup> SERAJUL HAQUE,<sup>2</sup> MONORANJAN KHAN,<sup>4</sup> SSM IQBAL HUDA<sup>5</sup>

### Abstract:

Since its introduction in 1977, Percutaneous Coronary Intervention (PCI) i.e. coronary angioplasty and/or stenting have gained increasing importance in the treatment of coronary artery disease. PCI has reduced the need for coronary artery bypass graft (CABG) surgery and are performed more and more frequently worldwide including Bangladesh. Though Dhaka Medical College Hospital (DMCH) is the pioneer institute for medical education in this country, the facilities for PCI and other cardiac intervention were previously not available in this institute. Recently, however, PCI has been introduced in DMCH. We are here reporting the first regular successful case of PCI done in DMCH.

**Keyword:** Coronary angioplasty, Dhaka Medical College Hospital, Newly established

### Case History:

A 42 years old hypertensive, non-diabetic, chain smoker patient suffered an acute anterior MI on 6<sup>th</sup> December 2008. He was thrombolysed with streptokinase and discharged from the hospital a week later in stable condition. The patient, however, subsequently developed effort angina (CCS class III) despite taking medicines regularly. He was fire service personnel by profession and he could not discharge his duties properly because of the angina. He was readmitted to

DMCH for coronary angiogram (CAG) which was done on 10<sup>th</sup> February, 2009. CAG showed that the patient had double vessel disease with critical stenosis (80 %) in mid LAD (left anterior descending artery) and in proximal part of the PDA (posterior descending artery).

PDA was, however, a small vessel. Mr. Asaduzzaman was, therefore, advised for PTCA (Percutaneous coronary angioplasty) to LAD only. On 15<sup>th</sup> of March, 2009 he

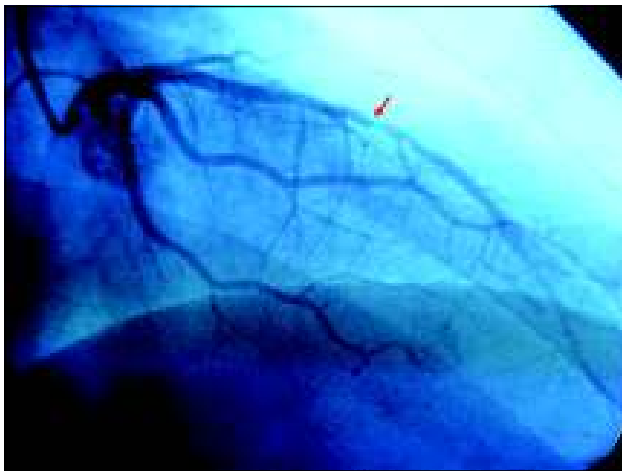


Fig.-1

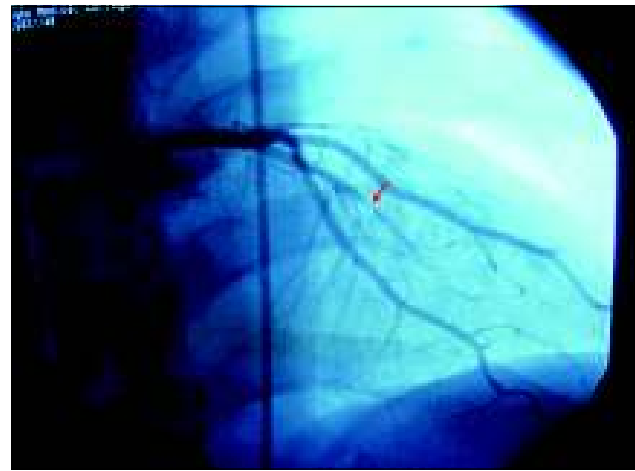

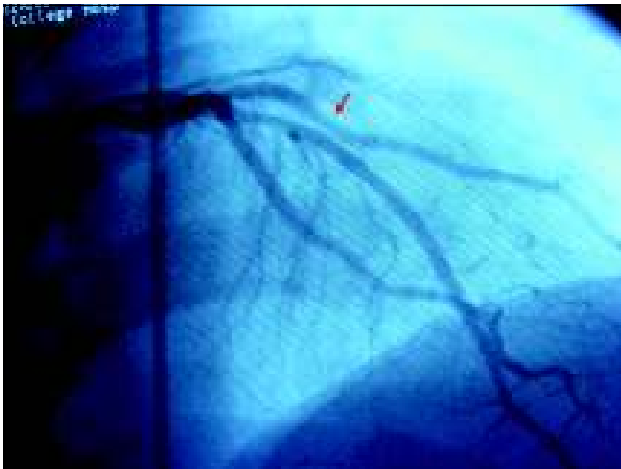Fig.-2

1. Associate Professor of Cardiology, Dhaka Medical College.
2. Assistant Professor of Cardiology, Dhaka Medical College.
3. Professor of Cardiology, Dhaka Medical College.
4. Registrar, Cardiology, Dhaka Medical College.
5. Assistant Registrar, Department of Cardiology, Dhaka Medical College Hospital.

**Correspondence:** Dr. Abdul Wadud Chowdhury, Associate Professor of Cardiology, Dhaka Medical College, E mail: drwadud@hotmail.com

underwent successful angioplasty with stenting to LAD. Left main coronary artery was engaged with Judkin's left guide catheter (3.5, 6F size). Initial angiographic views showed the lesion in LAD had already transformed from 80% stenosis to sub-total occlusion.

So an ACS 0.014"X190 cm intermediate PTCA guide wire was chosen for crossing the lesion. With a 1.5x15 mm balloon support (Sprinter balloon, Medtronic, USA) the lesion was crossed and the tip of the guide wire was parked in distal LAD. The lesion was inflated by the PTCA balloon at 12 to 18 atmospheric pressure by multiple inflations. The LAD lesion was thus opened up. However, it was a long lesion with considerable residual stenosis. Hence 2 stents were used to cover the whole lesion. Distally a 2.5x25mm Flyer stent (bare metal, Atrium, USA) was deployed; proximally a 2.5x19mm Flyer stent was deployed overlapping with the previous stent. The overlapped junction was inflated at higher pressure for good apposition. The result was a gratifying TIMI III flow to distal vessel with no residual stenosis and no dissection.



**Fig.-3**

Patient was heparinised with low molecular weight heparin Enoxaparin at a dose of 1 mg/kg body weight intravenously at the beginning of the procedure. During the procedure intra-coronary GTN (nitrate) at a dose of 100-200 microgram was used repeatedly to prevent vasospasm. After the procedure patient was kept in CCU (coronary care unit) for 24 hours. The vascular access sheaths were removed after 4 hours. Patient was kept on oral nitrate, diltiazem, dual anti platelets (both aspirin and clopidogrel), and statin (atorvastatin 40 mg per day). Injection Enoxaparin was continued at a dose of 60 mg B.D. subcutaneously for 3 days to prevent sub-acute stent thrombosis. Patient was discharged on the 4<sup>th</sup> day. At follow up 7 days later, patient

was quite asymptomatic, haemodynamically stable and happy.

#### **Discussion:**

Since Dr Andreas Gruentzig did the first coronary angioplasty in 1977, coronary care reached a new level.<sup>1</sup> Coronary stenting have emerged as the predominant form of PCI and are currently used in more than 90% of PCI procedure world wide.<sup>2</sup> The procedure was initially limited to fewer than 10% of patients with symptomatic CAD who had single, focal, non calcified lesion of proximal coronary artery disease. With evolving equipment design and operator experience, the use of PCI expanded to include an increasing spectrum of coronary anatomy including multivessel disease, total occlusion, diseased saphanous venous graft and patients with acute ST segment elevation myocardial infarction (STEMI) among other complexities.<sup>3,4</sup> In Bangladesh, percutaneous coronary intervention (i.e. coronary angioplasty and/or stenting) started its journey in 1997 in NICVD(National Institute of Cardiovascular Diseases) by Prof Sufia Rahman and her team.<sup>5</sup> Since the early years of this decade PCI has been widely accepted in this country and cardiologists who had mostly been trained at NICVD are practicing this technical art in many public and private institutions. However, Dhaka Medical College being the pioneer medical institute of this country had been unfortunately lacking the facilities for this important procedure. Since 2007 the angiographic cath lab in DMCH started functioning. On the official opening day of the cath lab eminent interventional cardiologist Professor Emeritus Sufia Rahman did a PCI as a test case on 10th January, 2007. But since then only diagnostic procedures like coronary, peripheral and cerebral angiograms (DSA) were being done here regularly. At the beginning of this year we started to make arrangements for doing not only the diagnostic but also the therapeutic part i.e. coronary intervention. Accordingly we planned and executed this cherished procedure at Dhaka Medical College Hospital (DMCH) on 15th march, 2009. In institutions like DMCH, PCI in type A and type B coronary lesions can be easily done, provided requisite expertise and hardware are available. In our case the lesion was type C (long lesion, sub total occlusion). But we did the procedure smoothly without any hemodynamic or technical compromise.

#### **Conclusion:**

PCI is an important treatment modality for cardiac patients. Considering the importance of the procedure we hereby are proudly reporting the first regular case of Percutaneous coronary intervention (PCI) done in Dhaka Medical College Hospital.

**Conflict of Interest :** None

**References:**

1. Gruntzig A. Transluminal dilatation of coronary artery stenosis. *Lancet*. 1978; 1-263.
2. Jeffar JP, Donald SB, Frederic SR. Percutaneous coronary and valvular intervention. In : Petter L, Robert OB, Douglas MN, Douglas ZP, Braunwald E. editors: *Braunwalds Heart disease A text book of cardiovascular medicine*. Saunders. 2008:1419-1456.
3. Holmes D, Selzer F, Johnston J et al. Modeling and risk prediction in the current era of interventional cardiology: A report from the National Heart, Lung and Blood institute Dynamic Registry. *Circulation*. 2003,107(14) :1871-6.2003
4. Keeley EC, Boura JA, Grines CL,. Primary angioplasty versus intravenous thrombolytic therapy for acute myocardial infarction: A quantitative review of 23 randomized trials. *Lancet*, 2003,361(9351): 13-20
5. First successful intracoronary stent implantation at NICVD by Bangladeshi team- A case report. *Bangladesh J Medicine* 1997: 8 : 77-78