

Picture Quiz

Sudden Unilateral Blindness in a Healthy Man

SUMAIYA SULTANA BINTE MOSHARRAF¹, MAHMUDUR RAHMAN SIDDIQUI², MD SHAHRIAR MAHBUB²

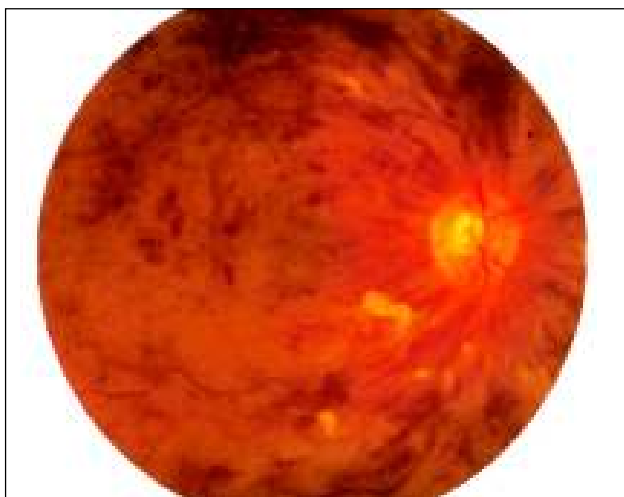

Fig-1: Fundus photography of the right eye,

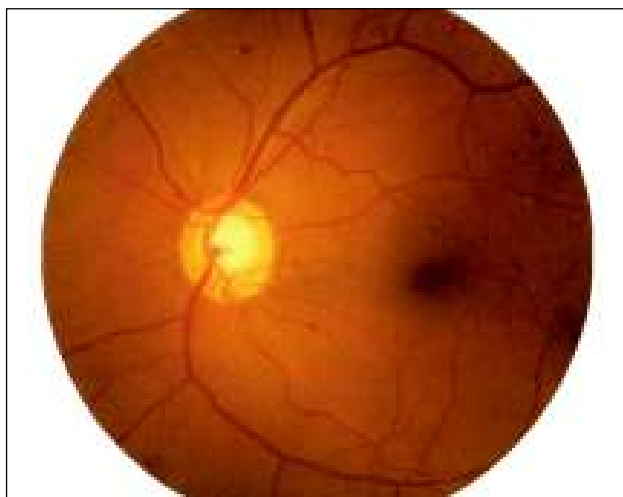


Fig-2: Fundus photography of the left eye,

Clinical Presentation

A 40-year-old previously healthy man presented with sudden dimness of vision in his right eye without any pain or redness. Clinical examination revealed visual acuity 6/36 and normal anterior segment of right eye. But fundoscopic examination of right eye revealed (Fig 1,2). Left eye was normal.

Questions:

1. What are the findings in the pictorial?
2. What is the diagnosis?

Answer

See page 117 for answer.

-
1. Assistant Registrar, Department of Ophthalmology, Armed Forces Medical College, Dhaka.
 2. Consultant, Medicine, The Medical Center
 3. Dr. Sumaiya Sultana Binte Mosharraf, Assistant Registrar, Department of Ophthalmology, Armed Forces Medical College, Dhaka.

Correspondence : Dr. Sumaiya Sultana Binte Mosharraf, Assistant Registrar, Department of Ophthalmology, Armed Forces Medical College, Dhaka, E-mail: dr.mahmud99@yahoo.com