

CASE REPORTS

CHYLOUS ASCITES - A PRESENTATION OF GASTRIC LYMPHOMA

MD. SHAFIQUUL BARI¹, RUBINA YASMIN², KFM AYAZ³, AFSANA BEGUM⁴, NC RAJIB⁵
MA RASHID⁶, HAM NAZMUL AHASAN⁷, FM SIDDIQUI⁷

Summary: A 47-year-old male was admitted with gradually developing ascites. Paracentesis revealed chylous fluid. Histoathology following endoscopic biopsy from the stomach was suggestive of diffuse Non-Hodgkin lymphoma, intermediate grade.

Case Report:

A 47-year-old Bangladeshi male was admitted in a medicine unit of Dhaka Medical College Hospital with the complaints of abdominal discomfort for one year, loose mucoid stool associated with anorexia, nausea, vomiting and weight loss for four months and gradual swelling of abdomen for one month. For these complaints he was investigated and was treated with Anti TB drugs on trial basis prior to hospitalization without any significant improvement. He gave no history of fever, cough, jaundice, haematemesis or melaena. Patient was mildly anaemic and examination of abdomen revealed ascites. There was no lymphadenopathy or hepatosplenomegaly.

On investigation, the ESR was 105 mm in the first hour, Hb 11.4 gm/dl, serum albumin: 3.59gm/dl, ALT:19U/L, prothrombin time: patient -12 sec and control - 12 sec, Montoux test: 8 mm after 72 hrs, chest X-ray P/A view: Normal, and USG of whole abdomen revealed moderate ascites. Paracentesis was done and color of the ascitic fluid was yellowish white with glucose:80mg/dl, protein:7.5gm/dl, TG:344mg/dl, and cell count 2000/cmm of which lymphocyte was 90%. No bacteria was seen on gram stain nor any AFB was found, there was also no malignant cell. ICT for filaria was negative. Rectum and colon was visualized through colonoscopy and was found to be normal. Endoscopy showed nodular swelling and thickening of gastric folds in the

proximal and mid body along the greater curvature with irregularity and discrete shallow ulcers in the rest of the mucosa in these areas. Biopsy was obtained and the histopathology report revealed dense accumulations of small lymphocytes in the lamina propria extending into the submucosa, findings were suggestive of diffuse non Hodgkin lymphoma, intermediate grade. H. pylori IgG was negative.

The patient was given high protein and low fat diet and was administered chemotherapy. He received 4th cycle of chemotherapy prior to writing this report and is due for his 5th cycle. His condition improved and the ascites disappeared.




Fig - 1: Chylous ascetic fluid

1. Clinical Pathologist attached to Medicine Unit - White, Dhaka Medical College Hospital.
2. Junior Consultant, Department of Medicine, Shahid Suhrawardi Hospital.
3. MD 2nd part course student, Dhaka Medical College, Dhaka
4. Medicine Specialist, United Hospital.
5. Junior Consultant, Upazilla Health Complex, Sonargoan, Narayanganj
6. Assistant Professor, Department of Anatomy, Bangladesh Medical College.
7. Professor, Department of Medicine, Dhaka Medical College.

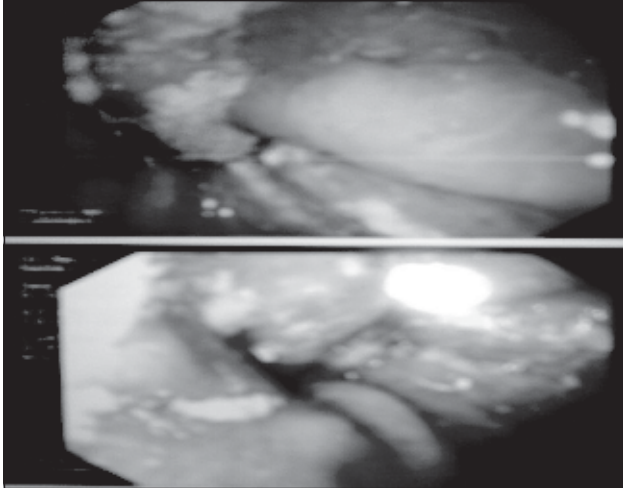


Fig - 2: Endoscopy showed nodular swelling and thickening of gastric folds in the proximal and mid body along the greater curvature with irregularity and discrete shallow ulcers in the rest of the mucosa in these areas

Discussion:

Chylous ascites is a rare clinical condition. The extravasations of the milky chyle into the peritoneum de novo or into a preexisting ascites leads to formation of chylous ascites. This condition is diagnosed when the content of the triglyceride in the ascitic fluid is >200 mg/dl.¹ There is a wide range of causes leading to such a condition. De novo formation is mostly due to trauma. Abdominal surgery usually of the retro peritoneum² and liver transplantation³ are common causes in the developed world. While abdominal tuberculosis^{4, 5, 6} and filariasis^{5, 6} are the leading causes of chylous ascites in the developing countries. CMV infection⁷ has also been reported in one case report. Up to 0.5%-1% patient suffering from cirrhosis of liver may present with chylous ascites.^{8, 9} Malignant neoplasms such as small bowel lymphoma¹⁰, retroperitoneal lymphoma, hepatoma and bowel angiosarcoma has also been reported. In fact in the past this was one of the major causes as reported by Kelly and butt of the Mayo clinic where they found 62 of 71 reported cases were secondary to malignancy.¹¹ The pathophysiology in such cases is mostly obstruction of the lymphatic channels. Other than these, constrictive pericarditis¹², Pancreatitis¹³, spontaneous bacterial peritonitis, pelvic irradiation¹⁴, peritoneal dialysis, carcinoid syndrome and congenital defects of lacteal formation have all been linked to the etiology of chylous ascites.

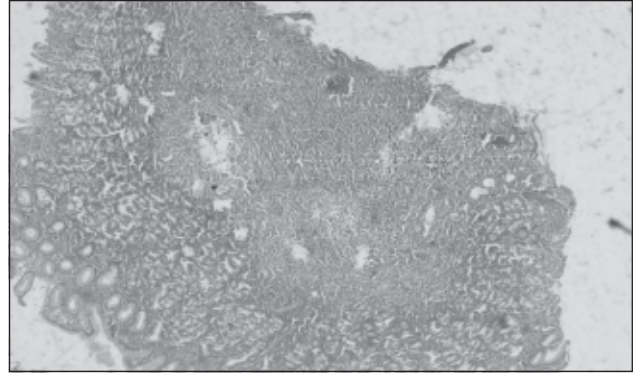


Fig - 3: Histopathology revealed dense accumulations of small lymphocytes in the lamina propria extending into the submucosa

The symptoms and signs are usually similar to those of ascites and in majority of cases, the diagnosis is not suspected till paracentesis. A prospective study found 45 malignant ascites patients (10%) out of 448 patients having ascites and 6.7% of them had chylous ascites which was diagnosed on the basis of milky white colour, triglyceride content and cytology.¹⁵ The common dilemma is to differentiate between chyle and pus, the later usually having a high acute inflammatory cell count and a high serum to ascitic fluid albumin gradient. Abdominal USG and CT may help in identifying lymph nodes and other mass. Peritoneal biopsy is required to confirm the diagnosis of tuberculosis.¹⁶

The prognosis in case of lymphoma with chylous ascites could not be known. The treatment modality is that of lymphoma itself. Only a few studies have mentioned the management of this sort of ascites per se.¹⁷ Nutritional status in this case required special attention as mentioned in various studies. High protein and low fat diet with medium chain triglyceride (MCT) is the first choice for the improvement of ascites and if this fails then TPN along with fasting remains the option out, as fasting reduces intestinal lymph flow.^{18, 19}

Conclusion:

In Bangladesh when ever we get a patient of ascites, the first diagnosis that strikes our mind is cirrhosis. Following paracentesis, if the fluid is chylous, filariasis is what we think of. After exclusion of filariasis, we should also keep in mind lymphoma when chylous ascites is found in a patient with no apparent diagnostic clue.

References:

1. Bachmeyer C, Henni MA, Blanc AS et al. Chylous ascites revealing a non-Hodgkin's lymphoma (French version). *Press Med* 2004; 33:167-69.
2. Ablan CJ, Littooy FN, and Freeark RJ. Post operative chylous ascites: diagnosis and treatment, a series report and literature review. *Arch Surg* 1990; 125:270-73.
3. Asfar S, Lowndes r, Wall WJ. chylous ascites after liver transplantation. *Transplantation* 1994; 58:368-69.
4. Arsuru EL, Ismail Y, civrnakaralian J, Johnson RH. Chylous ascites associated with tuberculosis in a patient with AIDS. *Clin Infect Dis* 1994; 973.
5. Aalami OO, Allen DB, Organ CH Jr. Chylous ascites: a collective review. *Surgery* 2000; 128:761-78.
6. Keaveny AP, Karasik MS, farber HW. Successful treatment of chylous ascites secondary to *Mycobacterium avium* complex in a patient with the acquired immune deficiency syndrome. *Am J Gastroenterology* 1999; 94:1689-90.
7. Greydanus DE, Smith TF, Stickler GB. Acute encephalopathy with liver dysfunction, chylous ascites and cytomegalovirus infection. *Infection* 1977; 5:255-58.
8. Romero S, Martin C, Hernandez L, Verdu J, Trigo C, Perez-Mateo M et al. Chylothorax in cirrhosis of the liver - Analysis of its frequency and clinical characteristics. *Chest* 1998; 114:154-59.
9. Rosser BG, Poterucha JJ, mcKusick MA, Kamath PS. Thoracic duct cutaneous fistula in a patient with cirrhosis of the liver: Successful treatment with a Tran jugular intrahepatic Porto systemic shunt. *Mayo clin Proc* 1996; 71:793-96.
10. Browse NL, Wilson NM, Russo F, Al Hassan H, Allen DR. Aetiology and treatment of chylous ascites. *Br. J Surg* 1992; 79:1145-50
11. Kelley ML Jr, Butt HR. Chylous ascites: an analysis of its etiology. *Gastroenterology* 1960; 39:161-70.
12. Savage MP, Munoz SJ, Herman WM, Kusiak VM. Chylous ascites caused by constrictive pericarditis. *Am J Gastroenterology* 1987; 82:1088-90.
13. Ben ami H, Nagachandran P, Assalia A, Edoute Y. Acute transient chylous ascites associated with acute billiary pancreatitis. *Am J Med Sci* 1999; 318:122-23.
14. Reisinger SA, Asbutry R, Liao SY et al. A phase 2 study of weekly cisplatin and whole abdominal radiation for the treatment of stage 0 and 21 endometrial carcinoma: a gynecologic oncology group pilot study. *gynaecol Oncol* 1996; 63:299-303.
15. Runyon BA, Hoefs JC, Morgan TR. ascitic fluid analysis in malignancy - related ascites. *Hepatology* 1988; 8:1104-9.
16. Martinez-Vazquer JM, Ocana I, Ribera E et al. Adenosine deaminase activity in the diagnosis of tuberculosis peritonitis. *Gut* 1986; 27:1049-53.
17. Leibovitch I, Mor Y, Golomb J et al. The diagnosis and management of postoperative chylous ascites. *J Urol* 2002; 167:449-57.
18. Huang Q, Jiang ZW, Jiang J et al. Chylous ascites: treated with total parenteral nutrition and somatostatin. *World J Gastroenterology* 2004; 10:2588-91.
19. Cardenas A, Chopra S. Chylous ascites. *Am J Gastroenterol* 2002; 97:1896-1900.