

# COMPARISON BETWEEN SWENSON AND SOAVE-BOLEY PROCEDURE IN THE MANAGEMENT OF HIRSCHSPRUNG'S DISEASE

ASM LOKMAN HOSSAIN CHOWDHURY<sup>1</sup>, MD. SHAHID KARIM<sup>2</sup>, MOMOTAJ BEGUM<sup>3</sup>, MD. KABIRUL ISLAM<sup>4</sup>, MD. SHAH ALAM TALUKDER<sup>5</sup>, MD. TOUFIQUE EHSAN<sup>6</sup>

## Abstract :

**Objective:** *The purpose of study was to compare Swenson & Soave-Boley procedure in the staged operative treatment of Hirschsprung's Disease (HD).*

**Methods:** *During 16 months of study period, 25 patients of histopathologically confirmed HD were selected for staged operative treatment, following certain inclusion & exclusion criteria & were admitted & operated at DSH; after completion of all stages operation they were followed up & studied under two groups : staged Swenson procedure (Group-A; n<sub>a</sub>=13) & staged Soave-Boley procedure (Group-B, n<sub>b</sub>=12).*

*They were similar for age, sex, body weight, reselected length of aganglionic segment & postoperative follow up. The level of ganglionosis was assessed from marking biopsy. Preoperative & postoperative observations of Swenson procedure were analyzed & compared with those of Soave-Boley procedure in the staged operative treatment of HD statistically (unpaired 't' test &  $\chi^2$  test)*

**Results:** *For group A (Swenson procedure) the operative time was significantly lesser (unpaired 't' test : <P0.01) than for the group B (Soave-Boley procedure). First bowel movement after colostomy closure was also significantly lesser in duration in Swenson procedure ( $\chi^2$  test :P<0.05).*

## Introduction :

Hirschsprung's Disease (HD) is a development disorder of the enteric nervous system (ENS) characterized by absence of ganglion cells in the myenteric & submucosal plexuses along a variable portion of the distal intestine.<sup>1</sup> The rectum is always involved & in 90% patients the disease extends upto rectosigmoid region.<sup>2</sup>

The most widely accepted etiopathogenic hypothesis is based on a defect of craniocaudal migration of Neuroblasts originating from the neural crest.<sup>1</sup>

Three most common operations for the definitive treatment of HD are the Swenson, Duhamel & the Soave procedure.<sup>3</sup> Although each has been modified following its original description, three procedure

continue to be used as the standard operations for the definitive treatment of this disease.<sup>4</sup>

Swenson first introduced the abdomino-perineal resection with pull through for HD in 1948. The risk of damage to the sacral nerves responsible for fecal & urinary continence as well as sexual function with the Swenson operation stimulated the development of the other pull through procedure.<sup>4</sup>

Soave introduced the endorectal pull through for HD in 1963 as an ERPT procedure without a distal anastomosis. The operation was modified by Boley in 1964 to include a primary anastomosis at the anus. The main advantages of the ERPT are relatively easy to perform & minimal chance of damage to the sacral nerves which control fecal & continence as the dissection is done entirely within the rectal cuff.<sup>4</sup>

- 
1. Assistant Professor, Department of Pediatric Surgery, Dhaka Medical College, Dhaka, Bangladesh.
  2. Professor, Department of Pediatric Surgery & Pediatric Urology, Bangladesh Institute of Child Health, Dhaka Shishu Hospital, Dhaka, Bangladesh.
  3. Assistant Professor, Department of Physiology, Dhaka Medical College, Dhaka.
  4. Professor & Head of the Department of Paediatric Surgery, Dhaka Medical College Hospital, Bangladesh.
  5. Associate Professor, Department of Paediatric Surgery, Dhaka Medical College & Hospital, Bangladesh.
  6. Assistant Professor, Department of Paediatric Surgery, Holy Family Red Crescent Medical College Hospital, Dhaka Bangladesh.

**Materials & Methods:**

This is a prospective study conducted on the children admitted & subsequently operated for Hirschsprung's disease in the department of Surgery of Dhaka Shishu (Children) Hospital (DSH). During the study period of 16 months, (December/2002 to June/2004), total 25 operated patients with HD with transverse colostomy were selected for evaluation. Total operated patients of HD were grouped under 2 categories. Group A (n<sub>a</sub>=13) patients underwent Swenson pull through operation as a part of staged procedure. Group B (n<sub>b</sub>=12) patients underwent Soave-Boley procedure of pull through operation as part of staged procedure.

The surgical resident on duty first took the history & examined the patients and recorded the findings in the history sheet. Documents of the previous operation regarding diagnostic & marking biopsies were checked. Later on the patients were evaluated by the researcher & senior doctors like registrar, the resident surgeon or the consultants. Data from the questionnaire or documents were collected in data sheet under two different groups clinically patients were evaluated by physical & systemic examination.

Under general anaesthesia, rectal examination was done to ensure that no residual stool was present. Nasogastric tube & Foley catheter were introduced into the stomach & bladder respectively. The entire field from the umbilicus to the feet was prepared with povidone-iodine solution. Stockinetes were placed on the leg. The draping was complicated around the perineum with fixation of the sheets to the buttocks. The child was placed in a supine position. The abdomen was draped. The Swenson or Soave-Boley procedure then was done.

The child was allowed to feed as soon as bowel movement returned; till then intravenous fluids support was continued antibiotics were continued for 7 days. Foley catheter was removed on 3<sup>rd</sup> postoperative day. Catheter tip was sent for culture & sensitivity. Postoperative complications such as fever & cough was noted & treated accordingly. Anastigmatic stenosis was diagnosed when little finger of the investigator could not negotiate the anastomotic

area & age appropriate Hager's dilator could not negotiated.

A gentle rectal examination was performed at 15<sup>th</sup> postoperative day if the colorectal anastomosis was adequate. We advised anastomotic dilation by metallic anal dilator twice daily by the mother / father at home till colostomy closure after adequate demonstration to the parents as per Pena scheduled.

After the first post pull through follow up visit the patients were advised to attend the follow up 2 weeks interval till the colostomy closure.

Data for colostomy closure was scheduled within 6 to 8 weeks for the definitive operation, if the anastomotic lumen was adequate. After closing the colostomy the patients were advised to attend the follow up at 2 weeks internal for 3 months.

**Observations & Results:**

Among the total number of patients 9 (69.23%) were male & 4(30.77%) were female in group A, 11(91.67%) male & 1(8.34%) female in group B. Age of the patients ranges from 9 month to 72 months in Group A, 8 months to 36 months in Group B. Out of 25 patients of our series 3(12%) patients came from a contagious parents.

In Group A the length of resected aganglionic segment was ranging from 10 cm to 25 cm with a mean of 15.31 cm (SD±3.82 cm).

In Group B the length of resected ananglionic segment was ranging from 12 cm to 30 cm with a mean of 18.67 cm (SD±6.93 cm) (Table-I).

**Table-I**

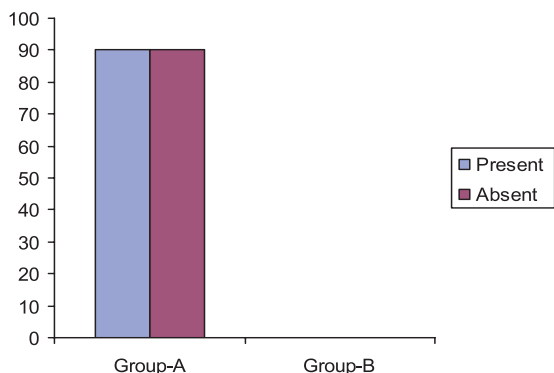
*Length of resected aganglionic segment (range and mean) in two groups.*

Length (cm)	Group-A (n <sub>a</sub> =13)	Group-B (n <sub>b</sub> =12)
Range	10 to 25 cms	12 to 30 cm
Mean	15.31 cm	18.67 cm

In Group A, the operative time for pull through was ranging from 120 min to 270 min with a mean of 156.92 min (SD±40.442 min) in group B, the operative time for pull through was ranging from 145 min to 300 min with a mean of 210.42 min (SD±49.838).

Operative time (range and mean) required fro pull through in two groups.

Two patients developed anastomotic stenosis in group-A after pull through & 2 patients developed anastomotic stenosis in Group-B.  $P < 0.50$  (Fig.-1).

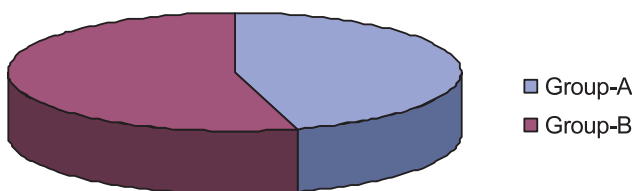


**Fig.-1 :** Anastomotic Stenosis in Group-A and Group-B.

None of the patients in our series developed disturbances of micturation.

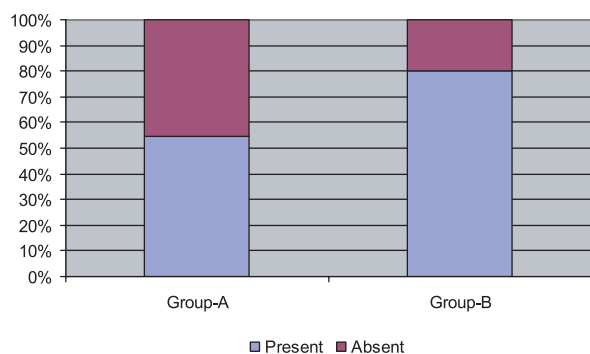
In Group-A first bowel movement occurred ranging from 2 to 5 days with a mean of 3.54 days (SD±0.775 days).

In group B first bowel movement occurred ranging from 2 to 4 days, with a mean of 3.8 days (SD±0.839 days) Fig.-2).



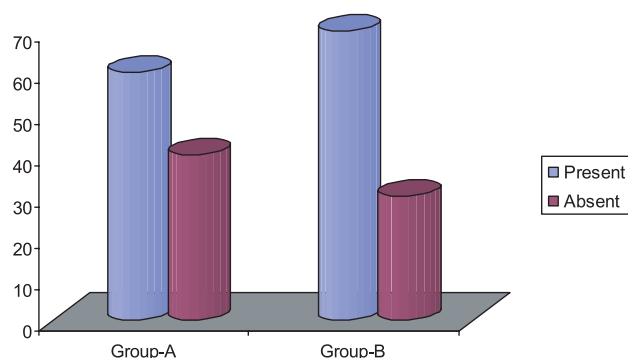
**Fig.-2:** First bowel movement in Group-A and Group-B patients.

Six patients in group-A developed postoperative perianal excoriation after colostomy closure & 10 patients development perianal excoriation in group B patient  $P < 0.05$  (Fig.-3).



**Fig.-3:** Perianal excoriation Group-A and Group-B patients

Eight patients developed incontinence of stool in group A patient after colostomy closure & 8 patients developed incontinence of stool in group B patient  $P > 0.50$  (Fig.-4).



**Fig.-4:** Incontinence of stool after colostomy closure.

**Discussion**

In our series, the average age of the patients were 26.15 months (range from 9 months to 72 months) in group A & 25.25 months (range 8 month to 36 month) in group B. Unpaired 't' test showed no significant difference ( $P > 0.10$ ) between the two different age groups. Thus both the groups were age matched for comparative study. Both the groups were sex matched with a uniform male : female ratio of 4:1  $P > 0.10$ , which is not significant. Similar male preponderance was found in a previous study at DSH, with a male female ratio of 4:01.<sup>5</sup> Comparable American & Japanese studies reported male : female ratio to be 4:1 & 3:1 respectively.<sup>6</sup>

In our series, consanguinity present in two patients (15.38%) in grpup-A & 1 patient (7.69%) in group-B  $P < 0.50$  which is not significant. None of the siblings was affected. The average length of resected anganglionic segment was 15.31 cm (range from 10 to 25 cm) in group A & 18.67 cm (range from 12 to 30 cm) in group B. A study<sup>7</sup> was done in DSH, in which resected lengths were 12.25 cm in endorectal pull through & 13.31 cm in Swenson procedure unpaired 't' test showed no significant difference ( $P > 0.10$ ) in the length of resected aganglionic segment in group A & B.

In this series, the average operative time for pull through was 156.92 min (range 120 to 270 min) in group A & 210.42 min (range 145 to 300 min) in group B. Unpaired 't' test showed highly significant difference ( $P < 0.01$ ) in the operative time in group A & group B patients.

A Mexican study showed that the operative time was ranging from 90 min to 300 min with an average of 186 min variation in the operation time for the procedure in our series was portable due to meticulous dissection in the cuff separation.

In our series anastigmatic stenosis is developed in 2 patients (15.38%) in group A & 2 patients (16.67%) in group B  $P > 0.50$  which is not significant

In a study anastigmatic stenosis is developed in 7.6% of the patients in Swenson procedure.

In our series, six patients (46.15%) in group A developed postoperative parietal excoriation for up to 2 to 3 visit after colostomy closure & 10 patients (83.33%) in group B. Subsequently with treatment excoriation was improved.

$\chi^2$  test showed significant difference ( $P < 0.50$ ) between the 2 groups with lesser chance of perianal excoriation in Swenson pull through procedure. None of the patients in our series developed enterocolitis.

In a study in DSH 12.5% of the patients developed enterocolitis after Swenson procedure.

An American study showed that 11.5% of the patients developed enterocolitis after Swenson procedure.

In 1628 Japanese patients, enterocolitis had been noted to occur in 34% after Swenson procedure.

In a western study 5 out of 31 patients developed enterocolitis after Swenson procedure.<sup>6</sup>

According to the western published reports the incidence of enterocolitis after repair of HD has not changed during recent years (Holschneider & Ure 2000)<sup>10</sup> thus both East & West there is increased incidence of postoperative enterocolitis after Swenson procedure.

The comparative study in the staged operative treatment of HD suggests that Swenson procedure was a better procedure ensuring economic by consuming significantly lesser operative time. Both the procedure produced significant lesser incidence of operative complications but better functional results & patients

parenteral satisfaction without requiring any additional operative procedure for the treatment of complications.

Statistically, the difference between the two procedures are not significant except operative time. Both the procedures were safer, more comfortable & one procedure was effective alternative to others in staged operative treatment of HD.

#### **Conclusion:**

The study shows the results are good & equally comparable in both the procedures as far as outcome is concerned. Soave-Boley procedure requires little extra-time with the available expertise in anaesthesia & postoperative care, this extra time should not be taken as a deterrent to practice Soave-Boley procedure. The researcher feels that the choice between the two procedures for pull through operation of HD should be left to individual paediatric surgeons.

#### **References:**

1. Martucciello G, Ceccherini I, Lerone M, Jasonni V. Pathogenesis of Hirschsprung's disease. *Journal of Pediatric Surgery* 2000; 35: 1017-1025.
2. Leapl LL. Patient care in Pediatric surgery. Boston: Little, Brown & Company, 1987; 165-69.
3. Jordan FT, Coran AJ, Weintraub WH, Wesley JR. An evaluation of the modified endorectal procedure of Hirschsprung's disease. *Journal of Pediatric surgery* 1979; 14: 681-85.
4. Polley TZ, Coran AG & Wesley JR, A ten year Experience with Ninety two cases of Hirschsprung's Disease. *Ann Surg* 1985; 1: 349-55.
5. Rahman L. Clinical diagnosis of Hirschsprung's Disease (Thesis) Dhaka, University of Dhaka, 1992.
6. Teitelbaum DH, Coran AG, Weitzman JJ, Ziegler MM, Kane T. Hirschsprung's Disease and related Neuromuscular disorders of intestine. O'Neil A, Rowe I, Grosfeld L, Fonkalsrud W, Coran G. *Pediatric Surgery*. 1998: 1381-1424.
7. Ullah ASMW. Comparison between Transanal pull through and Swenson procedure in the three stage operative treatment of rectosigmoid Hirschsprung's Disease. (Thesis). Dhaka, University of Dhaka, 2001.