

# Histoplasmosis - An Unusual Cause of Spastic Paraplegia in an Immunocompetent Host in Bangladesh

CHAYAN KUMAR SINGHA<sup>1</sup>, ESHITA BISWAS<sup>2</sup>, FERDOUS JAHAN<sup>1</sup>, PRODIP KUMAR BISWAS<sup>3</sup>

## Abstract:

*A case of disseminated histoplasmosis in a 62-year immunocompetent healthy male presenting as compressive myelopathy without any pulmonary involvement or travel to endemic zone is described. The patient presented with fever, dull ache pain in the back of the lower chest, weakness of both lower limbs with impairment of emptying of bowel and bladder, physical findings include raised temperature, generalized lymphadenopathy, nontender mild hepatomegaly, spastic paraplegia with sensory level up to D8 and local tenderness over D7 vertebra without any gibbus. Diagnosis was confirmed by presence of histoplasma capsulatum in the lymph node and soft tissue from the spine. The particular interest of this paper is to present a case of disseminated histoplasmosis especially presenting as spastic paraplegia in an immunocompetent host without pulmonary involvement and illustrates the importance of recognizing the possibility of histoplasmosis in Bangladesh where mimickers of histoplasmosis like tuberculosis is extremely common.*

**Keywords:** Histoplasmosis, Disseminated histoplasmosis, Histoplasma Capsulatum, immunocompetent host, spastic paraplegia.

## Introduction:

Histoplasmosis is the most common endemic mycosis in human. It has recently emerged as an important opportunistic infection among human immunodeficiency virus (HIV) infected persons living in areas where it is endemic.<sup>1</sup> Histoplasma capsulatum is a dimorphic fungus that remains in a mycelial form at ambient temperature, and grows as yeast at body temp. It was first described by Samuel Darling in 1906 in an adult patient who presumably died of miliary tuberculosis.<sup>2</sup>

Initial infection is spread via respiratory tract through which it enters the reticuloendothelial system and resides in macrophages. Most individuals with intact cellular immunity are asymptomatic or have mild pulmonary symptoms. Severe disseminated histoplasmosis (DH) develops in patients with primary or secondary immunodeficiency.

Its presentation varies depending on the size of the inoculum, host immune status, and presence of underlying host disease. Approximately 10% cases of histoplasmosis develop into progressive disseminated histoplasmosis.<sup>3</sup> DH can be fatal if untreated. In Bangladesh, reporting

of DH in medical literature is very rare especially as the cause of spastic paraplegia. The successfully treated 1<sup>st</sup> reported case in Bangladesh was in 1982.<sup>4</sup> We report our experience to increase awareness of the clinical spectrum of DH where it is similar to other infections particularly Tuberculosis and metastatic malignancy.

## Case Report:

A 62-year old male non-diabetic, farmer was admitted with the complaints of low grade fever for 3½ months, pain in the back of the lower chest for 2 months, weakness of the both lower limbs with impaired emptying of bowel and bladder for 2 months. His past history was unremarkable, and denied any H/O extramarital sexual exposures or contact with any sputum positive pulmonary tuberculosis patient. He was not on any drug that might have induced immunosuppression. On examination revealed mild anemia, temperature-99°F, generalized non-tender discrete lymphadenopathy. Neurological examination revealed spastic paraplegia with sensory level up to D8 and local tenderness over D7 vertebra without any gibbus. Abdominal examination revealed non-tender 4cm hepatomegaly, vitals were normal and other systemic examination revealed no abnormality. The patient's laboratory investigation results showed hemoglobin 9.2 gm/dl, total WBC- 7500/mm<sup>3</sup> ESR- 84 mm in 1<sup>st</sup>-hr, chest X-ray was normal. MT- 4 mm, USG showed mild hepatosplenomegaly, serum PSA-3.84, x-ray dorsal spine showed reduced joint space between D7 and

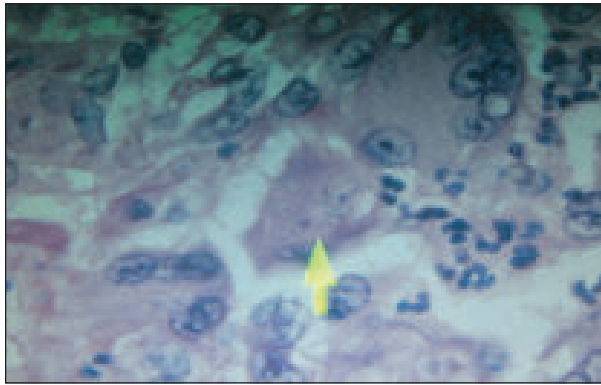
1. Medical Officer, Department of Medicine, BSMMU

2. Medical officer, Bangladesh Shilpokola Academy

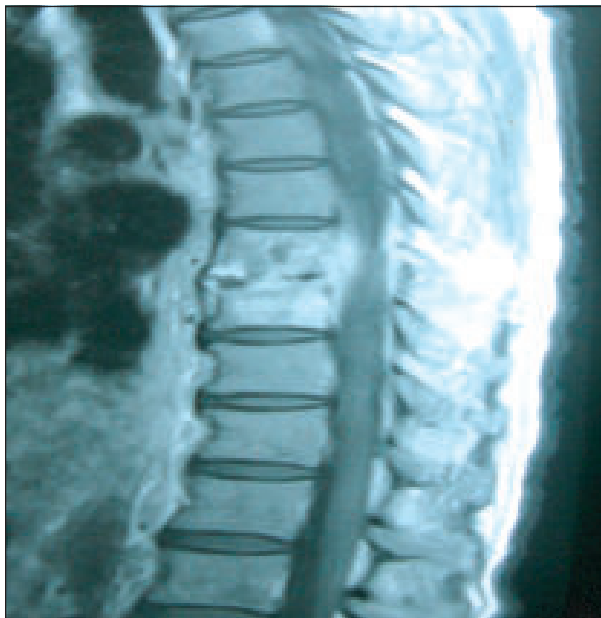3. Resident, Department of Gastroenterology, BSMMU

**Correspondence :** Dr. Chayan Kumar Singha, FCPS (Medicine), Medical Officer, Department of Medicine. BSMMU, Dhaka. e-mail: chayansmmu@gmail.com.

D8. Lymph node biopsy showed multiple PAS positive fungal budding yeast, microbiological investigation of soft tissue from the back showed intracellular parasite compatible with *histoplasma capsulatum*. MRI of dorsal spine showed reduction of joint space between D7 to D8 and paravertebral soft tissue compressing the spinal cord. HIV screening was negative, CD4-845 cells/micro liter, CD8-543 cells/micro liter. He was treated with neurosurgical explorations and stabilization of vertebrae and started on intravenous amphotericin-B followed by oral itraconazole. One month later of his next follow up his condition was improved markedly.



**Fig-1:** Showing budding yeast of *histoplasma capsulatum*.



**Fig-2:** Showing reduction of disc space with paravertebral soft tissue.

#### Discussion:

Histoplasmosis is the most prevalent endemic mycosis in the United States. An estimated 40 million people in the United States have been infected with *Histoplasma*.

*capsulatum*, with 500,000 new cases occurring in each year.<sup>5-7</sup> In Bangladesh sporadic cases have been reported in different literature.<sup>8-10</sup>

The causative agent *histoplasma capsulatum* grows in soil laden with excreta of chickens, Pigeons, starlings, blackbirds and bats<sup>11</sup>. Exposure occurs through contact with chicken house, soil containing large amount of bird or bat guano and old houses or caves known to be bat roosts.<sup>11</sup> Incidence of histoplasmosis in non-endemic areas is far fewer than endemic areas. Commonly, histoplasmosis occurs in non endemic areas due to travel or residence in endemic areas.

Disseminated histoplasmosis may present either as self limited disease or progressive disseminated H<sup>12</sup>. The self-limited condition is found in acute histoplasmosis. Histoplasmosis occurs during the first few weeks of illness when hematogenous dissemination leads to development of various clinical features like hepatomegaly, splenomegaly, bone marrow suppression, elevated hepatic enzymes are some of the features. Calcified granuloma in the spleen is a common finding in people living in the endemic zone. Blood culture is rarely positive in acute stage. Specific cell mediated immunity plays an important role in controlling the infection in lung and extra pulmonary tissues.

Progressive disseminated histoplasmosis (PDH) usually occurs either in patients at extremes of age or patients with an underlying immune deficiency states. Not all patients harbor an immunodeficient status.<sup>12</sup> Unidentified mechanism leading to immune deficiency is thought to be behind these cases. Ongoing research has identified defects in interferon-alpha/interleukin-12 pathway as a possible explanation in otherwise healthy individuals who develop PDH.<sup>13</sup> Approximately 10% cases of histoplasmosis develop PDH.<sup>13</sup> In 80% of patients, symptoms are nonspecific and include fever, chills, myalgia, nonproductive cough, and chest pain. The acute syndrome can range from mild (lasting 1-5 days) to severe (lasting 10-21 days); the latter is associated with weight loss, fatigue and night sweats. Fatigue may persist for weeks after the acute symptoms resolve. Patient may develop a variety of clinical manifestations which include fever, weight loss, fatigue, respiratory complaints like cough and shortness of breath. Hepatomegaly, splenomegaly, lymphadenopathy, bone marrow involvement are found in less than 50% of cases. Central nervous system involvement occurs in 5 to 20 percent of cases.<sup>13</sup> Other less common manifestations include oropharyngeal ulcers, gastrointestinal hemorrhage, adrenal insufficiency, subacute to chronic meningitis and endocarditis, pleuritis, pneumonitis, pancreatitis, cholecystitis, osteomyelitis, septic arthritis and epididymitis. Few patients may present with acute shock

like episodes with hypotension and coagulopathy. Rarely disseminated histoplasmosis can cause hypercalcemia due to calcitriol production by activated macrophage, which may lead to the incorrect diagnosis of sarcoidosis.

Histoplasmosis can be diagnosed by growth of histoplasma in culture, fungal stains (Bone marrow aspirate, peripheral blood Smear, lymph node biopsy, bronchoalveolar, lavage fluid, transbronchial biopsy, cutaneous biopsy or according to the affected site),<sup>14</sup> Serologic test for antibodies and antigen detection. Skin testing is rarely useful as a diagnostic measure because of high positivity in endemic areas and false-negative results associated with chronic pulmonary and disseminated disease<sup>14</sup>. Among all these, bone marrow examination has the highest diagnostic yield.<sup>14</sup> Antigen detection in urine and serum by radioimmunoassay is useful in immunocompromised patient when antibody production may be impaired. It is highly sensitive in disseminated infection. It can also be used for monitoring response to treatment especially in AIDS patient the most common finding on chest imaging is diffuse interstitial or reticulonodular infiltrates and millary infiltrates. Chest X-ray in chronic pulmonary histoplasmosis may also show upper lobe involvement with cavitations leading to misdiagnosis of pulmonary tuberculosis<sup>14</sup>.

The recommended treatment regimen for disseminated histoplasmosis is liposomal Amphotericin B for 1-2 weeks followed by oral itraconazole for at least 12 months<sup>15</sup>. Suppressive therapy with itraconazole may be required in immunocompromised patients like AIDS on organ transplant patient.<sup>16</sup>

Our patient presented with fever, back pain followed by lower limb weakness with impaired bowel and bladder emptying. Before admission his symptoms and imaging findings lead to clinical diagnosis of disseminated tuberculosis involving spine and lymph node which is widely prevalent in Bangladesh. However lymph node biopsy and soft tissue from back of the spine showed histoplasma capsulatum. Subsequently he was managed accordingly. Indeed histoplasmosis is under reported from Bangladesh due to low index of suspicion and lack of diagnostic facility. Another possible explanation of under diagnosis is that disseminated histoplasmosis resembles visceral leishmaniasis in many aspects of same clinical features. Moreover, both of the two condition responsive to Amphotericin B.

#### Conclusion:

This case illustrates the importance of high index of suspicion for diagnosing histoplasmosis in a patient presenting with features suggestive of tuberculosis and sometimes when

fail to respond to anti tubercular therapy after a reasonable period of time. Increasing prevalence of AIDS, Organ transplantation and expanding international travel is likely to heighten the possibility of histoplasmosis. Bangladesh physician need to alert them to this under diagnosed infectious disease which is ultimately fatal if left untreated.

#### References:

1. Cano MV, Hajjeh RA. The epidemiology of histoplasmosis: a Review. *Semin Respir Infect* 2001; 16(2):109-18.
2. Subramanian S, Abraham OC, Rupali P, et al. Disseminated Histoplasmosis. *J Assoc Physicians India* 2005; 53:185-189.
3. Joshi SA, Kagal AS, Bharadwaj RS, et al. Disseminated Histoplasmosis. *Indian J Med Microbiol* 2006; 24:297-298.
4. Islam N, Chowdhury NA. Histoplasmosis from Bangladesh: a Case report. *Bangladesh Med Res Counc Bull* 1982; 8(1): 21-24.
5. Conces DJ Jr. Histoplasmosis. *Semin Roentgenol* 1996; 31:14-27.
6. Benenson AS, ed. Control of communicable diseases manual. 16th ed. Washington DC: American Public Health Association 1995, pp. 237-240.
7. Springston JP. The birds. *Occup Health Saf* 1998; 67:86-9.
8. Rappo U, Beitler UR, Faulhaber JR, et al. expanding the horizons of histoplasmosis: disseminated histoplasmosis in a renal transplant patient after a trip to Bangladesh. *Transpl Infect Dis* 2009; 1-6.
9. Mahbub MS, Ahsan MN, Miah MT, Alam MB, Gupta RD, Arif KM, Hasnain M: Disseminated histoplasmosis. *J Medicine* 2010; 11:70-73.
10. Rahman MM, Hossain SM, Faiz MA, Rahman J, Sultan MT, Dewanjee AK: Disseminated Histoplasmosis in AIDS. *J BCPS* 2005; 23: 43-45.
11. Rappo U, Beitler UR, Faulhaber JR, et al. expanding the horizons of histoplasmosis: disseminated histoplasmosis in a renal transplant patient after a trip to Bangladesh. *Transpl Infect Dis* 2009; 1-6.
12. Wheat LJ. Histoplasmosis: a review for clinicians from non-endemic areas. *Mycoses* 2006; 49:274-282.
13. Wheat LJ, Conger NG. Histoplasmosis. In: *Hospital DR, Rinaldi MG, eds. Diagnosis and Treatment of Human Mycoses*. New Jersey: Humana Press, 2008:318-329.
14. Doughan A. Disseminated histoplasmosis: Case report and brief review. *Travel Med Infect Dis* 2006; 4:332-35.
15. Wheat LJ, Freifeld AG, Kleiman MB, et al. Clinical practice guidelines for the management of patients with histoplasmosis: 2007 update by the Infectious Diseases Society of America. *Clin Infect Dis* 2007; 45:807-825.