

Review Article

Coarctation of Aorta as Shown in CT Aortogram

MD. FARUQUE,¹ MA RASHID,² MD. JABED IQBAL,³ F RAHMAN,⁴ MD. MAHMUDUR RAHMAN SIDDIQUE⁵

Abstract:

Coarctation of the aorta is a congenital heart disease where there is constriction of Aorta. Coarctation accounts for 15-20 % of congenital cardiac defects and is more common in males than in females. It occurs in 1 of 10,000 live births. Coarctation of the aorta is a condition for which surgical outcomes are good and children will lead normal and healthy lives without restriction of their activity. They will typically catch up in growth and have normal development following the recovery period of the surgery. Coarctation of the aorta is typically treated by surgery to remove the narrowed segment of the aorta. Typically the surgery is best done when the child is between 18 and 24 months of age. Sometimes coarctation can be corrected by a balloon angioplasty procedure done during cardiac catheterization. A plastic tube will be inserted in the narrowed segment and a balloon in the tube will be inflated to stretch the narrowed segment. Sometimes a mesh tube is then inserted (called a stent) to hold the vessel open. Some infants will be very sick, requiring care in the intensive care unit (ICU) prior to the procedure and could possibly even need emergency repair of the coarctation. Others, exhibiting few symptoms, will have the repair scheduled on a less urgent basis. A small device, called a stent, may also be placed in the narrowed area after the balloon dilation to keep the aorta open. Overnight observation in the hospital is generally required.

Key words: Coarctation of aorta.

Introduction:

Coarctation of the aorta is a common congenital cardiovascular defect characterized by upper-body hypertension resulting from constriction of the aorta. Constrictions vary in degree; they may occur at any point from the transverse arch to the iliac bifurcation.

Narrowing of the aorta occurs in the region where the ductus arteriosus joins the aorta, i.e. at the isthmus just below the origin of the Left subclavian artery.¹

Coarctation of the aorta may occur as a discrete juxtaductal obstruction or as tubular hypoplasia of the transverse aorta. Hypoplasia may start at the head or neck vessels and extend to the ductal area (preductal or infantile-type coarctation). Often, both components are present.

Aortic coarctation is most likely related to an abnormality in the pattern of ductus arteriosus blood flow in utero, which, in turn, may be the result of associated intracardiac anomalies.

1. Prof. of Cardiology, Anwer Khan Modern Medical College, Dhaka,
2. Assoc. Prof, Dept. of Anatomy, Bangladesh Medical College, Dhaka,
3. Junior consultant, Cardiology, Anwer Khan Modern Medical College, Dhaka.
4. Professor, Dept. of Cardiology, BSMMU, Dhaka
5. Assistant Professor, Medicine, Anwer Khan Modern Medical College, Dhaka.

Correspondence: Prof. Dr. Md. Faruque, Professor of Cardiology, Anwer Khan Modern Medical College, Dhanmondi, Dhaka – 1205

In fetal life, blood flow through the aortic isthmus constitutes only 12-17 % of the total cardiac output, where as blood flow through the ductus arteriosus exceeds that across the aortic valve, Coarctation is initiated when a cardiac abnormality causes a decrease in blood flow antegrade through the aortic valve; abnormalities that may lead to coarctation include a bicuspid aortic valve and a ventricular septal defect (VSD).

In the first few days of life, the patent ductus arteriosus may serve to widen the juxtaductal area of the aorta and provide temporary relief from the obstruction, in these acyanotic infants, left to right ductal shunting occurs. In contrast with more severe juxtaductal coarctation or in cases involving transverse arch hypoplasia, right ventricular blood is ejected through the ductus to supply the descending aorta, as it does during fetal life. Perfusion of the lower body then depends on right ventricular output. In this situation, the femoral pulse is palpable and differential blood pressures may not be helpful in making the diagnosis.

The ductal right-to-left shunting is manifested as differential cyanosis, with the upper extremities being pink and the lower extremities being blue, in such cases, severe pulmonary hypertension and high pulmonary vascular resistance may be present. Signs of heart failure are prominent. Occasionally, severely hypoplastic segments of the aortic isthmus become completely atretic, resulting in an interrupted aortic arch, with the left subclavian artery arising either proximal or distal to the interruption.

Coarctation associated with arch hypoplasia is referred to as infantile type coarctation because it usually manifests itself in early infancy, owing to its severity. The adult type is isolated juxtaductal coarctation; if mild, such coarction usually does not manifest itself until later in childhood.

Blood pressure is elevated in the vessels that arise proximal to the coarctation; blood pressure and pulse pressure Below the constriction are lower, Hypertension is not the result of the mechanical obstruction alone; rather, neurohumoral mechanisms are also involved. Unless operated on in infancy, patients with coarctation of the aorta usually develop an extensive collateral circulation, chiefly from the branches of the subclavian, the superior intercostal, and the internal mammary arteries, which create channels for arterial blood to bypass the area of coarctation.

The vessel contributing to the collateral circulation may become markedly enlarged and tortuous by early adulthood. After pharmacologic interventions that dilate the ductus arteriosus (prostaglandin E1 infusion) are administered, the pressure difference may be obliterated across the site of coarctation because the fetal flow pattern is reestablished.

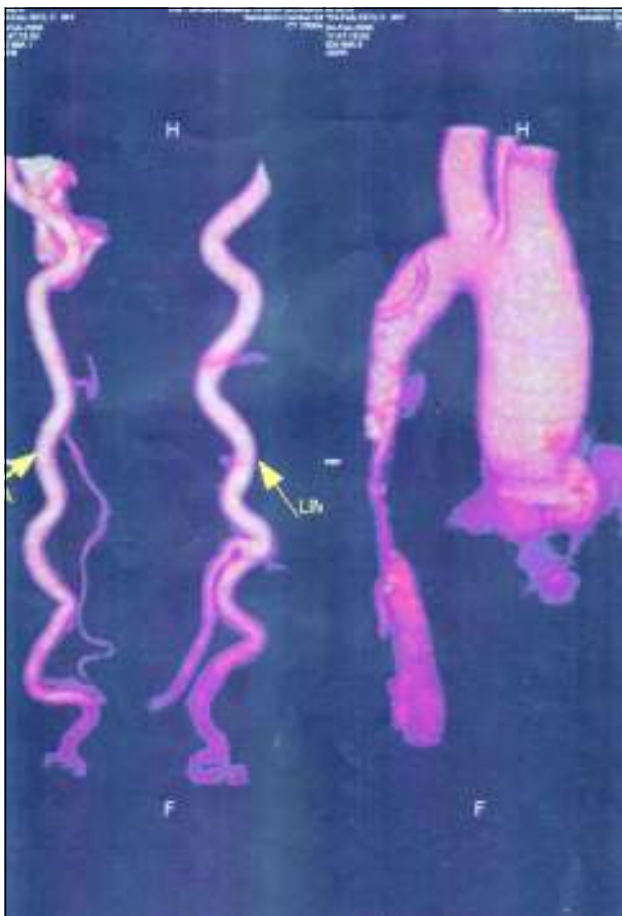


Fig-1: CT aortogram shows coarctation and dilated LIMA and RIMA due to establishment of collateral.

The pathogenesis of juxtaductal coarctation already described accounts for the prevalence of associated intracardiac anomalies that further reduced ascending aortic flow and augmented ductus arteriosus flow in utero, as well as the absence of associated intracardiac anomalies in which conditions of converse flow exist in utero.

The dependence of aortic obstruction on constriction of the ductus arteriosus postnatally accounts for the variable onset after birth of the clinical manifestations of coarctation, as well as the dramatic alleviation of the obstruction produced pharmacologically by dilatation of the ductus arteriosus.

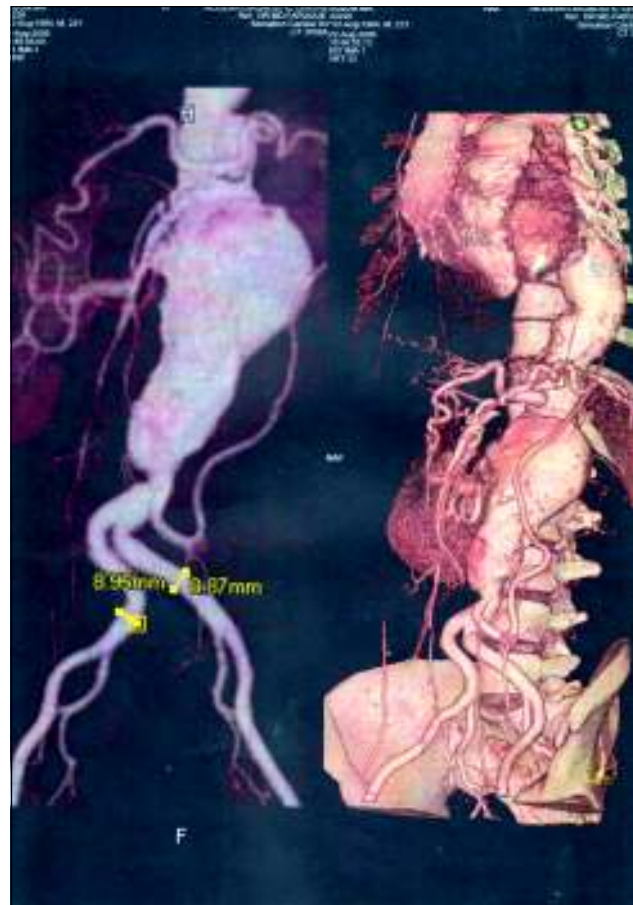


Fig.-2: CT aortogram shows atypical coarctation and aneurismal dilatation of abdominal aorta.

Discussion:

Aortic coarctation accounts for 8% of congenital heart defects in children and about 6% of congenital heart diseases in adults. It is associated with other abnormalities, most frequently bicuspid aortic valve and berry aneurysms of cerebral circulation.²

Subarachnoid or intracerebral hemorrhage may result from rupture of congenital aneurysms in the circle of Willis, of

other vessels with defective elastic and medial tissue, or of normal vessels; these accidents are secondary to hypertension.

The common serious complications are related to systemic hypertension, which may result in premature coronary artery disease, heart failure, hypertensive encephalopathy, or intracranial hemorrhage.

About 98 % coarctations occur immediately beneath the origin of the left subclavian artery at the site of attachment of the ductus arteriosus (juxtaductal coarctation).

Aortic coarctation is associated with a bicuspid aortic valve in more than 70% of patients. Mitral valve abnormalities, such as a supra-avalvular mitral ring or parachute mitral valve, subaortic stenosis may be associated lesions. A Significant pressure difference develops between arms and legs, allowing detection of a pulse discrepancy.³

The classic sign of coarctation of the aorta is a disparity in pulsations and blood pressures of the arms and legs. The femoral, popliteal, posterior tibial, and dorsalis pedis pulses are weak or absent (such pulses are found to be absent in up to 40% of patients); by contrast, bounding pulses are present in the arms and the carotid vessels.

The radial and femoral pulses should always be palpated simultaneously for the presence of a radial-femoral delay. Normally, the femoral pulse occurs slightly before the radial pulse. A radial-femoral delay occurs when blood flow to the descending aorta is dependent on collateral vessels, in which case the femoral pulse is felt after the radial pulse.

In healthy persons, the systolic blood pressure in the legs obtained by the cuff method is 10-20 mm Hg higher than that in the arms. In patients with coarctation of the aorta, the blood pressure in the legs is lower than that in the arms frequently; blood pressure is difficult to obtain in legs. The precordial impulse and heart sounds are usually normal; the presence of a systolic ejection click or thrill in the suprasternal notch suggests the presence of a bicuspid aortic valve (present in 70% of cases). Associated anomalies are VSD, stenosis or atresia of the left subclavian artery, PDA, Turner syndrome, and mitral valve prolapse.⁴

The enlarged left subclavian artery commonly produces a prominent shadow in the left superior mediastinum. Notching of the inferior border of the ribs from pressure erosion by enlarged collateral vessels is common. Fundoscopic examination can reveal "cork screw" tortuosity of retinal arterioles.^{4, 5}

Associated anomalies of the mitral and aortic valve may also be demonstrated. Color Doppler imaging is useful for

demonstrating the specific site of the obstruction. Pulse and continuous-wave Doppler study may be used to determine the pressure gradient directly at the area of coarctation. Cardiac catheterization with selective left ventriculography and aortography is useful in evaluating selected patients.

Heart failure can occur, as the heart has to work extra-hard to pump blood through the narrowed section of the aorta. The heart will enlarge because of this effort. High blood pressure is a complication in uncorrected coarctation because the kidneys receive the blood that is under lower pressure and they will secrete chemicals to raise the blood pressure to keep the kidneys perfused. High blood pressure can persist even after the coarctation is corrected.

High blood pressure can cause damage to various parts of the body (such as the eyes and kidneys), and it also can lead to serious conditions such as stroke. Thus high blood pressure should be monitored and treated throughout life. Problems with the aortic valve can also be found in about 30% of individuals with coarctation of the aorta, and this condition will also require careful assessment frequently.

Symptoms of coarctation of the aorta are Irritability, pale skin, sweating, heavy and / or rapid breathing, poor feeding, poor weight gain, headaches from high blood pressure in the head, cold feet or legs, cramps in the legs with exercise, abnormal heart sounds (heart murmur), dizziness or fainting, babies may have difficulty feeding and poor weight gain. Coarctation of the aorta may be seen with other congenital heart defects, such as: bicuspid aortic valve, single ventricle, Ventricular septal defects.

Complications that may occur before, during, or soon after surgery includes Aortic aneurysm, Aortic dissection, Aortic rupture, Bleeding in the brain, Endocarditis (infection in the heart), Heart failure, Hoarseness caused by injury to the nerve to the larynx, Impaired kidney function, Paralysis of the lower half of the body (rare complication of surgery to repair coarctation), Premature development of coronary artery disease (CAD), Severe high blood pressure, Stroke.

These complications may well be reduced if stents are used.^{6,7} The significance of aneurysm formation is often unknown and longer term data are necessary.⁸ Recoarctation after surgical repair is 5 to 10 percent. Doppler measurements can detect the presence of a recurrent obstruction.⁹ Recoarctation is usually addressed with balloon dilatation & balloon expandable stents have been employed with good success. Long term complications include continued narrowing of the aorta, endocarditis and high blood pressure.

Atypical CoA in various syndromes are in Takayasu arteritis, thoracic and abdominal aorta is commonly involved.

Granulomatous vasculitis can cause intima proliferation and consecutively aneurysm or stenosis of various degrees or even the occlusion of the aorta and its branches. High incidence of concomitant renal artery stenosis is reported, while celiac or superior mesenteric artery involvement is less often observed.

Williams syndrome is associated with supravalvular aortic stenosis, localized or extended narrowing of the ascending aorta beyond the superior margin of the sinuses of Valsalva. Williams syndrome is associated with coarctation of the abdominal aorta and renal artery stenosis. In neurofibromatosis type 1 (von Recklinghausen disease), atypical CoA is reported in the descending thoracic and abdominal aorta. The renal arteries are rarely involved. Stenosis may be attributed to the proliferation of Schwann cells within the vessels wall.

Conclusion:

Coarctation of aorta, a congenital constriction of the aorta, impeding the flow of blood below the level of constriction and increasing blood pressure above the constriction. Symptoms may not be evident at birth, may develop as soon as the first week after birth with congestive heart failure or high blood pressure that call for early surgery. Coarctation of aorta can be accurately diagnosed with CT angiogram or MRA. In teenagers and adults echocardiogram may not be conclusive. In adults with untreated coarctation blood often reaches the lower body through collaterals, those can be seen on CT angiography.

Conflict of Interest : None

References:

1. Aluquin VP, Shutte D, Nirill MR, et al: Normal aortic arch growth and comparison with isolated coarctation of aorta. *Am J cardiol.* 2003, 91: 502.
2. Levine JC, Sonders SP, Golan SD et al: The risk of having additional obstructive lesions in neonatal coarctation of the aorta. *Cardiol young.* 2001, 11:44.
3. O' Sukivan JJ, Derrick G, Darnell R. Prevalance of hypertension in children after early repair of coarctation of aorta. A cohort study using casual and 24 hour ambulatory blood pressure measurement. *Heart.* 2002, 88:163.
4. de Divitis M Pilla G, kuttenhorn M, etal: Ambulatory blood pressure, left ventricular mass and conduit artery function late after successful repair of coarctation of the aorta. *I am coll cordial.* 2003, 41:2259.
5. Zadinello M, Grave G, Liu XQ et al: Angiotensin 1 converting enzyme genotype aysects ventricular remodelling in children with aortic coarctation, *Heart.* 2005 91:367.
6. Zabal C, Attic F, Rosas M et al: the adult patient with native coarctation of the aorta: Balloon angioplasty or primary stenting ? *Heart* 2003, 89:77.
7. Tzifa A, Ewert P. covered cheatham – platinum stents term result. *I am coll cordial.* 2006, 47: 1457.
8. Harrison DA, Mc Laughlin PR, Lazzam C, et al: Endovascular stents in the management of coarctation of the aorta in the adolescent and adult: One year follow up. *Heart.* 2006, 85:561.
9. De May S, Segers P, Coomans I, et al: Limitations of Doppler echocardiography for the post operative evaluation of aortic coarctation. *J Biomech.* 2001, 34:95.