

# Primary Hypoparathyroidism - Misdiagnosed as Epilepsy

ISHRAT BINTE REZA,<sup>1</sup> CHANDRA SHEKHAR BALA,<sup>2</sup> ESHRAT ZARIN MUMU,<sup>3</sup> BHARUL MINNAT,<sup>4</sup> HAM NAZMUL AHASAN<sup>5</sup>

## Abstract:

*Absent or inappropriately low intact parathyroid hormone along with hypocalcemia is the diagnostic criterion of hypoparathyroidism. Clinically, hypoparathyroidism manifests predominantly as neuromuscular dysfunction caused by hypocalcemia. We present here a case of hypoparathyroidism wrongly and ineffectively treated as epilepsy for six years prior to reporting to our hospital. Hypoparathyroidism was diagnosed in our patient on the basis of low serum calcium (ionized and total), high phosphate and very low IPTH levels in face of normal magnesium levels along with radiological evidence of cerebral calcification.*

**Keywords:** Hypoparathyroidism, hypocalcemia, tetany, cerebral calcification.

DOI: <http://dx.doi.org/10.3329/jom.v19i2.37236>

## Introduction:

Hypoparathyroidism is an endocrine disorder caused as a result of congenital disorders, iatrogenic causes, infiltration of the parathyroid glands, suppression of parathyroid function, or idiopathic mechanisms.<sup>1</sup> In these cases either there will be apparent deficiency of PTH secretion or end-organ failure.<sup>2</sup> Idiopathic hypoparathyroidism is an uncommon condition of unknown aetiology. Acquired and congenital hypoparathyroidism would have either normal or undetectable PTH levels with hypocalcaemia whereas in idiopathic hypoparathyroidism both calcium and PTH levels are low.<sup>2</sup> In pseudo hypoparathyroidism PTH levels will be high with hypocalcaemia. In pseudopseudo hypoparathyroidism with increased PTH level both serum calcium and phosphorus levels are normal.<sup>2</sup>

## Case summary:

21 yrs old man presented to us with the complaints of recurrent episodic rigid movement of the limbs for 6yrs. It used to last for few seconds. But there was no history of loss of consciousness, fall from height, incontinence of urine and stool, tongue bite, amnesia. Sometimes he also experienced cramp and twitching of limbs. Initially it was 2/3 months interval later its frequency increased and used to develop every week. On query he gave a history of perioral paresthesia, tingling of the hands and feet. He also had

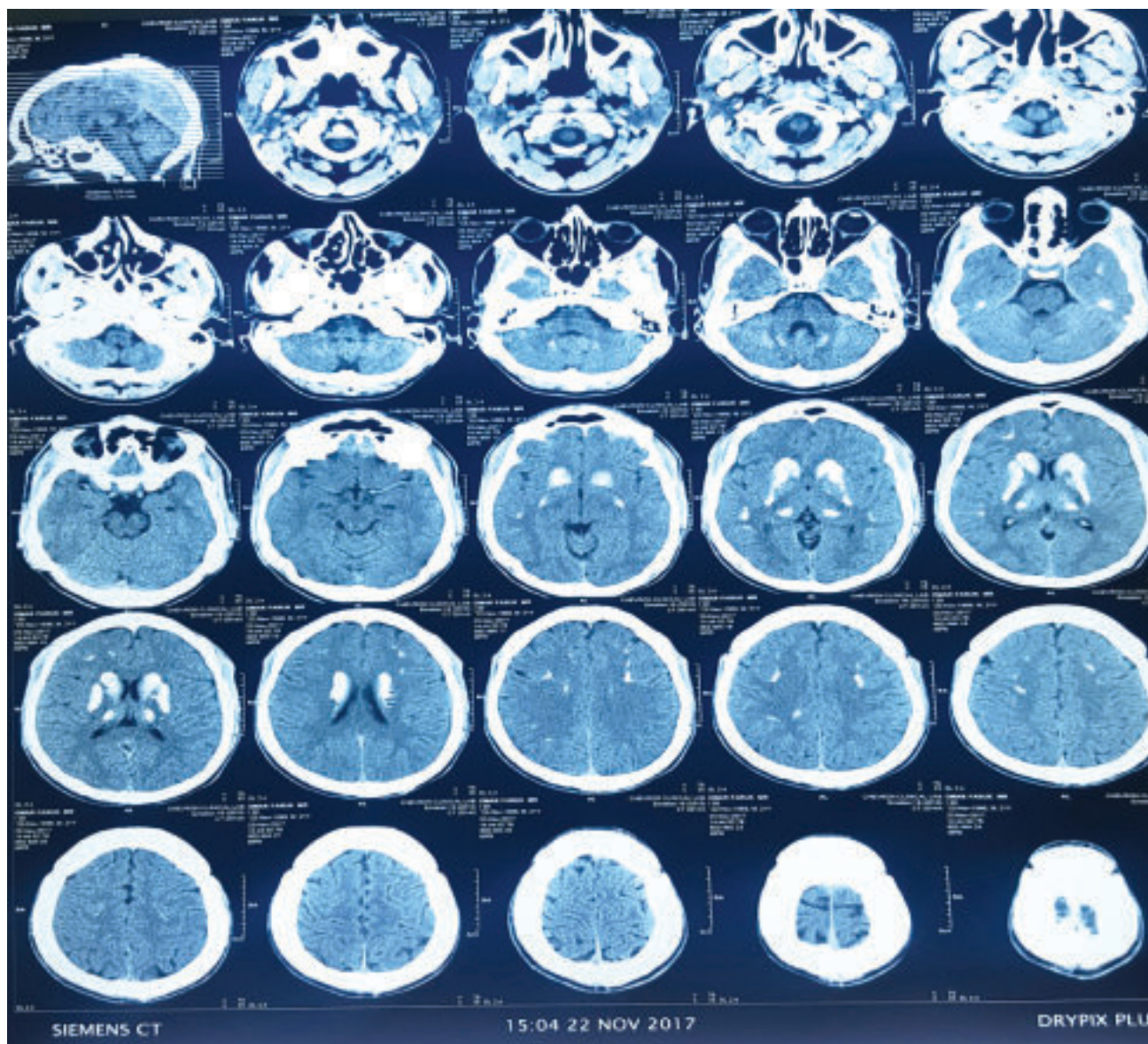
history of progressive dimness of vision of both eyes for the last 1 yr and he had undergone cataract surgery of right eye for this. He also gave a history of generalized weakness for same duration. His bowel and bladder habit was normal. On checking his prescription and reports, it was found that she was being treated with antiepileptic drugs. But his condition didn't improve. A CT scan of brain revealed excessive bilateral symmetrical calcification in cerebral and cerebellar hemisphere (Figure 1). On examination BP was 110/70 with no postural drop, P 80b/min, Trousseau was sign positive, but chovstek sign was negative. Ophthalmoscopic examination revealed psuedophakia in the right eye and presenile cataract in other eye, fundus was normal. He had no dysmorphic features. A CT scan of brain revealed excessive bilateral symmetrical calcification in cerebral and cerebellar hemisphere. Electrocardiogram revealed episodes of sinus rhythm with short PR interval 214 and prolong QTc interval over 494 ms. Serum calcium was 3.88 mg/dl [8.4-10.2], thyroid stimulating hormone [TSH] 4.04 ¼ IU/ ml [0.25-5], intact parathyroid hormone [IPTH] 1.70pg/ml [15-65], phosphorus 9 mg/dl [2.5-4.5], magnesium 1.30mg/dl [1.6-2.5], haemoglobin 13.5g/dl [12-15], fasting plasma glucose 100.4 mg/dl[70-110]. Albumin and 25 hydroxyvitamin D levels were within reference range. No nutritional, familial, congenital, infiltrative or autoimmune cause of hypoparathyroidism was obvious. Our tests for ANA and APLA by IFA and ELISA respectively tested negative. Patient never had surgery or irradiation of neck. Eye examination revealed no abnormality. Cortisol level was within reference range, excluding hypoadrenalism. On clinical examination, there was no evidence of mucormycosis or any other fungal infection. The patient was diagnosed as primary hypoparathyroidism and treated with calcium and activated vitaminD [1, 25 dihydroxycholecalciferol]. During discharge his calcium level was 6.05mg/dl. After that he has not complained the presenting feature.

1. Registrar, Department of Medicine, Popular Medical College, Dhaka
2. Junior Consultant, National Institute of Neurosciences and Hospital Dhaka, Dhaka
3. Assistant Registrar, Popular Medical College, Dhaka
4. MPH(Thesis) student, State University of Bangladesh, Dhaka
5. Professor of Medicine, Popular Medical College, Dhaka

**Corresponding Author:** Dr. Ishrat Binte Reza, Registrar, Department of Medicine, Popular Medical College, Dhaka. Email: [ishrat.reza@yahoo.com](mailto:ishrat.reza@yahoo.com).

**Received:** 04 March, 2018;

**Accepted:** 24 May, 2018



**Figure 1:** CT scan of brain showing excessive bilateral symmetrical calcification.

#### Discussion:

The clinical presentation of hypocalcaemia in hypoparathyroidism is usually insidious and classical symptoms may be absent, even in patients with profound hypocalcaemia.<sup>3</sup> Hypocalcaemia may be an asymptomatic laboratory finding or a life-threatening metabolic disturbance. Its prevalence is 18% in all patients in hospital and 85% in the intensive care unit.<sup>4</sup> The clinical algorithm for the workup of the patient who presents with hypocalcaemia<sup>5</sup> aims to differentiate hypocalcaemia associated with an absent or inappropriately low serum parathyroid hormone concentration (hypoparathyroidism) from hypocalcaemia associated with an appropriate compensatory increase in

parathyroid hormone. Transient hypoparathyroidism with biochemical abnormalities is commonly seen (>83% of cases) after thyroid surgery.<sup>6</sup> However, our patient had no recent or remote history of thyroid/neck surgery or irradiation. Magnesium level of our patient was low, which ruled out nutritional deficiency. Basal ganglia calcification occurring in idiopathic hypoparathyroidism correlates with the duration of hypocalcaemia, choroid plexus calcification, seizures and cataract and has been observed to worsen despite maintenance of normal calcium levels.<sup>7</sup> The culprit is believed to be the high serum calcium-phosphorus product ratio and poor calcium control. A literature review of the clinical presentations of basal ganglia calcification revealed that there

are diverse presentations, the most common including seizures, mental deterioration, and disorders of cerebellar or extra-pyramidal function.

Movement disorders, chorea or Parkinsonism are present in 20 - 30% of patients with basal ganglia calcification, while some patients are asymptomatic.<sup>8</sup> Decreased PTH level and hypocalcemia exclude other causes of intracerebral calcifications like pseudohypoparathyroidism, hyperparathyroidism, monoxide carbon intoxication, encephalitis, Fahr disease, idiopathic basal ganglia calcifications, Cocayne syndrome, tuberous sclerosis, neurofibromatosis, vascular disease (vascular malformations, chronic ischemic or hemorrhagic stroke), cerebral parasitosis<sup>9</sup>. Our patient's recovery from tetany with vitamin D and calcium, absence of family history of similar features and biochemical test results helped rule out Fahr's syndrome<sup>10</sup>. Due to financial constraints, no genetic testing could be done. In a prospective study, Aggarwal and colleagues found there was a significant association between cognitive dysfunction and the duration of hypocalcemia, serum calcium levels, and calcium-phosphorus complex formation, but no association with serum 25(OH) D levels, serum PTH levels, or the volume or site of basal ganglia calcification.<sup>11</sup> Presently, treatment consists of calcium supplementation and the use of vitamin D analogs, but PTH replacement is under investigation.<sup>12</sup> Oral calcium and vitamin D restore the overall calcium-phosphate balance.<sup>13</sup>

#### Conclusion:

Since adequate treatment of hypoparathyroidism may lead to marked clinical improvement and due to its rarity, it is warranted to do serum concentration of calcium, phosphorus, and parathyroid hormone in all individuals with calcification of the basal ganglia to rule out hypoparathyroidism.

**Conflict of interest:** None.

#### References:

- Girija AS. Idiopathic hypoparathyroidism with extensive intracranial calcification associated with kinesogenic choreoathetosis. *J Assoc Physicians India* 2000;48(9):938-939.
- Hypoparathyroidism, pseudohypoparathyroidism, pseudopseudohypoparathyroidism, chapter metabolic and endocrine disease of the skeleton. by J.B.Vogler III and J.H.Kim - Diagnostic Radiology 4th edition, volume three.
- Mukhopadhyay R, Strens LH, Winer JB, Ayuk JA, Gittoes NJ. Having the vision to measure calcium. *J Neurol*. 2010;257(6):1032-4.
- Cooper MS, Gittoes NJL. Diagnosis and management of hypocalcaemia. *BMJ* 2008;336:1298-302.
- Bilezikian JP, Khan A, Potts Jr JT, Brandi ML, Clarke BL, Shoback D, et al. Hypoparathyroidism in the Adult: Epidemiology, Diagnosis, Pathophysiology, Target Organ Involvement, Treatment, and Challenges for Future Research. *J Bone Miner Res*. 2011;26(10):2317-2337.
- Dedivitis RA, Pfuetszenreiter EG, Jr, Nardi CE, Barbara EC. Prospective study of clinical and laboratorial hypocalcemia after thyroid surgery. *Braz J Otorhinolaryngol* 2010;76: 71-7.
- Goswami R, Sharma R, Sreenivas V, Gupta N, Ganapathy A, Das S. Prevalence and progression of basal ganglia calcification and its pathogenic mechanism in patients with idiopathic Hypoparathyroidism. *Clin Endocrinol (Oxf)*. 2012;77(2):200-6.
- Koller WC, Cochran JW, Klawans HL. Calcification of the basal ganglia: computerized tomography and clinical correlation. *Neurology*. 1979;29(3):328-33.
- Sabau M, Comanescu A, Maghiar T, Dinulescu D. Hypoparathyroidism diagnosed by neurological signs and widespread intracerebral calcifications. *Romanian journal of neurology* 2010; 9(1):44-50.
- Saleem S, Aslam HM, Anwar M, Anwar S, Saleem M, Saleem A, et al. Fahr's syndrome: literature review of current evidence. *Orphanet Journal of Rare Diseases* 2013;8:156.
- Aggarwal S, Kailash S, Sagar R. Neuro-psychological dysfunction in idiopathic hypoparathyroidism and its relationship with intracranial calcification and serum total calcium. *Eur J Endocrinol* 2013; 168:895-903.
- Wong EMM, Dahl M. Basal ganglia calcification in idiopathic hypoparathyroidism. *BCM J* 2013; 55(10):462-465.
- Rizvi I, Ansari NA, Beg M, Shamim MD. Widespread Intracranial Calcification, Seizures and Extraparapyramidal Manifestations in a Case of Hypoparathyroidism. *North Am J Med Sci* 2012; 4:369-72.