

# TUBERCULOSIS OF STERNOCLAVICULAR JOINT - UNCOMMON MANIFESTATION OF A COMMON DISEASE

ANKIT SHRIVASTAV<sup>1</sup>, JYOTIRMOY PAL<sup>2</sup>, PARTHO SARTHI KARMAKAR<sup>3</sup>, NIRODH BARAN DEBNATH<sup>4</sup>

## Abstract

*15 % of Tuberculosis patients have extra pulmonary lesions of which 1 to 3 % have bone and joint lesions. In the musculoskeletal system, tuberculous spondylitis is most typical form of the disease; however, joint changes in extraspinal sites, such as the hip, knee, wrist & elbow, also may occur. Involvement of sternoclavicular joint is very rare. In 2 of the world's largest series of osteoarticular TB, sternoclavicular joint involvement was reported in less than 0.5% of cases with less than 20 cases reported till date. However, with the emergence of drug resistant tuberculosis and large number of immunocompromised patients, the incidence may increase. We report a case of left sternoclavicular joint tuberculosis in an adolescent boy. As this entity is rare, level of suspicion is low and suspicion regarding TB arises only after poor response to antibiotic treatment. Early diagnosis and treatment is mandatory for good result*

**Keyword:** Tuberculosis, sternoclavicular joint, extrapulmonary tuberculosis

## Introduction

Tuberculosis is an infectious disease caused by *Mycobacterium tuberculosis* and manifested by formation of tubercles and caseous necrosis in tissues. In the musculoskeletal system, tuberculous spondylitis is the most typical form of the disease; however, joint changes in extraspinal sites, such as the hip, knee, wrist and elbow, also may occur. Rare sites include the sternoclavicular joint. Characteristically, the tissues respond to the mycobacterial infection by forming tubercles with clusters of epithelial cells surround a central zone of caseating necrosis. We report a case of left sided sternoclavicular joint tuberculosis in an adolescent boy. As this entity is rare, level of suspicion is still low and suspicion regarding TB arises only after poor response to antibiotic treatment. Early diagnosis and treatment is mandatory for good result

## Case report

A 12 years old male from rural background presented with low grade fever for 3 months and gradually

increasing swelling of left sternoclavicular joint for last 2 months. He had no history of cough or haemoptysis. His gait and shoulder joint movements were normal. He had no past history of tuberculosis (TB) or any history of contact with any patient of TB.

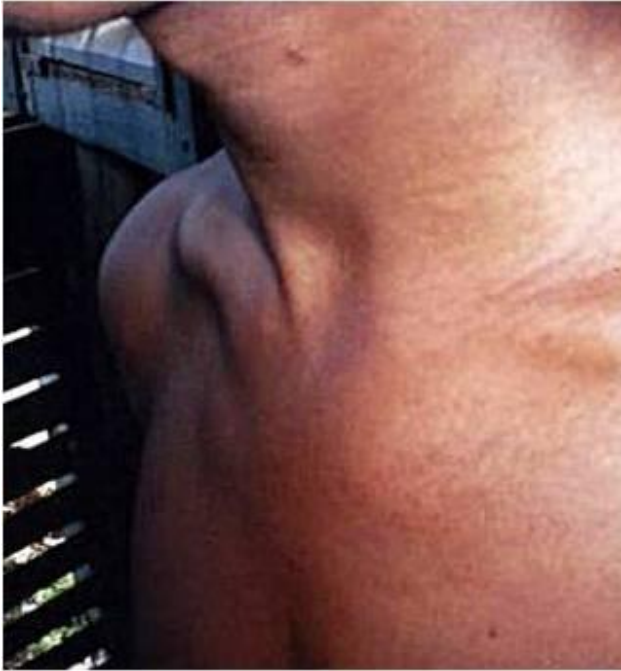On general survey, the patient had mild anemia and low-grade fever. He had no lymphadenopathy. He had bilateral vesicular breath sound with no added sounds. Other systems were within normal limit. The swelling on left sternoclavicular joint was hot, tender but soft, about 5 x 6 cm in size. The overlying skin was shiny, no sinuses tracts were noted. (Fig. 1)

Routine investigations were within normal limits except for low Hb (9.5gm%), and raised ESR(112 mm). Total WBC count was normal. Chest X-ray was normal with no bone destruction or any pulmonary lesion. Sternoclavicular joint was also normal.

An aspiration from left sternoclavicular joint was done and sent for Gram stain, AFB stain, culture and histopathology. The cytology smears showed

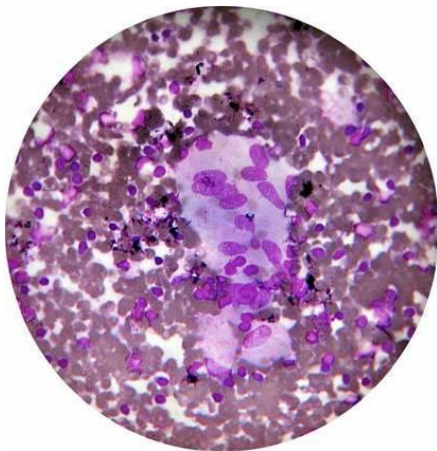
1. Senior Resident, Dept of Endocrinology & Metabolism, Institute of Post Graduate Medical Education & Research, Kolkata, West Bengal, India
2. Associate Professor, Dept of Medicine, North Bengal Medical College & Hospital, Siliguri, West Bengal, India
3. Associate Professor, Dept of Medicine, Institute of Post Graduate Medical Education & Research, Kolkata, West Bengal, India
4. Professor & Head, Dept of Medicine, BS Medical College, Bankura, West Bengal, India

**Correspondence:** Dr Ankit Shrivastav, MD (Med), Senior Resident, Dept of Endocrinology & Metabolism, Institute of Post Graduate Medical Education & Research, Kolkata, West Bengal, India. E-mail: ankit.med@gmail.com

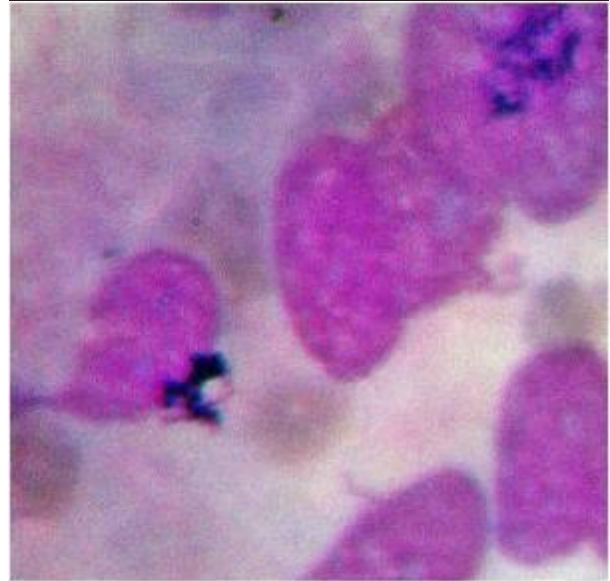


**Fig-1:** Swelling on left sternoclavicular joint

features of epithelioid granuloma with some caseation suggestive of tuberculous lesion (Figure 2 & 3) Gram stain and cultures were normal. Sputum examination was done which was within normal limit. Mantoux test was positive and tests for immunocompromised status (HIV) were negative. He was started on four drugs anti-TB drugs (ATD) — rifampicin, isoniazid, ethambutal and pyrizinaide. Within a period of 2 month his symptoms improved and the swelling of left sternoclavicular joint had subsided. The patient was advised to complete the course of ATD and had complete response with no residual impairment.



**Fig.-2:** Cytology smear showing features of epithelioid granuloma



**Fig.-3:** Cytology smear showing features of epithelioid granuloma

### Discussion

Infection of the sternoclavicular joint is rare with tubercular infection being even rarer.<sup>1</sup> In a reported series of septic arthritis, sternoclavicular joint involvement is found in only 9% of patients.<sup>2</sup> In a case review of all the 180 report cases of sternoclavicular septic arthritis, tuberculosis was reported in less than 5 % of the cases with staphylococcus aureus alone being responsible for around 49% of cases. Clinical findings of sternoclavicular joint may be same- hot, swollen, tender in both septic bacterial and tubercular arthritis, so diagnostic confusion is likely. Due to the rare occurrence of sternoclavicular TB, the diagnosis may often be difficult. Poor response to antibiotic therapy leads to suspicion of underlying TB and relevant investigations are done. The delay in treatment may lead to more joint destruction and disabling sequelae.

Patients usually present with insidious onset, painful or painless swelling.<sup>1</sup> There may be a cold abscess or sinus formation. Our patient presented with fever, pain and swelling of the left sternoclavicular joint. Source of infection in all cases of osteoarticular TB is haematogenous dissemination from a primary infected visceral focus, which may be the lung, lymph node or other viscera.<sup>1</sup> Contiguous involvement from apical pulmonary lesion has also been implicated. But evidence of pulmonary tuberculosis may not be present, as it was in our case.<sup>3,4,5</sup>

Differential diagnosis is rather broad and includes septic arthritis, rheumatoid arthritis, ankylosing spondylitis, Tietze syndrome etc. Examination of joint aspirate is important. Once necrotic tissue or pus is aspirated, the possibility of pyogenic infections arises. So tissue diagnosis is imperative at an early stage of the disease and should be done in all cases. Aspirate must be cultured in all cases for confirmation. Regarding tubercular arthritis isolation and culture of the bacilli has proved difficult.<sup>6</sup> So histological diagnosis of chronic granulomatous infection with caseating necrosis should warrant a trial of ATD and this is the protocol followed in most centers in countries with high prevalence of tuberculosis.<sup>1</sup>

Regarding imaging methods, radiological signs are not easy to discern especially in early cases. CT scan and MRI of the site may show osseous destruction of clavicle and sternum but joint destruction is not specific for tubercular infection.

Advanced tubercular arthritis and osteomyelitis in the sternoclavicular joint should be treated with operative debridement and administration of ATD. If the infection is diagnosed at an early stage, treatment with ATD alone may be sufficient.<sup>5</sup>

### Conclusion

We hope that by highlighting the salient features of sternoclavicular TB, this entity may be suspected and diagnosed at an early stage as early institution

of ATD will decrease the morbidity of the joint. This is especially important for residents of endemic zones and travellers. The diagnosis is difficult with radiological investigations including CT scan and MRI not being specific and culture of mycobacterium tuberculosis from joint aspirate being notoriously difficult. Feature of chronic inflammation with granuloma formation on histopathological examination is important clue. A high index of suspicion with smear and histopathological examination and early therapy is the key to success.

### References

1. Tuli SM. Tuberculosis of the Skeletal System: Bones, Joints, Spine and Bursal Sheaths. New Delhi: Jaypee, 1993:121-123.
2. Robert YA, Don GL, et al. Sternoclavicular joint arthritis. *Arthritis and Rheumatism* 1980; 23; 232-239.
3. Martini M. Tuberculosis of Bones and Joints. New York: Springer, Berlin Heidelberg, 1988:149-150.
4. Hunt DD. Problems in diagnosing osteoarticular tuberculosis. *JAMA* 1964;190;95-98.
5. Mandeep DS, Ravi G, Rao SK, et al. Bilateral sternoclavicular joint tuberculosis. *Arch Orthop Trauma Surg* 2000;120;363-365.
6. Ross JJ, Shamsuddin H. Sternoclavicular septic arthritis: Review of 180 Cases. *Medicine* 2004; 83:139-148