

Atypical 'Granulomatosis with Polyangiitis' Presenting with Epistaxis

Sumaiya Akter¹, HAM Nazmul Ahasan², Quazi Tarikul Islam³

Abstract

Granulomatosis with polyangiitis (GPA) is a systemic necrotizing vasculitis involving small and medium-sized blood vessels and granulomatous inflammation of upper and lower respiratory systems and/or renal system. In the limited form of GPA, there is no systemic involvement of disease with sparing of kidneys. Herein, we report a case of 37-year-old male who was diagnosed as ethmoidal polyposis clinically. Ethmoidal tissue biopsy granulomatous angiitis. Diagnosis of GPA was made which was substantiated by antineutrophil cytoplasmic antibody (ANCA) positivity. This was a case of GPA involving only upper respiratory system. The early diagnosis and initiation of treatment are critical for improved survival of patients with GPA. Tissue biopsy is necessary for the diagnosis of GPA.

Keywords: Atypical Wegener's granulomatosis, granulomatosis with polyangiitis, limited GPA.



DOI: <https://doi.org/10.3329/jom.v22i1.51400>

Copyright: © 2021 Akter S. This is an open access article published under the Creative Commons Attribution-NonCommercial-NoDerivatives 4.0 International License, which permits use, distribution and reproduction in any medium, provided the original work is properly cited, is not changed in any way and it is not used for commercial purposes.

Received: 15 December, 2020;

Accepted: 28 December, 2020

Introduction:

Granulomatosis with Polyangiitis (GPA) is the most common Anti-Neutrophil Cytoplasmic Antibody (ANCA) associated vasculitis (previously called Wegener's Granulomatosis) and is a rare multisystem autoimmune disease categorized by a combination of upper airway disease, lower airway disease, and glomerulonephritis.¹ About 11 million cases arise every year, equally distributed amongst males and females.² Patients typically present in the 4th or 5th decade of life with various nonspecific symptoms including hemoptysis, stridor, hoarseness and wheezing.³ Systemic symptoms such as fever, weight loss, myalgia and headache can also be present, usually for several weeks to months.⁴ Studies have found that prompt recognition and intervention is the most important factor in the morbidity and mortality of these patients.⁵ Therefore, early detection (and hence, early treatment) is critical, although it may be difficult if another diagnosis is perceived as more likely on presentation.⁶ This is especially true in the case of GPA, where early treatment leads to clinical remission in up to 75% of patients, but a rapidly progressive disease process and high rate of mortality may occur if diagnosis is delayed.^{3,7}

We report an atypical presentation of GPA in a middle-aged man who presented with only nasal bleeding without any renal involvement. The case highlights the importance of

having a suspicion for GPA in patients with atypical presentations, so that timely diagnosis and initiation of treatment will help in the survival of the patient.

Case History:

A 37 years old male presented with episodic nose bleeding for 1 year, unilateral headache on right side for last 5 months, hearing impairment for 1 month. He developed nasal bleeding for about a year back which was spontaneous, moderate in amount. He went to ENT specialist and diagnosed as a case of ethmoidal polyposis for which he undergone Endoscopic Sinus Surgery. Tissue biopsy of ethmoidal polyp revealed granulomatosis with angiitis. After that operation, he developed depressed nasal bridge & also complained of nasal bleeding during nose blowing and fetching but this time it was very little in amount. He was treated with MMF and steroid. For last 5 months he has been suffering from right sided unilateral headache. When he stood up it became more severe. It was localized in the right hemisphere. It was dull in nature, there was no sensitivity to light or sound & absence of nausea & vomiting. Headache relieved after taking analgesic. Patient also noticed partial hearing impairment in left side for 1 month. There was absence of joint pain, fever, skin rash, shortness of breath or hematuria. He had no urinary complain during his illness.

On clinical examination he had saddle nose deformity, anemia and on nervous system examination there was reduced visual acuity (far) on right side with loss of corneal reflex & diminished sensation of the ophthalmic division on right side and sensory neural hearing loss in the left ear. Other systemic examinations revealed no abnormality.

1. Asstt. Registrar of Medicine, Popular Medical College, Dhaka
2. Professor of Medicine, Popular Medical College, Dhaka
3. Professor of Medicine, Popular Medical College, Dhaka

Corresponding author: Dr. Sumaiya Akter, Asstt. Registrar of Medicine, Popular Medical College, Dhaka

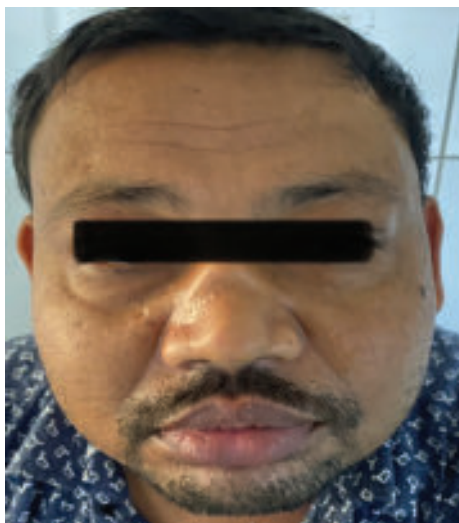

Figure 1: Saddle nose deformity.

His X-Ray PNS OM view revealed maxillary sinusitis with hypertrophied inferior turbinate. (figure-2)

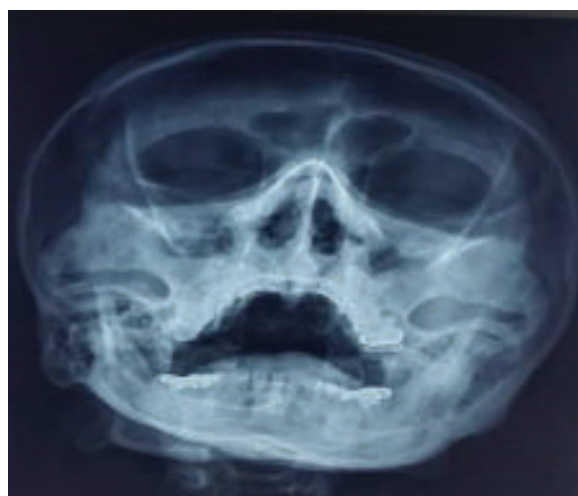

Figure 2: X ray PNS OM view

Among his serological report he had low level of hemoglobin with slightly raised ESR. C-ANCA was positive but his urine RME was completely normal (Table-1) revealing there was no renal involvement.

Table-1

Hemoglobin	11.7 g/dl
MCV	76 fl
MCHC	30 g/dl
Total RBC	5.05 m/cmm
ESR	40 in first hour
Total WBC	13,400/cmm
Platelet	5,68,000/cmm
c-ANCA	34.0 U/ml
Urine RME	normal

CXR P/A revealed fibrous band opacities are seen in right upper zone (Figure 3). Whereas CT guided FNAC from right lung lesion revealed chronic inflammatory lesion.

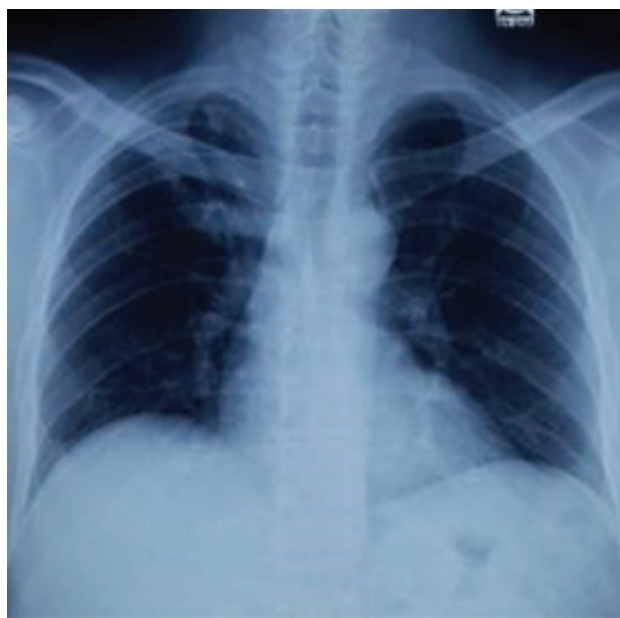

Figure 3: CXR PA view.

CT scan of brain revealed dilatation of ventricular & extra-ventricular CSF spaces which appear age appropriate (figure 4). MRI of brain left middle ear & mastoid region shows hyperintensities on T2W & FLAIR images. Same area shows intermediate signal intensity on T1W1. (figure 5)

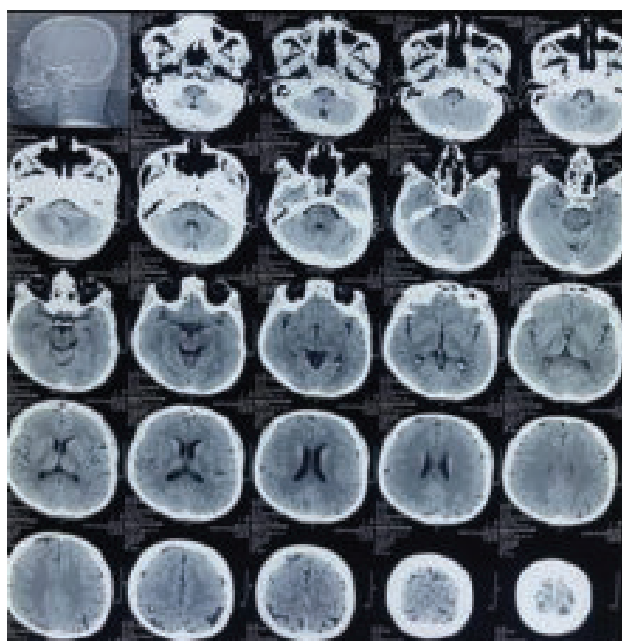


Figure 4: CT scan of brain

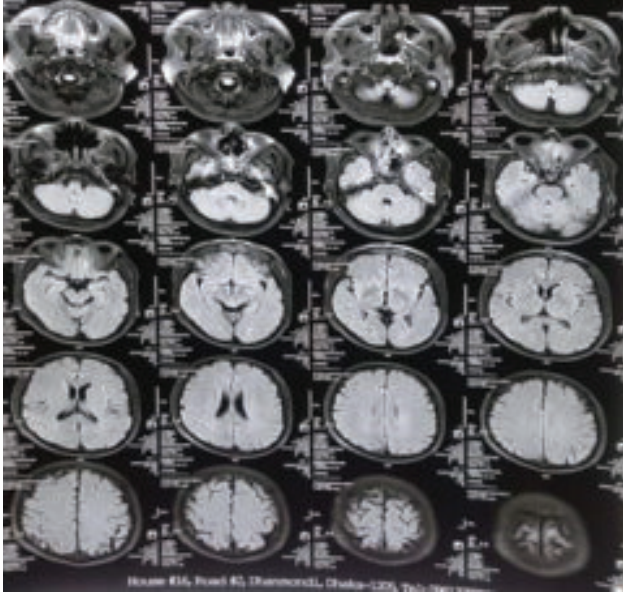


Figure 5: MRI of brain.

Discussion :

Granulomatosis with polyangiitis (GPA), previously known as Wegener granulomatosis, is an idiopathic vasculitis involving medium and small arteries. Among patients with GPA, 80%-95% of patients develop head and neck manifestations during their life⁸ and often otorhinolaryngological symptoms are the presenting and sole signs of the disease. In case of a GPA developing only in Head and Neck region, this condition is called “limited GPA”, differing from more advanced form, named “generalized GPA”, characterized by systemic vasculitis with renal and/or pulmonary involvement and systemic symptoms such as fever and asthenia.

“Limited GPA” phenotype is more likely to affect young female patients, with a recurrent behavior and often non-compliant to medical therapy.⁹ Nasal involvement has long been recognized as a feature of “Limited GPA” and usually starts in the septum area supplied by Kiesselbach plexus and then spreads to the paranasal sinuses.¹⁰

In our case, patient’s symptoms are related to sinonasal region, without systemic involvement. Our patient presented with episodic nasal bleeding, for which he was diagnosed as ethmoidal polyposis, in GPA we usually search for so called triad including upper and lower respiratory tract with glomerulonephritis. As for GPA early diagnosis is crucial, it

is important to keep suspicion of GPA even only with upper respiratory tract involvement, it is not necessary to present the triad. This is a case of limited GPA without lower respiratory tract involvement and renal involvement. If definitive treatment can be initiated at the earliest, thereby improving the survival of patients with GPA. Tissue biopsy forms an essential component for the definitive diagnosis of GPA.

References:

1. Pesci A, Manganelli P (2007) Respiratory system involvement in antineutrophil cytoplasmic-associated systemic vasculitides: clinical, pathological, radiological and therapeutic considerations. *Drugs R D* 8: 25-42.
2. Ntatsaki E, Carruthers D, Chakravarty K, D’Cruz D, Harper L, et al. (2014) BSR and BHPR guideline for the management of adults with ANCA-associated vasculitis. *Rheumatology (Oxford)* 53: 2306-2309. [Crossref]
3. Hoffman GS, Kerr GS, Leavitt RY, Hallahan CW, Lebovics RS, et al. (1992) Wegener granulomatosis: an analysis of 158 patients. *Ann Intern Med* 116: 488-498. [Crossref]
4. Berden A, Göçeroglu A, Jayne D, Luqmani R, Rasmussen N, et al. (2012) Diagnosis and management of ANCA associated vasculitis. *BMJ* 344: e26. [Crossref]
5. Cordier JF, Valeyre D, Guillevin L, Loire R, Brechot JM (1990) Pulmonary Wegener’s granulomatosis. A clinical and imaging study of 77 cases. *Chest* 97: 906-912. [Crossref]
6. Homma S, Suzuki A, Sato K (2013) Pulmonary involvement in ANCA-associated vasculitis from the view of the pulmonologist. *Clin Exp Nephrol* 17: 667-671. [Crossref]
7. Rockall AG, Rickards D, Shaw PJ (2001) Imaging of the pulmonary manifestations of systemic disease. *Postgrad Med J* 77: 621-638. [Crossref]
8. Srouji IA, Andrews P, Edwards C, Lund VJ. Patterns of presentation and diagnosis of patients with Wegener’s granulomatosis: ENT aspects. *J Laryngol Otol.* 2007. 121(7): 653-658. doi: 10.1017/S0022215106005032.
9. Holle JU, Gross WL, Holl-Ulrich K, et al. Prospective long-term follow-up of patients with localised Wegener’s granulomatosis: Does it occur as persistent disease stage? *Ann Rheum Dis.* 2010. 69(11): 1934-1939. doi: 10.1136/ard.2010.130203
10. Lloyd G, Lund VJ, Beale T, Howard D. Rhinologic changes in Wegener’s granulomatosis. *J Laryngol Otol.* 2002. 116(7): 565-569. doi: 10.1258/002221502760132737