

## Case Reports

### Pulmonary Alveolar Microlithiasis

B.GAYATHRI,<sup>1</sup> S KEERTHIVASAN<sup>2</sup>

#### Abstract

*Pulmonary alveolar microlithiasis (PAM) is a rare idiopathic disease characterized by microliths in the lungs which is usually asymptomatic and often diagnosed incidentally. Here we discuss a case of a young woman while evaluating for surgery presented with an abnormal chest X ray of bilateral diffuse nodular opacities. Patient was completely asymptomatic. High resolution CT scan revealed crazy paving pattern, black pleura sign, and pleural calcification typical findings of pulmonary alveolar microlithiasis. CT guided lung biopsy confirmed the diagnosis.*

**Keyword:** Black pleura sign, calcium deposition, crazy paving pattern, pulmonary alveolar microlithiasis

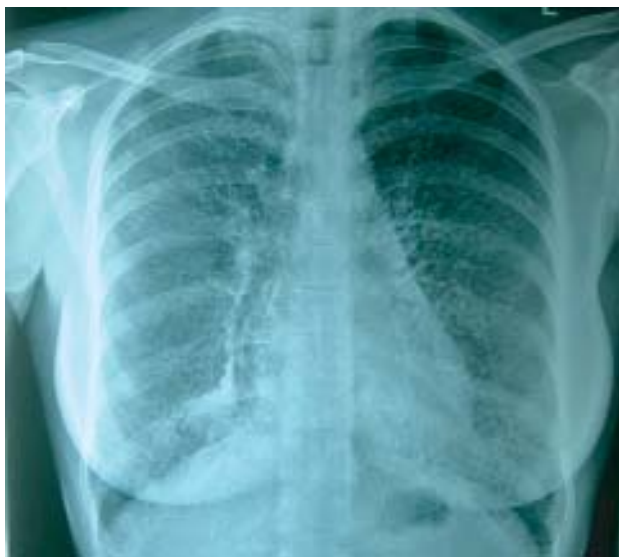#### Introduction

Pulmonary alveolar microlithiasis (PAM) is a rare idiopathic disease characterized by microliths in the alveoli, and was first described by Friedrich in 1856 and then by Harbitz in 1918.<sup>1,2</sup> In 1957, Sosman emphasized that 50% of the cases were familial.<sup>3</sup> The autosomal recessive inheritance was shown in later reports, with siblings usually being affected.<sup>4,5</sup> Mariotta S et al review report on 576 cases has shown that the etiology of the disease is still unknown and it is widespread throughout the world.<sup>6</sup> We present a case of 23 year old female incidentally presented with an abnormal chest radiograph diagnosed as pulmonary alveolar microlithiasis.

#### Case report

A 23 year old female diagnosed as acute appendicitis planned for laparoscopic appendectomy underwent routine investigations. Incidentally her chest radiograph (fig.1) showed diffuse fine nodular opacities throughout the lung fields for which the patient was referred to us. However, the patient was totally asymptomatic and had no respiratory complaints. The nodular opacities were sharply defined, discrete and showed greater involvement of lower compared to upper zones. Systemic examination and routine laboratory tests were unremarkable. Spirometry showed normal ventilatory function. High resolution CT scan(HRCT) of lung revealed a crazy paving pattern<sup>7</sup>(fig.2) with black pleura sign(fig.3) and pleural

calcification.<sup>8</sup> In fiberoptic bronchoscopy, the endobronchial appearance was normal. Bronchial lavage fluid was examined for tuberculosis and found as negative. She underwent CT guided biopsy of the lung tissue and the histopathological report came as calcium deposition in the alveoli which confirmed the diagnosis of pulmonary alveolar microlithiasis. In view of the familial association of this disease, sister and the brother of our patient (21 and 19 years old, respectively) were invited for chest radiographies. No abnormalities were detected in the X-rays of the siblings.

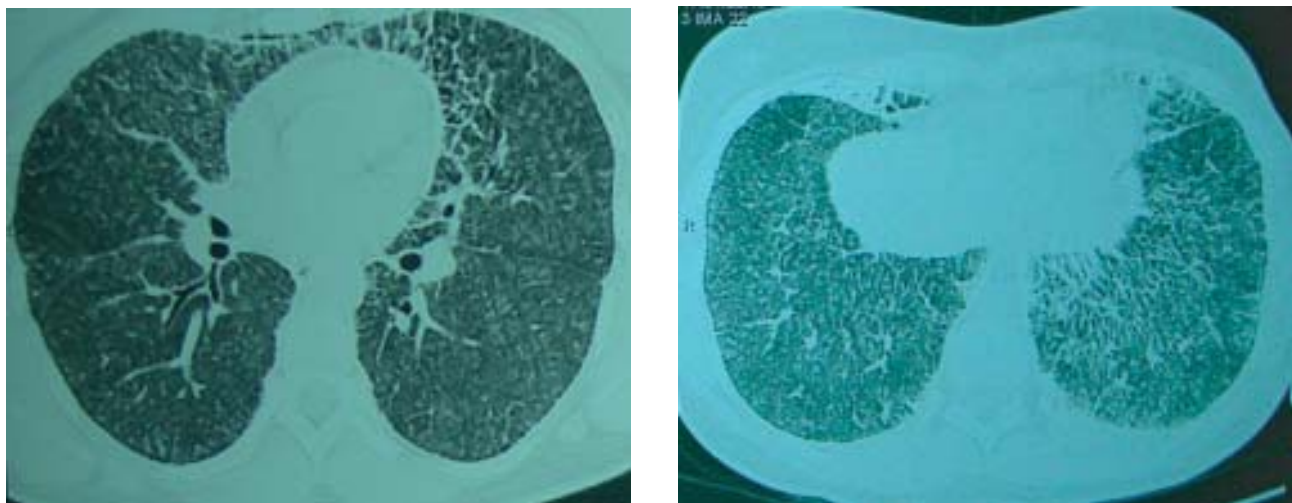


**Fig-1.** Bilateral diffuse nodular opacities

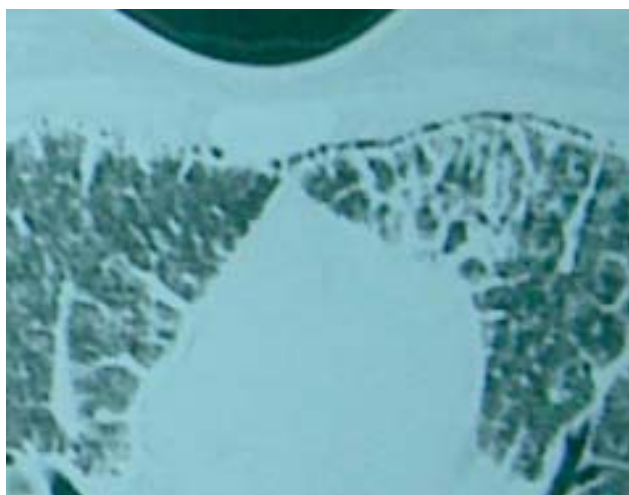1. Assistant Professor, PSG Medical College, Coimbatore, Tamil Nadu, India.

2. Consultant Pulmonologist, KG hospital Pvt Ltd, Coimbatore, Tamil Nadu, India.

**Correspondence:** Dr. B. Gayathri, No.55, Ashok Nagar II Avenue, M.K.P Colony, Ganapathy, Coimbatore, Tamilnadu – 641006. E-mail : drgayukv@yahoo.co.in



**Fig.-2:** Crazy paving pattern



**Fig.-3:** Black pleura sign

### Discussion

Pulmonary alveolar microlithiasis (PAM) is a rare diffuse lung disease characterized by the accumulation of calcium phosphate microliths within the alveoli.<sup>3</sup> Disease is prevalent amongst family units with a high rate of consanguinity among the parents of affected individuals suggesting the hypothesis of the role of genetic factors in causing PAM.<sup>9,10,11</sup> Recently, Corutctal et al have identified the gene mutation responsible for the disease as SLC34A2 (the type IIb sodium phosphate co-transporter gene), which is involved in phosphate homeostasis in several organs, including the lung surface, readily apparent on HRCT.<sup>12</sup>

Asymptomatic cases, even with extensive radiographic involvement, are often discovered incidentally. Cough

and dyspnoea are the most common presenting symptoms and usually occur late in the course of the disease. Normal or mild restrictive pulmonary physiology may be present in the asymptomatic individual.<sup>13</sup> With progressive disease, severe lung restriction may ensue with impairment of the diffusing capacity and gas exchange abnormalities. Cor pulmonale frequently occurs late in the course of the disease, after symptoms of respiratory insufficiency have been present for several years.<sup>14</sup> Right ventricular hypertrophy has been a frequent finding in postmortem examination.<sup>15</sup> The chest radiograph shows bilateral, sand-like, micronodular calcified densities known as microliths or calcispherites, which are usually less than 1 mm in diameter. They appear concentrated in the lower two-thirds of the lung, often obliterating the diaphragmatic, mediastinal, and cardiac borders. The greater radiographic density at the lung bases is likely due to the larger lower lobe volumes rather than selective predisposition.<sup>3</sup> Other findings that may be seen include bullae in the lung apices, a zone of increased lucency between the lung parenchyma and the ribs (known as a black pleural line), and pleural calcification.<sup>7</sup> CT and the <sup>99m</sup>Tc diphosphonate scan have been used to confirm diffuse calcification in PAM. CT scan of the chest reveals a diffuse infiltrative pattern, and the <sup>99m</sup>Tc diphosphonate scan reveals increased uptake of the isotope throughout both lungs.<sup>16,17</sup> The predominant high resolution HRCT finding is the presence of micronodular calcifications primarily located along the bronchovascular bundles and subpleural regions and peribular distribution.<sup>18</sup> Pulmonary function studies are initially normal. In about 30% of the patients, a mild restrictive defect evolves. The most common findings

are decreased vital and total lung capacity, normal residual volume/total lung capacity ratio and decreased diffusing capacity.<sup>19</sup> The standard chest radiograph and CT, with results for PAM, are enough to diagnose the disease, even if microscopic evidence of the microliths in the alveoli was obtained in most cases.<sup>20,21</sup> Microliths in the sputum and bronchoalveolar lavage are not diagnostic because patients with chronic obstructive pulmonary disease and tuberculosis expectorate microliths as well.<sup>22</sup> In histologic examination of open lung or transbronchial biopsies, the lesions of PAM consist of intraalveolar calcispherites, which represent laminated calcium phosphate concretions. There is no known therapy for PAM. However there was a single report<sup>23</sup> where radiologic lesions due to PAM were found to be reduced after treatment with disodium etidronate.<sup>23</sup> Bilateral lung transplantation is a viable option for advanced cases. It has been reported that PAM cases followed after transplantation did not show evidence of recurrence.<sup>24,25</sup>

### Conclusion

The present case illustrates that in diffuse parenchymal lung disease particularly in a young asymptomatic patient pulmonary alveolar microlithiasis should be considered in the differential diagnosis. Scrutiny of the long-term follow-up data of PAM patients reveals that the prognosis for PAM is poor. The establishment of an effective treatment, which is not yet available, is mandatory.

**Conflict of Interest:** None

### References:

- Friedrich N. Corpora amylacea in den Lungen. Arch Pathol Anat 1856; 9: 613-8
- Harbitz F. Extensive calcifications of the lungs as distinct disease. Arch Intern Med 1918; 21: 139-46
- Sosman MC, Dodd GD, Jones DW, Pillmore GU. The familial occurrence of pulmonary alveolar microlithiasis. AJR 1957; 77:947-1012
- Kanra G, Tanyol E, Göçmen A, et al. Pulmonary alveolar microlithiasis (a case report). Turk J Pediatr 1988;30: 61-7
- Coşkunsel M, Penyiđit A, Büyükbayram H, et al. Familyer pulmoner alveoler mikrolitiazis. Solunum Hastalýklarý 1997; 8: 475-83
- Mariotta S, Ricci A, Papale M, De Clementi F, Sposato B, Guidi L, Mannino F. Pulmonary alveolar microlithiasis: report on 576 cases published in the literature. Sarcoidosis Vasc Diffuse Lung Dis. 2004 Oct; 21(3):173-81
- Johkoh T, Itoh H, Müller NL, Ichikado K, Nakamura H, Ikezoe J et al. Crazy paving appearance at thin-section CT. Spectrum of disease and pathologic findings. Radiology 1999; 211:155-60
- Pulmonary alveolar microlithiasis. In: Fraser RS, Müller NL, Colman N, Pare PD, Eds. Diagnosis of Diseases of the Chest. 4th Ed. Philadelphia. W.B. Saunders Company; 1999, p. 2719-22
- Sears MR, Chang AR, Taylor AJ. Pulmonary alveolar microlithiasis. Thorax 1971; 26: 704
- Stamatis G, Zerkowski HR, Doetsch N, Greschuchna D, Konietzko N, Reidermeister JC. Sequential bilateral lung transplantation for pulmonary alveolar microlithiasis. Ann Thorac Surg 1993; 56: 972
- Lauta VM. Pulmonary alveolar microlithiasis: an overview of clinical and pathological features together with possible therapies. Respir Med 2003; 97: 1081-1085
- Corut A, Senyigit A, Ugur SA, Altin S, Ozcelik U, Calisir H et al. Mutations in SLC34A2 cause pulmonary alveolar microlithiasis and are possibly associated with testicular microlithiasis. Am J Hum Genet 2006; 79: 650-656
- Shah MS, Nanavati KJ, Airon A, Shah RR, Joshi BD. Case report -pulmonary alveolar microlithiasis. Ind J Radiol Imag 2003;13(3):277-9
- Barbolini G, Rossi G. Pulmonary alveolar microlithiasis. N Engl J Med 2002; 347(1):69-70
- O'Neill RP, Cohn JE, Pellegrino ED. Pulmonary alveolar microlithiasis - a family study. Ann Intern Med 1967; 67: 957-67
- Winzelberg G, Boller M, Socos M. CT evaluation of pulmonary alveolar microlithiasis. J Comput Assist Tomogr 1984; 8: 1029-30
- Garty I, Giladi N, Flatau E. Bone scintigraphy in two siblings with pulmonary alveolar microlithiasis. Br J Radiol 1985; 58: 763-6
- Cluzel P, Grenier P, Bernadac P, Laurent F, Picard JD. Pulmonary alveolar microlithiasis: CT findings. J Comput Assist Tomogr 1991; 15: 938-42
- Fuleihan FJD, Abboud RT, Balikian JP, Nucho CKN. Pulmonary alveolar microlithiasis: lung function in five cases. Thorax 1969; 24:84-90
- Artvinli M, Özesmi M, Barýb Ý. Pulmoner Alveoler Mikrolithiazis. Hacettepe Týp/ Cerrahi Bülten: 1972;5(4):407-11
- Sicenicca T, Fiehler PC. A patient with palpitation and bilateral pulmonary infiltrates. Chest 2001;119: 1951-2
- Palombini BC, da Silva Porto N, Wallau CU, Camargo JJ. Bronchopulmonary lavage in alveolar microlithiasis. Chest 1981;80:242-3
- Ozcelik U, Yalcin E, Ariyurek M, Ersoz DD, Cinel G, Gulhan B et al. Long-term results of disodium etidronate treatment in pulmonary alveolar microlithiasis. Pediatr Pulmonol.2010 May;45(5):514-7
- Stamatis G, Zerkowski HR, Doetsch N, Greschuchna D, Konietzko N, Reidemeister JC. Sequential bilateral lung transplantation for pulmonary alveolar microlithiasis. Ann Thorac Surg 1993;56: 972-5
- Edelman J, Bavaria J, Kaiser LR, Litzky LA, Palevsky HI, Kotloff RM. Bilateral sequential lung transplantation for pulmonary alveolar microlithiasis. Chest 1997; 112: 1140-4