

Clinical Images

Retained Foreign Body in the Pleura

PULAK KUMAR JANA¹, SIBES KUMAR DAS¹, RAJAT BANDYOPADHYAY², TAPAN DAS BAIRAGYA¹

A 48-year-old non-smoker female was referred to our chest clinic for preoperative pulmonary evaluation for subtotal thyroidectomy for thyroid carcinoma, as she had an abnormal chest radiograph.

Her chest x ray showed left sided pleuroparenchymal fibrosis and some air pockets with a tube-like structure in the left hemithorax (Fig-1). On interrogation she revealed that she had an empyema on the left side 15 years back which was treated with intravenous antibiotics and a small bore intercostal drainage catheter. Accidentally the tube entered

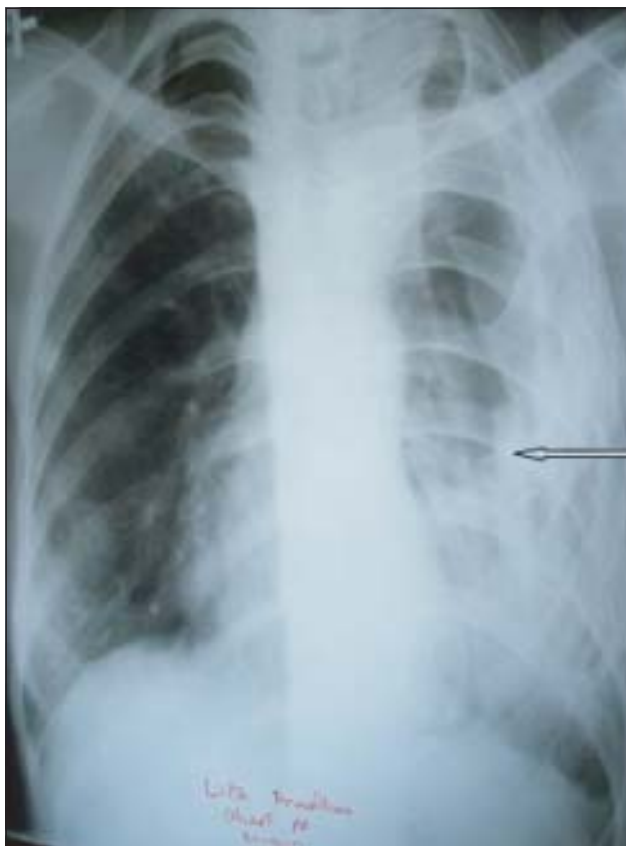


Fig.-1: Chest x ray (PA) view showing pleura-parenchymal fibrosis with encysted pneumothorax and a tube-like structure (arrowhead) in left hemithorax.

into the pleural space. Subsequent attempt of removal of the tube from left pleural space by thoracotomy was unsuccessful due to extensive pleuroparenchymal adhesion. CT Scan thorax done at our clinic showed left sided pleuroparenchymal fibrosis with persistent localised pneumothorax and confirmed the presence of retained catheter (Fig-2) in the left pleural space.

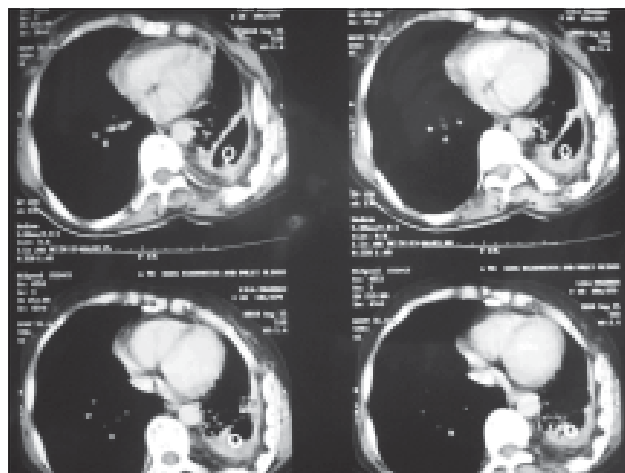


Fig.-2: CT Thorax showing retained drainage catheter in left pleura.

As the patient was asymptomatic and previous attempt of removal of the tube was unsuccessful she was advised against repeat thoracotomy.

A small bore catheter may be retained within the pleural space following pleural drainage.¹ Every attempt should be done to remove the catheter, but if it is small, blunt, inert or asymptomatic, it may be left alone.²

References:

1. Retained foreign body following pleural drainage with a small-bore catheter. Paddle A, Elahi M, Newcomb A. *Gen Thorac Cardiovasc Surg* 2010; 58: 42-4
2. Weissberg D, Weissberg - Kasav D. Foreign bodies in Pleura and chest wall *Ann Thorac Surg* 2008;86:958-61

¹ Department of Respiratory Medicine, North Bengal Medical College West Bengal, India

² Department of Radiotherapy, North Bengal Medical College, Darjeeling, West Bengal, India

Correspondence - Sibes Kumar Das, Email- sibesdas67@gmail.com