

Case Report

Idiopathic Pericarditis Leading to Hemorrhagic Pericardial Effusion- A Case Report and Review

Forest Riekhof BS¹, Farzana Hoque¹

Abstract

Pericardial effusion presentation is a large spectrum that can vary from asymptomatic to cardiac tamponade. It is a relatively common syndrome and has a diverse set of etiologies including infections, malignancy, radiation/iatrogenic, pericardial injury, metabolic disturbances, endocrine disease, connective tissue disease, autoimmune disorders, trauma, or idiopathic. Pericardial drainage is recommended in most large pericardial effusions or those causing cardiac tamponade. Pericardial fluid can be either purulent, serous, serosanguinous, or hemorrhagic. In the case of hemorrhagic effusion, the common etiologies include malignancy, iatrogenic, and tuberculosis (in endemic regions). Large hemorrhagic pericardial effusions resulting from idiopathic (presumed viral) pericarditis are rare but possible. We present an interesting case of a woman with a large hemorrhagic pericardial effusion presenting as subacute cardiac tamponade caused by idiopathic pericarditis in the setting of known malignancy. This report aims to increase awareness about pericarditis as a potential cause of significant hemorrhagic pericardial effusions, rather than solely attributing them to malignancy.

Keywords: Idiopathic Pericarditis, Pericardial Effusion, Pericarditis, Cardiac Tamponade

DOI: <https://doi.org/10.3329/jom.v25i1.70533>

Copyright: © 2024 Forest Riekhof BS. This is an open access article published under the Creative Commons Attribution-Non Commercial-No Derivatives 4.0 International License, which permits use, distribution and reproduction in any medium, provided the original work is properly cited, is not changed in any way and it is not used for commercial purposes.

Received: 12.8.2023;

Accepted: 1.12.2023

Introduction

Pericardial effusion presentation is a large spectrum that can vary from asymptomatic to cardiac tamponade. It is a relatively common syndrome and has a diverse set of etiologies including idiopathic, infectious, inflammatory disorder, malignancy, and more.¹ Idiopathic pericardial effusion is the most frequent cause in the United States, but large idiopathic effusions causing cardiac tamponade are comparatively rare. Pericardial effusions can be hemorrhagic, which is often the result of malignancy or tuberculosis (in endemic areas).² We present an interesting case of a woman with massive hemorrhagic pericardial effusion presenting as subacute cardiac tamponade caused by idiopathic pericarditis in the setting of known malignancy.

Case Report

A 69-year-old woman with a history significant for stage IV invasive ductal carcinoma of the right breast (ER+, PR+,

HER2-) previously treated with letrozole and Palbociclib presented with abdominal and chest pain. Her symptoms began two weeks prior to presentation when she was seen for chest pain and diaphoresis at an outside hospital. ECG at that time showed sinus rhythm with inferior ST elevations and PR depression, interpreted as early repolarization. Basic labs, serial troponins, and chest X-rays were within normal limits at the time. She was treated with pantoprazole, famotidine, meclizine, Ketorolac, GI cocktail, and 1 L fluid bolus and reported symptomatic improvement. She was discharged with cardiology follow-up, who ordered a stress echocardiogram which had not yet been done. 2 weeks later she developed new-onset abdominal pain, constipation, dyspnea on exertion, and fatigue causing her to present to our hospital. She denied chest pain, palpitations, orthopnea, fevers, chills, recent illness, or exposure to sick contacts. The physical exam was positive for Beck's triad (decreased blood pressure, increased jugular venous pressure, and muffled heart sounds). Vital signs revealed tachycardia with heart rate in the 110s, tachypneic to the 30s, afebrile, hypotensive with systolic blood pressure in the 90s, and saturating 96% on room air. EKG showed sinus tachycardia. Pertinent labs included leukocytosis with a WBC of 16.5, elevated lactic acid to 3.27, and troponins within normal limits. A chest x-ray was ordered showing a

1. Saint Louis University School of Medicine, St. Louis, Missouri, USA.

Corresponding author: Dr. Farzana Hoque, Associate Professor of Medicine, Saint Louis University School of Medicine, St. Louis, Missouri, USA. E-mail: farzanahoquemd@gmail.com

massive pericardial effusion and small bilateral pleural effusions (*Image 1*). CT of her abdomen showed no small bowel obstruction but did show a massive pericardial effusion plus ascites (*Image 2*).

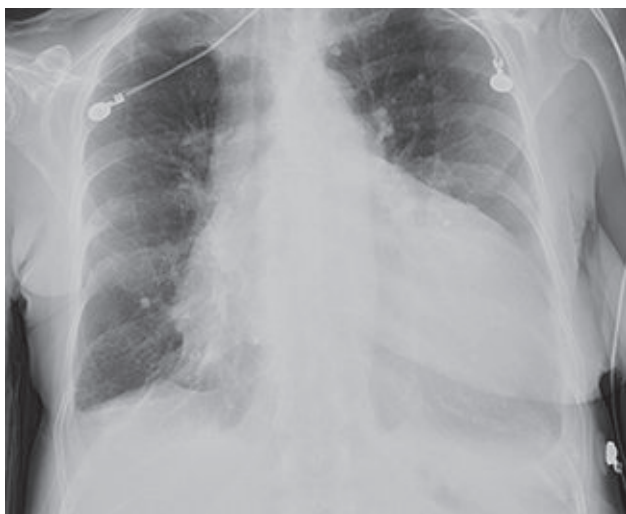

Figure 1: Chest X-ray revealing large pericardial effusion and small bilateral pleural effusions.

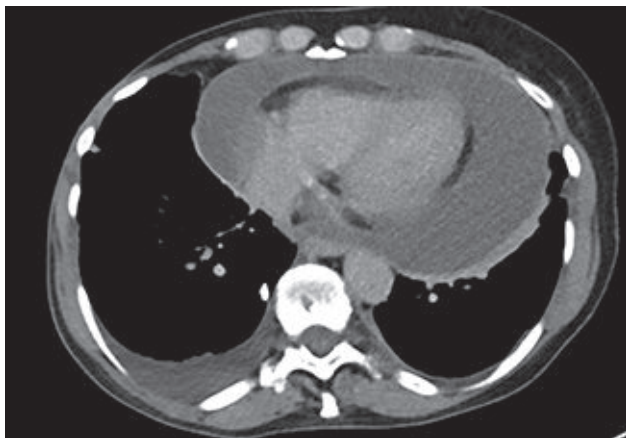

Figure 2: CT abdomen showing large circumferential pericardial effusion with fluid at the apex measuring 3.5cm

The echocardiogram revealed a large circumferential pericardial effusion with evidence of cardiac tamponade including right atrial systolic collapse and focal strands; as well as a dilated IVC and hepatic veins (*Image 3*). The patient was admitted to the ICU for further management of cardiac tamponade. Etiology at the time was unclear, thought to be most likely secondary to malignancy. Initial treatment included fluid resuscitation, pericardiocentesis fluid analysis, and further labs including normal TSH. Pericardiocentesis was done with a pericardial drain placed for further drainage. The procedure revealed a large hemorrhagic pericardial effusion draining 900 mL of red fluid. No pericardial tissue was taken for analysis. Pericardial fluid analysis revealed

an exudative fluid consisting predominately of red blood cells with a normal white blood cell differential. The sample did not show evidence of malignant cells. The drain put out another 200 mL of bloody fluid over the next 24 hours and then tapered off over several days. The final diagnosis was idiopathic pericarditis causing a large hemorrhagic pericardial effusion. Repeat ECHO at that time showed resolution of her pericardial effusion. Her pericardial drain was removed, and she was discharged on NSAIDs and colchicine with cardiology follow-up.

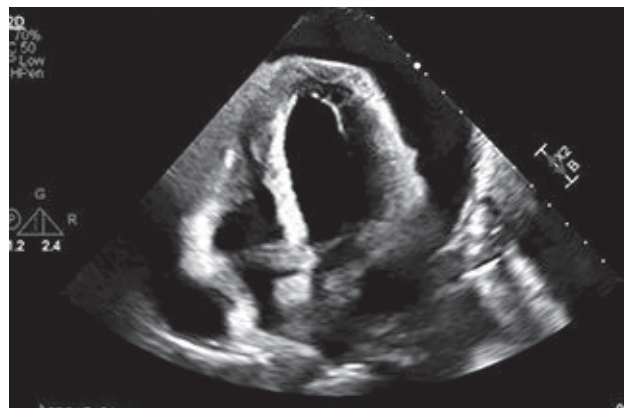


Figure 3: ECHO done prior to pericardiocentesis showing large circumferential pericardial effusion with compression of right atrium indicative of early cardiac tamponade.

Discussion

Pericardial effusion is thought to occur when there is increased production of fluid in the pericardial sac or decreased absorption, which is frequently the result of an insult that causes inflammation. Presentation for pericardial effusion is a large spectrum that can vary from asymptomatic to cardiac tamponade. Pericardial effusion is generally diagnosed with echocardiography due to suspicion based on clinical syndrome or incidental evidence from other imaging. The pericardial effusion can be classified by size on two-dimensional echocardiography by assessing the end-diastolic distance between the epicardium and pericardium: small (<10 mm), moderate (10–20 mm), large (>20 mm). Determining the etiology of the effusion can be challenging which can result from a wide range of etiologies including various infections by viruses, bacteria (especially *Mycobacterium tuberculosis*), and fungi; malignancy, radiation, pericardial injury (post-myocardial infarction), metabolic disturbances, endocrine disease, connective tissue disease, autoimmune disorders, trauma, or idiopathic.¹ Using a patient's history of present illness, past medical history, and physical exams can give clues to the cause for many

patients. Our patient's presentation was not typical of pericarditis as she did not have chest pain at the time of presentation, lacked a friction rub due to her effusion, and her EKG was unremarkable. Laboratory testing of the pericardial fluid or pericardium itself can facilitate the diagnosis of infection or malignancy. However, testing for a broad array of infectious etiologies can be cumbersome and unfruitful, as it may not alter treatment, such as is the case for viral etiologies. Pericardial drainage is recommended in all large pericardial effusions, as was the case with our patient. Pericardial fluid can be either purulent, serous, serosanguinous, or hemorrhagic. In the case of hemorrhagic effusion, such as in our patient, malignancy, and tuberculosis (in endemic regions) become a more likely etiology, however, the possibilities remain broad. If the patient recently underwent a procedure, iatrogenic causes are also likely. Another iatrogenic cause of hemorrhagic effusions includes drugs such as anti-coagulants, anti-neoplastic, and immunosuppressants.^{3,4} Sometimes patients' initial presentation for malignancy can be pericardial effusion. In patients with breast cancer who develop pericardial effusion, a significant number of cases are due to malignancy.⁵ However, the pericardial fluid analysis did not show malignant cells for our patient. Our patient also had no evidence of cardiac injury or recent procedures that would lead us to believe this was secondary to post-myocardial infarction inflammation, which is also associated with hemorrhagic effusions. There have been several reports of hemorrhagic pericardial effusion related to COVID-19 infection. Viral pericarditis (usually coxsackievirus B and now SARS-CoV-2) is a less common, but important contributor to hemorrhagic pericardial effusions.⁶ Hemorrhagic pericardial effusion treatment should be prompt due to the risk of recurrence and constrictive pericarditis. Definitive treatment of the pericardial effusion should be based on the etiology of the disease.⁷ If the cause of the effusion is not viral, then therapy appropriate to the cause should be selected. If the effusion is thought to be viral pericarditis, then treatment will focus on pericarditis, including the use of NSAIDs and colchicine.⁸ If NSAIDs and colchicine fail, then steroids can be considered until resolution or normalization of CRP. If pericardiocentesis is needed due to the size of the effusion or tamponade features, this should come first.

Conclusion

Pericardial effusion is a relatively common syndrome and has a diverse set of etiologies including idiopathic, infectious, inflammatory disorder, and malignancy. Treatment of large pericardial effusions will often require pericardiocentesis. Hemorrhagic pericardial effusions are often the result of malignancy, tuberculosis, or iatrogenic; but viral etiologies should also be considered, as was this patient. Hemorrhagic effusions need aggressive treatment due to the risk of recurrence and constrictive pericarditis. Treatment after pericardiocentesis is based on the etiology of pericardial effusion. For viral (or idiopathic) pericarditis, NSAIDs and colchicine remain the primary treatment.

References

1. Azarbal A, LeWinter MM. Pericardial Effusion. *Cardiol Clin.* 2017;35(4):515-524.
2. Vakamudi S, Ho N, Cremer PC. Pericardial Effusions: Causes, Diagnosis, and Management. *Prog Cardiovasc Dis.* 2017;59(4):380-388.
3. Khachatryan A AJM, Chow R D, et al. Late-Onset Hemorrhagic Pericardial Effusion and Cardiac Tamponade Associated With Immune Checkpoint Inhibitors: Case Report and Literature Review. *Cureus.* 2023;15(8).
4. Nasir SA, Babu Pokhrel N, Baig A. Hemorrhagic Pericardial Effusion From Apixaban Use: Case Report and Literature Review. *Cureus.* 2022;14(10):e30021.
5. Ilerhunmwuwa N, Sedeta E, Wasifuddin M, et al. Cardiac Tamponade in Patients With Breast Cancer: A Systematic Review. *Cureus.* 2022;14(12):e33123.
6. Kermani-Alghoraishi M, Pouramini A, Kafi F, Khosravi A. Coronavirus Disease 2019 (COVID-19) and Severe Pericardial Effusion: From Pathogenesis to Management: A Case Report Based Systematic Review. *Curr Probl Cardiol.* 2022;47(2):100933.
7. Adler Y, Charron P, Imazio M, et al. 2015 ESC Guidelines for the diagnosis and management of pericardial diseases: The Task Force for the Diagnosis and Management of Pericardial Diseases of the European Society of Cardiology (ESC) Endorsed by: The European Association for Cardio-Thoracic Surgery (EACTS). *Eur Heart J.* 2015;36(42):2921-2964.
8. Imazio M, Bobbio M, Cecchi E, et al. Colchicine in addition to conventional therapy for acute pericarditis: results of the Colchicine for acute Pericarditis (COPE) trial. *Circulation.* 2005;112(13):2012-2016.