



Review Article

Operative complications of urogenital tract during repair of anorectal malformation (ARM) in boys: A review

Hasan MS¹, Rahman A²

Abstract

Despite advancements in reconstructive surgery and a growing understanding of anorectal malformation (ARM) anatomy, boys still commonly experience urinary tract injuries after ARM reconstruction. These injuries include postoperative rectourethral fistula (RUF), urethral stricture or stenosis, bladder dysfunction or injury, prostatic injury, ureteral injury, and vas & seminal vesicle injury. Some of these injuries are immediately apparent during surgery, while others present later in follow-up. This article details the causes, symptoms, management, and prevention protocols for urogenital tract injuries during ARM reconstruction in boys.

Keywords: Anorectal malformation, PSARP, Recto urinary fistula, Urinary tract injury

Introduction

Anorectal malformation (ARM) affects approximately 1 in 5000 live births worldwide¹. While the exact incidence of ARM in low-middle-income countries (LMICs) is unknown, it is believed to be higher than in high-income countries due to over 90% of congenital anomalies patients being in LMICs². Studies from Bangladesh have reported a higher prevalence of ARM among neonatal surgical conditions³⁻⁵. There is a 1.5 times higher incidence of boys being affected compared to girls in ARM¹.

The surgical correction is individualized according to the type of malformation. However, the introduction of the posterior sagittal anorectoplasty (PSARP) by Pena and Devries in 1982 revolutionized the surgical approaches to the management of ARM. Before that, various pull-through procedures were in practice emphasizing the preservation of puborectalis for continence. But pulling the intestine blindly through the retro urethral space was associated with damage to the external sphincter and urethra, leading to a poor outcome. For a positive outcome, the pulled-through bowel can be placed using the posterior sagittal approach, which provides ample exposure and direct visualization of the sphincteric muscle complex.^{6,7}

Georgeson et al. introduced laparoscopy-assisted anorectoplasty (LAARP) in 2000 to preserve the levator ani muscle to achieve better functional outcomes. Since then, it has become the first choice in some centers though the outcome compared to PSARP is still debatable⁸. Bischoff et al. combined both techniques in patients with higher fistula, e.g., recto bladder neck and rectovesical fistula for better visualization of the fistula with minimal access⁹. Nevertheless, both these techniques underwent several modifications to avoid complications and to achieve optimal bowel function⁸⁻¹².

Despite this advancement in management, a significant proportion of children with ARM suffer from complications of definitive reconstructive surgery. Most of these complications require a second and/or subsequent operation, which increases the patient's

1. Dr. Md Samiul Hasan, Assistant Professor (Paediatric and neonatal surgery), Bangladesh Shishu Hospital and Institute.
2. Dr. Ashrarur Rahman, Professor (Paediatric and neonatal surgery), Bangladesh Shishu Hospital and Institute.

Correspondence to : Dr. Md Samiul Hasan Assistant Professor (Paediatric and neonatal surgery) Bangladesh Shishu Hospital and Institute. Room-333, Ward 5, Block-A Mobile: 01712886034 mail: samiulo45@gmail.com

Accepted: 24, June 2023

Published: July 2023

pain and suffering and produces a poorer final outcome. In boys, urinary complications are more frequent as the terminal part of the bowel shares a common wall for some distance or remains very close to the urinary tract. Separation of these two tracts inherits the potential of injuring either one. Complications may arise if there is insufficient identification of abnormal anatomy before surgery and limited experience with the procedure. Numerous studies reported these complications¹³⁻¹⁶. This article aims to review the types of urinary complications of ARM reconstruction, the possible mechanism of their occurrence, approaches to their diagnosis and management, and prevention strategies.

Post-operative recto urinary fistula (RUF)

Recto urinary fistula (RUF) is the most frequent type of ARM in male children. In more than 80% of boys with ARM, the rectum terminates in the urinary tract¹⁰. Depending on the position of the fistula, it could be recto bulbar urethral, recto prostatic urethral, or rectovesical fistula. Despite the advancement in understanding surgical anatomy and surgical techniques, resection and repair of RUF are still challenging. Postoperative RUFs are of three types-

1. Persistent RUF- in which the surgeon missed the original fistula during reconstruction. The main reason for this complication is the failure to delineate the fistula in a distal cologram. It mostly occurs in patients with recto bulbar urethral fistula, otherwise considered a less complicated case^{13,16-18}. Huang et al. reported a large series of persistent RUF results after primary PSARP at neonatal age. Delineation of the RUF might be difficult at neonatal age, though other series of primary PSARP didn't report this complication¹⁸⁻¹⁹.
2. Recurrent RUF- where the surgeon resected and repaired the fistula during the primary reconstruction, but it reappeared. Inadequate mobilization of the rectum leads to ischemic necrosis of the rectal wall. Additionally, injury to the anterior rectal wall, excessive use of electrocautery, and or superimposed rectal and urethral suture lines contribute to the recurrence of RUF¹³⁻¹⁷.
3. Acquired RUF-when a urethral injury remains unrecognized during the primary repair. It usually occurs in boys with perineal fistula when a primary

reconstruction is attempted without a Foley catheter in the urethra. Injuring the urethra during a PSARP is another mechanism¹³⁻¹⁷.

Most of these patients present with the passage of urine through neo anus after ARM correction. Complete voiding may occur through the neoanus in patients with wide fistula. Patients may even present later in life with infertility due to the passage of semen through the anus during ejaculation. Many patients also have urethral stenosis or stricture, anal stenosis, and mislocation of the neoanus^{16,17}. A careful examination under anesthesia can confirm the presence and position of RUF. A catheter or a stent can be passed through the fistula. It can be done manually by placing a finger in the rectum or with the help of a cystoscope. This maneuver helps the surgeon to locate the fistula and its distance from the anus, which in turn helps in the planning of surgery. A micturating cystourethrogram (MCU) and a colostogram may also help diagnose post-operative RUF^{16,17}.

The goals of surgical management in this scenario are complete separation of the rectum and the urinary tract, prevention of urinary injury, and preservation of the fecal and urinary continence. Several surgical approaches have been reported to deal with this bothersome complication. Levitt et al. always prefer a redo PSARP, complete separation of the urethra and rectum, repair of the urethra, and reposition of the rectum within the muscle complex^{13,17}.

Huang et al. described a trans-anal approach to resect post-operative RUFs within 3 cm from the anal verge, normally positioned anus, and without rectal or urethral obstruction. The success rate was 93.5%. The advantages of this procedure include limited disturbance of the sphincter mechanism to preserve continence and minimal dissection of the perineum to avoid anal stenosis. Out of 31 patients in this series, one boy developed urethral stenosis, and one boy developed urethral diverticulum. Both were managed conservatively. The authors recommended three characteristics of RUF for this approach- 1. Persistent RUF without scar in the surrounding tissue, 2. Low-lying fistula, within 3 cm from the anal verge, and 3. Normally positioned anus¹⁸.

Other approaches reported include pull-through of the anterior rectal wall proximal to the fistula, simple repair of fistula through the anal route, Abdomino perineal repair of the fistula, and posterior approach with variable success rate¹⁷.

The posterior sagittal approach, originally described as the definite reconstructive procedure of ARM with RUF, has been reported to achieve successful outcomes in most series. The benefits of this approach are excellent exposure of the whole anatomy, complete separation of the rectum from the urethra, mobilization of the rectum to leave a healthy rectal wall over the urethra, correction of associated anal pathology (e.g., stenosis, mislocation) and urethral stenosis but one should expect dense scar and adhesion from the previous surgery (Fig.-1) ^{13,17}.

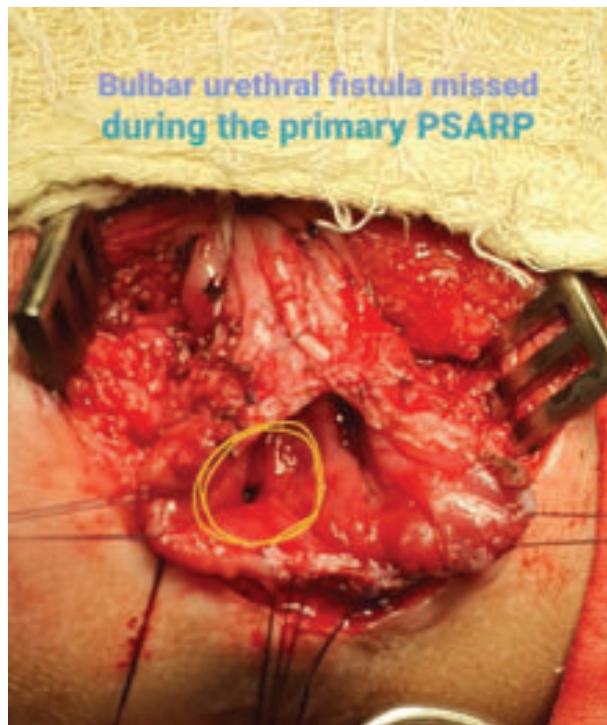

Fig.-1: Posterior sagittal approach to repair a persistent RUF

Some authors have reported correction of RUF without diverting colostomy, but those cases required extensive bowel preparation and long-term nutritional support. Fecal diversion is always safe for these patients. It rests the perineal wound and avoids anal spasms; a diverting colostomy allows spontaneous healing even if a recurrence occurs. A urinary diversion (suprapubic catheter) should be considered if a urethral injury is approached. Some authors recommend mandatory fecal and urinary diversion in these patients ^{17,18}.

Prevention of post-operative fistula

The surgeon's experience in the special anatomy of the ARM with RUF is mandatory to avoid this

dangerous complication. The essential steps include a high-pressure distal colostogram to delineate the fistula and placement of a urinary catheter before performing perineal reconstruction. Adequate mobilization of the rectum is recommended to avoid superimposed suture lines between the urethra and the rectum. Primary PSARP should be avoided without delineating the exact pathological anatomy of individual patients ^{13,14,16,18}.

Urethral stenosis/ stricture

Urethral stenosis, stricture, or acquired urethral atresia occurs when the surgeon accidentally devascularize or transects the urethra. It can occur during the separation of the common wall between the rectum and the urethra. Over enthusiastic closure of the urethra after fistula resection and traction of the urethra with multiple stay sutures might also cause urethral stricture. Sometimes, it is not detected immediately, and patients present later with urinary symptoms. A high index of suspicion is required to diagnose this problem when a patient presents with difficult voiding and or recurrent UTI after PSARP ^{7,13,14,16}.

Placement of a urethral catheter is difficult in these patients. Imaging studies may show thickened bladder and upper tract dilatation. A retrograde urethrogram may delineate a narrowing of the urethra at the level of injury. A cystoscopy is diagnostic and can be used as a therapeutic tool for gradual urethral dilation. In severe cases, a reoperation is required ^{13,14,16}. Levitt et al. recommended another posterior sagittal approach to repair this problem. Complete mobilization of the rectum exposes the urethral area for identification & mobilization of both the end of the urethra and tension free end to end anastomosis ¹³. In addition to fecal diversion, a urinary diversion (suprapubic catheter) should be considered in severe cases ^{13,18}.

Remnant of original fistula (ROOF)

ROOF was previously called posterior urethral diverticulum (PUD). It occurs when a segment of the rectum is left attached to the urethra during PSARP. It usually occurs in patients with a higher fistula approached from the abdomen. With the increasing incorporation of laparoscopy in the management of ARM, ROOF also occurs in the bulbar and prostatic fistula because it is very difficult to reach the urethral end in low-lying fistulas. Therefore, surgeons leave an extra piece of rectal tissue with the urethra ^{19,20}.

ROOF usually remains asymptomatic in the immediate postoperative period. Later, it presents with recurrent UTI, dribbling of urine, and dysuria. Some patients even develop stones within the diverticulum. An MCU can delineate a ROOF in most patients. A pelvic MRI is indicated to confirm the diagnosis and determine the extension of the diverticulum (Fig. 2). Imaging may miss the diagnosis in some patients. Therefore, all patients required a careful examination under anesthesia and cystoscopy to evaluate the size and the presence of any stone^{15,20}.

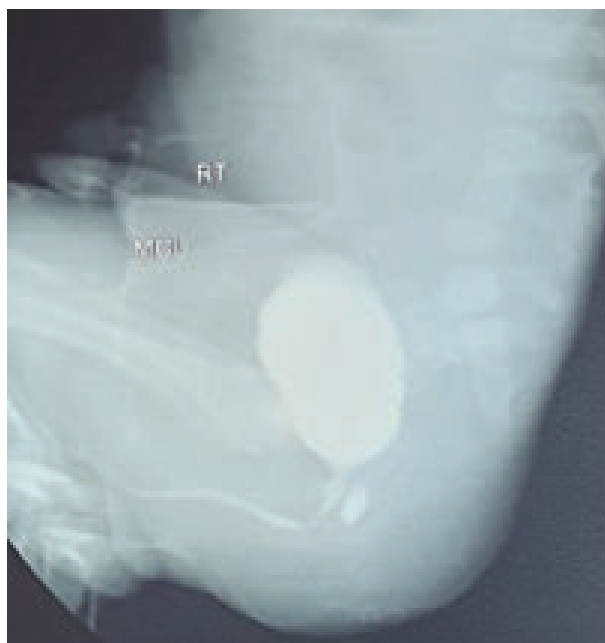


Fig-2: MCU delineating a ROOF after PSARP

The treatment of choice is the resection of ROOF in the posterior sagittal approach. After mobilization of the rectum, ROOF is completely mobilized and separated from the urethra, as in the definitive operation. A diverting colostomy is always performed to prevent perineal contamination and promotes wound healing^{15,18,20}.

Several technical modifications have been described to avoid this complication. Huang et al. reported cystoscopy-assisted excision of the RUF during PSARP¹⁰. Several authors recommended simple division and non-closure of the RUF during the original reconstruction. The hypothesis is that it prevents diverticulum formation even if a small segment of the rectum is left behind^{7,21}.

Bladder injury and or dysfunction

Neurogenic bladder is very unusual in boys after PSARP. It usually occurs due to bladder and or bladder

neck injury and complete denervation of the bladder neck during PSARP. It is very difficult to clarify a neurogenic bladder that is congenital or iatrogenic after surgery. Ralph et al. believe that the atonic type of neurogenic bladder results from surgical injury. Boemers et al. investigated the urodynamic studies of 27 boys before and after surgery and concluded that PSARP does not affect bladder function unless it is associated with major trans-abdominal and retrovesical dissection. The diagnostic workup follows the standard protocol of clinical and radiological investigations. The management goals are directed towards achieving continence and protecting the upper tract^{13,16}.

The authors practice a modified technique of PSARP, where the rectum is mobilized first proximally and then posterior to the bladder (retro vesical space) circumferentially. At this level, there is no longer a common wall with the urethra (Fig.-3).

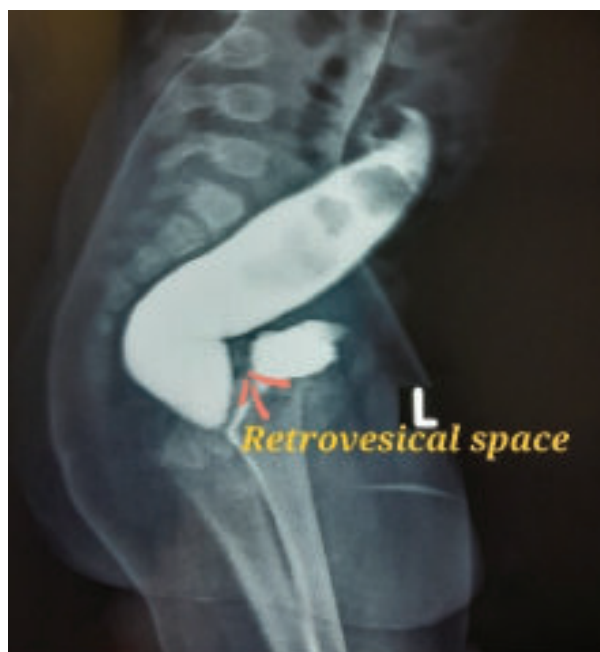

Fig.-3: The retro vesical space allows enough space for dissection without injuring the urogenital tract

The rectum is then pulled upwards using a vessel loop or a feeding tube to delineate a line of demarcation between the urethra and rectum, through which the dissection is continued to separate the rectum from the urethra (Fig.-4). This modification avoids traction sutures at the common wall between the rectum and the urethra and a submucosal dissection at this level, which avoids urethral injury, ROOF, and fistula recurrence.

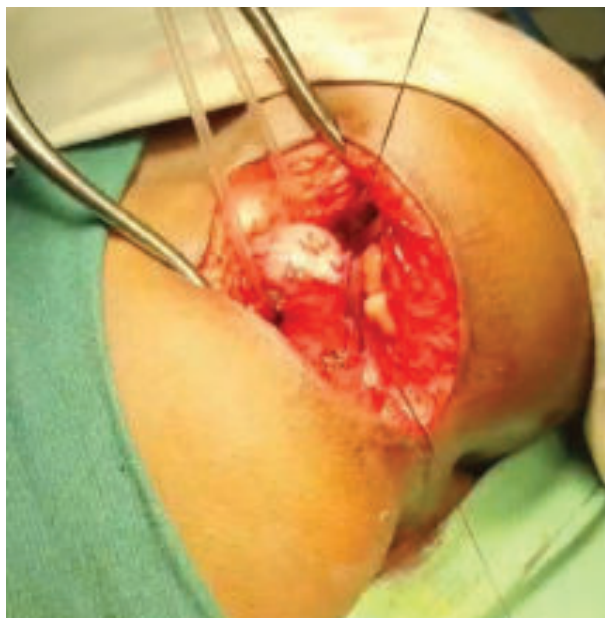


Fig.- 4: Pulling the rectal pouch away from the urinary tract.

Other urological injuries

Injuries to the vas deferens, seminal vesicle, and ureter have been reported in some series. All of these happened as a result of inadequate delineation of the exact anatomy before definitive surgery^{13,16}.

Conclusion

Reconstruction of ARM is associated with a significant risk of a variety of urinary injuries. Inadequate information about the individual patient's anatomy before surgery, lack of experience, and primary PSARP are the major risk factors for this. Adequate training of the paediatric surgeons on this complex reconstruction, a high-pressure distal colostogram before surgery to delineate the individual anatomy, and placement of a urinary catheter during surgery are the mandatory steps to follow to avoid serious urological injuries during ARM reconstruction.

Conflict of interest: None

References

1. Cassina M, Fascetti Leon F, Ruol M, Chiarenza SF, Scirè G, Midrio P, Clementi M, Gamba P. Prevalence and survival of patients with anorectal malformations: A population-based study. *J Pediatr Surg.* 2019 Oct;54(10):1998-2003. doi: 10.1016/j.jpedsurg.2019.03.004. Epub 2019 Mar 16. PMID: 30935729.

2. Toobaie A, Yousef Y, Balvardi S, St-Louis E, Baird R, Guadagno E, Poenaru D. Incidence and prevalence of congenital anomalies in low- and middle-income countries: A systematic review. *J Pediatr Surg.* 2019 May;54(5):1089-1093. doi: 10.1016/j.jpedsurg.2019.01.034. Epub 2019 Feb 2. PMID: 30786990.
3. Hanif, A., Hasina, K., Rouf, M. A., Islam, K. S., Ferdous, N. S., Khan, J. G., & Kazal, M. A. H. Neonatal surgery: Demand and survival both are on increase- an experience of seventeen years in Dhaka Medical College Hospital, Bangladesh. *Bangladesh Medical Research Council Bulletin.* 2020; 46(1), 5–11. <https://doi.org/10.3329/bmrcb.v46i1.47462>
4. Chowdhury, T. K., Kabir, S. M. H., Farooq, M. A. A., Sarwar, M. K. A., Khastagir, R., & Sajid, M. M. Mortality from Surgical Conditions in Children: An Insight from a Tertiary-Level Government Hospital in Bangladesh. *Asian Journal of Pediatric Research.* 2020; 4(3): 26–34. <https://doi.org/10.9734/ajpr/2020/v4i330151>
5. Hasan MS, Islam N, Mitul AR. Neonatal Surgical Morbidity and Mortality at a Single Tertiary Center in a Low- and Middle-Income Country: A Retrospective Study of Clinical Outcomes. *Front Surg.* 2022 Feb 3;9:817528. doi: 10.3389/fsurg.2022.817528. PMID: 35187058; PMCID: PMC8850305.
6. Bjoersum-Meyer T, Kaalby L, Lund L, Christensen P, Jakobsen MS, Baatrup G, Qvist N, Ellebaek M. Long-term Functional Urinary and Sexual Outcomes in Patients with Anorectal Malformations-A Systematic Review. *EurUrol Open Sci.* 2021;25:29-38. doi: 10.1016/j.euros.2021.01.007. PMID: 34337501; PMCID: PMC8317805.
7. Pandey V, Gangopadhyay AN, Gupta DK, Sharma SP, Kumar V. Management of anorectal malformation without ligation of fistula: an approach preventing posterior urethral diverticula. *J Pediatr Urol.* 2014 Dec;10(6):1149-52. doi: 10.1016/j.jpuro.2014.04.016. Epub 2014 Jun 5. PMID: 24953283.
8. Fujiwara K, Ochi T, Koga H, Miyano G, Seo S, Okazaki T, Urao M, Lane GJ, Rintala RJ, Yamataka A. Lessons learned from lower urinary tract complications of anorectoplasty for

- imperforate anus with rectourethral/rectovesical fistula: Laparoscopy-assisted versus posterior sagittal approaches. *J Pediatr Surg.* 2021 Jul; 56(7):1136-1140. doi: 10.1016/j.jpedsurg.2021.03.041. Epub 2021 Mar 26. PMID: 33838897.
9. Bischoff A, Peña A, Levitt MA. Laparoscopic-assisted PSARP - the advantages of combining both techniques for the treatment of anorectal malformations with recto-bladderneck or high prostatic fistulas. *J Pediatr Surg.* 2013 Feb;48(2):367-71. doi: 10.1016/j.jpedsurg.2012.11.019. PMID: 23414867.
 10. Huang Y, Xu W, Xie H, Wu Y, Lv Z, Chen F. Cystoscopic-assisted excision of rectourethral fistulas in males with anorectal malformations. *J Pediatr Surg.* 2015 Aug; 50(8):1415-7. doi: 10.1016/j.jpedsurg.2015.04.002. Epub 2015 Apr 10. PMID: 25913895.
 11. Stenström P, Anderberg M, Kockum CC, Arnbjornsson E. Endoscopically placed rectourethral guidewire facilitates the reconstruction of anus in children with anorectal malformations: a case report. *European J Pediatr Surg Rep.* 2013 Jun;1(1):46-7. doi: 10.1055/s-0033-1345104. Epub 2013 Apr 24. PMID: 25755952; PMCID: PMC4335956.
 12. Pratap A, Tiwari A, Kumar A, Adhikary S, Singh SN, Paudel BH, Bartaula R, Mishra B. Sphincter saving anorectoplasty (SSARP) for the reconstruction of Anorectal malformations. *BMC Surg.* 2007 Sep 24;7:20. doi: 10.1186/1471-2482-7-20. PMID: 17892560; PMCID: PMC2093923
 13. Levitt M, Pena A. Complications after the Treatment of Anorectal Malformations and Redo Operations. In: Hohlschneider A, Hustson J, editors. *Anorectal Malformations in Children: Embryology, Diagnosis, Surgical Treatment, Follow-up.* Berlin, Heidelberg: Springer; 2007. 319-326
 14. Peña A, Hong AR, Midulla P, Levitt M. Reoperative surgery for anorectal anomalies. *Semin Pediatr Surg.* 2003 May;12(2):118-23. doi: 10.1016/s1055-8586(02)00022-7. PMID: 12728398.
 15. Tirrell TF, McNamara ER, Dickie BH. Reoperative surgery in anorectal malformation patients. *Transl Gastroenterol Hepatol.* 2021 Jul 25;6:43. doi: 10.21037/tgh-20-214. PMID: 34423164; PMCID: PMC8343547.
 16. Hong AR, Acuña MF, Peña A, Chaves L, Rodriguez G. Urologic injuries associated with repair of anorectal malformations in male patients. *J Pediatr Surg.* 2002 Mar;37(3):339-44. doi: 10.1053/jpsu.2002.30810. PMID: 11877644.
 17. Kulshrestha S, Kulshrestha M, Yadav A, Singh B, Elhence IP, Gangopadhyay AN, Sarkar B, Tewari V. Posterior sagittal approach for repair of rectourethral fistula occurring after perineal surgery for imperforated anus at birth. *J Pediatr Surg.* 2000 Aug;35(8):1155-60. doi: 10.1053/jpsu.2000.8717. PMID: 10945685
 18. Huang X, Chen Y, Pang W, Peng C, Wu D. Transanal fistulectomy for postoperative persistent rectourethral fistula in patients with ARM: is simple resection enough? *BMC Surg.* 2021 Apr 2;21(1):179. doi: 10.1186/s12893-021-01186-3. PMID: 33810794; PMCID: PMC8017811.
 19. Leva E, Macchini F, Arnoldi R, Di Cesare A, Gentilino V, Fumagalli M, Mosca F, Bhuiyan A, Torricelli M, Banu T. Single-stage surgical correction of anorectal malformation associated with rectourinary fistula in male neonates. *J Neonatal Surg.* 2013 Jan 1;2(1):3. PMID: 26023423; PMCID: PMC4420348.
 20. Rentea RM, Halleran DR, Vilanova-Sanchez A, Lane VA, Reck CA, Weaver L, Booth K, DaJusta D, Ching C, Fuchs ME, Jayanthi RR, Levitt MA, Wood RJ. Diagnosis and management of a remnant of the original fistula (ROOF) in males following surgery for anorectal malformations. *J Pediatr Surg.* 2019 Oct;54(10):1988-1992. doi: 10.1016/j.jpedsurg.2019.02.006. Epub 2019 Feb 28. PMID: 30879755.
 21. Al Matar, Z., Maqbool, S., Zakaria, H. *et al.* Simple division of rectourethral fistula as an alternative to ligation during laparoscopic repair of anorectal malformation. *Ann Pediatr Surg* **18**, 86 (2022). <https://doi.org/10.1186/s43159-022-00225-9>