

Melioidosis: A Case Report of Confirmed *Burkholderia Pseudomallei* in Rangpur Medical College Hospital, Rangpur

Md. Helal Miah¹, Tania Begum², Md Shafiul Alam³, ASM Rahenur Mondol⁴, Md. Mahfuj-Ul-Anwar⁵

1. Assistant Professor
Department of Medicine
Rangpur Medical College
2. Resident, MD Phase-B
Department of Medicine
Rangpur Medical College
3. Associate Professor
Department of Medicine
Rangpur Medical College
4. Assistant Professor
Department of Medicine
Rangpur Medical College
5. Assistant Professor
Department of Medicine
Rangpur Medical College

Correspondence to:

Md. Helal Miah

Assistant Professor
Department of Medicine
Rangpur Medical College
Mobile: 01726863689
Email: drhelalmiah25@yahoo.com



Introduction:

Melioidosis is an infectious disease caused by the gram-negative bacteria - *Burkholderia pseudomallei*. It is associated with significant mortality due to an early onset of fulminant sepsis. The disease is endemic in South-East Asian countries and in Northern Australia.¹ It is now an emerging infection in Bangladesh.² Bangladesh is an example of a highly populous, agricultural country where melioidosis may be a significantly underdiagnosed cause of infection and death. A lack of awareness among microbiologists and clinicians and a lack of diagnostic microbiology infrastructure are factors that are likely to lead to the underreporting of melioidosis. The first reported, confirmed case of melioidosis that was acquired from Bangladesh (at that time known as East Pakistan) was a British sailor.³ The clinical presentation of melioidosis is widely varied, and a definitive diagnosis requires a skilled microbiology laboratory, making it more difficult to diagnose in low-resource settings such as Bangladesh. Agriculture is the most productive

Abstract

Bangladesh is an example of a highly populous, agricultural country where melioidosis may be a significantly underdiagnosed cause of infection and death. Melioidosis is caused by a highly pathogenic, soil-borne, Gram-negative bacterium, *Burkholderia pseudomallei*. Diabetes mellitus is the most common risk factor. Disease manifestations vary from pneumonia or localized abscess to acute septicemia or arthritis. Culture is considered the current gold-standard for diagnosis. For the intensive phase (10 to 14 days), ceftazidime or meropenem is the drug of choice. For the eradication phase (3 to 6 months), oral trimethoprim/ sulfamethoxazole is the drug of choice. Surgery (drainage of abscess) has an important role in the management of melioidosis. A 48-year-old male, health worker of an NGO, working at Cox's Bazar presented with fever for 1 month and gradual increasing pain and swelling of the left knee for 7 days followed by cellulitis and multiple abscess formation in the left leg. *B. pseudomallei* isolated from blood culture and successfully treated with meropenem.

Keywords: Melioidosis, *Burkholderia pseudomallei*

sector of the country's economy, contributing about 30% of the nation's GDP and providing over 90% of Bangladesh's rural employment.⁴ Melioidosis primarily affects persons who are in regular contact with soil and water. Infection results from percutaneous inoculation (e.g., by means of a penetrating injury or open wound), inhalation (e.g., during severe weather or as a result of deliberate release), or ingestion (e.g., through contaminated food or water). In most regions, the disease is highly seasonal, with rainy season peaks corresponding with higher infection rates. Vertical and sexual transmission, zoonotic transmission from animals with melioidosis, and transmission to laboratory staffs are very uncommon but have been documented. Although incidence peaks between 40 and 60 years of age, melioidosis is well recognized in children.⁵ Though human-to-human transmission is rare, a reported case of transmission to an infant from a mother with melioidosis mastitis via ingestion of breast milk has been described.^{3,4} Major organ involvement and clinical features were classified as

follows: Pulmonary: pneumonia, including complications such as a lung abscess or a pleural effusion. Musculoskeletal (MSK): septic arthritis, osteomyelitis, and others. Genitourinary (GU): infection of the urinary and genital tract, including the kidneys. Neurological: involvement of the brain and spinal cord, including the meninges. Organ abscess/deep-seated abscess: Abscess involving any solid organ or in any deep-seated site such as the muscles. Cutaneous: infection and abscess of the skin and subcutaneous tissue. Bacteraemia without focus: acute sepsis without any specific focus.

respiratory rate 18 breaths/min mildly enlarged spleen without palpable liver or any free fluid in the abdomen, and no cardiovascular or neurological abnormalities. On local examination- the left leg is swollen, edematous, cellulitis, and with pustular discharge. Laboratory investigations showed hemoglobin- 8.49gm/dl, ESR-85mm in 1st hour, total count- 13.0K/ul, MCV- 77fl, urine R/M/E- pus cell- plenty, RBC= 3-4/HPF, Serum Creatinine- 1.2 mg/dl, Serum Electrolytes- sodium-128, potassium-4.5 mol/l, bicarbonates-normal, Chest X-ray – normal, Ultrasonography- Hepatosplenomegaly,

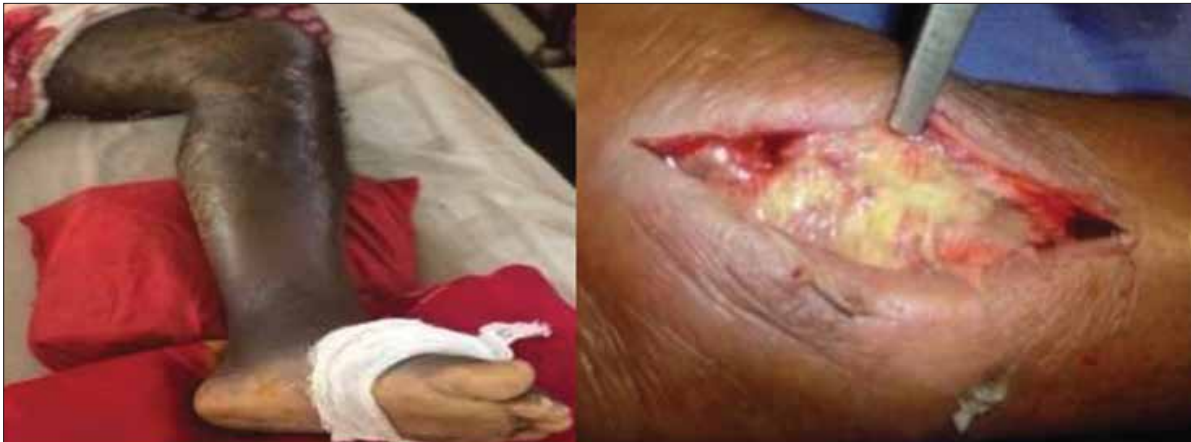

Figure-1: Cellulitis of left lower limb, deep seated pus after incision

A case report:

Our patient was a 48-year-old male from Sundorgong, Gaibanda district of Bangladesh. He was an NGO's worker who worked at Cox's Bazar for about three years. He presented with gradual increasing pain and swelling in his left knee for 7 days and fever for the last 1 month associated with weight loss, after admission in this hospital cellulitis and multiple abscesses developed in his left leg up to mid-thigh. About eight months back same episode of fever occurred and was treated with antibiotics, in that time investigations showed-Cystitis, Pyelonephritis, Encysted pelvic abscess, and Perinephric abscess. At the same time, he was diagnosed with Diabetes Mellitus. With treatment-though his fever was subsided to some extent, during the last 1 month he again complained of high fever, pain, and swelling of the left knee. Cellulitis and multiple abscesses developed on his left leg after admission. On examination he was toxic, febrile, moderately anemic, and mildly icteric. His highest body temperature was 102°F, BP- 90/70mm of Hg, pulse 80beats/ min,

serum albumin- 2.6gm/dl, Serum ALT-11u/L, serum bilirubin-5.6mg/dl, HBsAg and Anti HCV- Negative, Urine albumin-+++, Upper GIT endoscopy-normal, ANA- positive (sample index-3.0, cutoff index-1.5), Anti ds DNA -negative, MT-4mm, Hb electrophoresis- normal, D-dimer-10ug/mL (normal <0.5), ICT for kala-azar- negative, HIV screening-negative, Duplex study- of left lower limb-superficial venous thrombosis and features of thrombophlebitis involving long saphenous vein multiple segments of superficial veins of saphenous territory, deep veins are patent, Blood C/S report results-*Burkholderia pseudomallei* isolated in aerobic condition. Meropenem, and Ceftazidime both are sensitive. Treatment started with Meropenem. The post-admission condition further deteriorated and developed compartmental syndrome of the left leg and arranged for fasciotomy. After the incision, deep-seated pus was found (Figure-1), and then the pus was drained and followed by regular dressing and treated with flucloxacillin, Meropenem and LMWH followed by co-trimoxazole for next three months.

Discussion:

Melioidosis is an emerging infection in Bangladesh. It is still underreported due to its diverse clinical manifestations and the inadequacy of conventional bacterial identification methods.⁶ Moreover, clinical, radiological, and pathological similarities with Melioidosis in a Patient with Diabetes Mellitus. Worldwide about 1,65,000 people are diagnosed with cases of melioidosis per year.⁷ Among them, 15% account for pediatric melioidosis in endemic areas.⁸ Diabetes mellitus has been found to be one of the most frequent predisposing factors. Our patient was diabetic. Vidyalaxmi et al found a correlation of 76% between DM and melioidosis.⁹ In Bangladesh, during the period from 1988 to 2016, twenty-one cases of culture-confirmed melioidosis have so far been reported. Almost all of them suffered from diabetes mellitus. The organism has a unique ability to bind human insulin, and this bacterial property underlies a unique biological and clinical relationship with important implications for diabetes.¹⁰ The presentation of melioidosis ranges from localized to systemic infection. Infection by the causative agent *B. pseudomallei* causes abscess formation in different organs of the body, such as the lung, liver, prostate, and soft tissues. It presents as a febrile illness, ranging from acute fulminant septicemia to a chronic, debilitating localized infection.¹¹ Mortality rate remains high, even with aggressive antibiotic therapy. In endemic areas, the mortality rates ranged from 19% to 68%.⁴ It stresses the need for quick diagnosis and early initiation of appropriate treatment. Microbiological culture is considered the current gold standard (Figure-2,3) for diagnosis and culture confirmation should always be sought in patients where the disease is suspected. The likelihood of diagnosing melioidosis is maximized when appropriate clinical samples from a variety of sites and specimen types are sent to the microbiology laboratory for microscopy and culture.¹⁰⁻¹¹ The drug of choice for this stage is intravenous ceftazidime or meropenem for a minimum period of 10 to 14 days depending on the nature and severity of clinical presentations.²¹ This should be increased for severely ill patients, including those with extensive pulmonary disease, deep-seated collections or organ abscesses, osteomyelitis, septic arthritis, or neurological Melioidosis. In resource-poor settings, extending intensive-phase treatment duration may not be afford, able, but a minimum of 10 to 14

days is recommended. In this situation, completing a full course of oral eradication therapy is essential. In patients with a collection (including skin ulcers/ abscesses and abscesses in internal organs), and in bone/joint, genitourinary, or in CNS infections (but not for pneumonia), intravenous or oral trimethoprim/ sulfamethoxazole may be added. If trimethoprim/ sulfamethoxazole is included, it should be continued for the entire duration of the intensive-phase treatment.¹² The drug of choice for oral eradication-phase is oral trimethoprim/ sulfamethoxazole for a minimum of 3 months post cessation of IV therapy. It can be extended to 6 months if neurological melioidosis, osteomyelitis, or vascular mycotic aneurysms are present. The alternative drug of choice is amoxicillin/ clavulanic acid.³ It dramatically reduces the relapse of melioidosis, which is very common. Even after a full course of eradication therapy 10%. Relapse can reach up to 30 % if the duration of oral eradication therapy lasts for less than 8 weeks. Relapse can be manifested as a severe acute illness and could be fatal.¹³

Surgery has an important role in the management of melioidosis. Drainage is required for localized pus such as big abscesses in internal organs (liver, prostate, etc. and muscles. Repeated joint aspiration and washout may be required in septic arthritis if the collection is massive. Other internal abscesses rarely need to be drained as they frequently resolve with medical therapy. Repeated surgical debridement of the necrotic bones is an essential part of managing osteomyelitis. Urgent surgical intervention is warranted if a Mycotic aneurysm is suspected.¹⁴

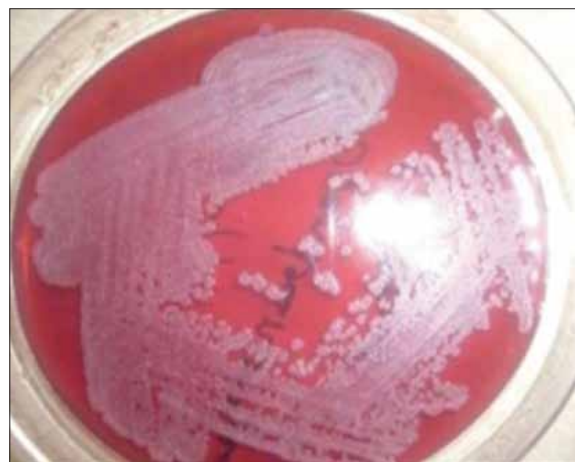

Figure-2: Colonies of *Burkholderia pseudomallei* on Mac Conkey agar¹⁵

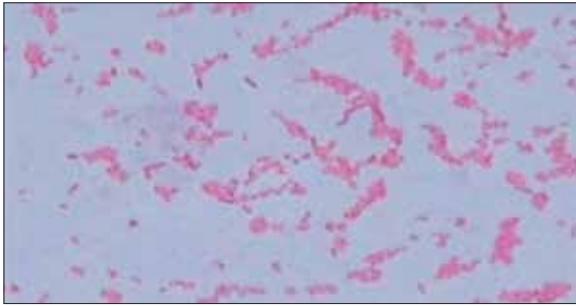


Figure-3: Safety-pin appearance of gram-negative *Burkholderia pseudomallei*¹⁵

As of today, there is no available vaccine to prevent melioidosis. Some preventive measures such as avoiding contact with soil and standing water, wearing appropriate clothing and footwear, washing or showering after exposure to contaminated water or soil, cleaning of wounds, maintaining regular hand hygiene, and others have shown effective in preventing melioidosis.¹³⁻¹⁴

Conclusion:

The case focuses on the need to record the presence of Melioidosis in Bangladesh. This case was initially probably missed due to a lack of clinical awareness and correct microbiological diagnosis. A high index of suspicion is needed for diagnosis due to its varied clinical presentations. At the same time, the case highlights the need for improved microbiology services in patient care management. With the recognition of this bacterium as a potential agent of biological warfare, we were able to successfully treat the case by the institution of correct antimicrobials based on microbiological feedback.

References:

1. White NJ. Melioidosis. *Lancet*. 2003 May 17;361(9370):1715-22. doi: 10.1016/s0140-6736(03)13374-0.
2. Limmathurotsakul D, Dance DA, Wuthiekanun V, Kaestli M, Mayo M, Warner J, et al. Systematic review and consensus guidelines for environmental sampling of *Burkholderia pseudomallei*. *PLoS Negl Trop Dis*. 2013;7(3):e2105. doi:10.1371/journal.pntd.0002105.
3. Maegraith B.G., Leithead C.S. Melioidosis: A case-report. *Lancet*. 1964;1:862-863. doi: 10.1016/S0140-6736(64)91581-8.
4. Haradhan M. Food, agriculture and economic situation of Bangladesh; Proceedings of the 2nd

- International Conference on Global Sustainable Development (2nd ICGSD-2013); Kasbit, Pakistan. 5-6 October 2013. MPRA Paper No. 54240, Mar 2014. https://mpra.ub.uni-muenchen.de/54240/1/MPRA_paper_54240.pdf [Accessed 12th June, 2022]
5. Chowdhury FR, Jilani MSA, Barai L, Rahman T, Saha MR, Amin MR, Fatema K, Islam KMS, Faiz MA, Dunachie SJ, Dance DAB. Melioidosis in Bangladesh: A Clinical and Epidemiological Analysis of Culture-Confirmed Cases. *Trop Med Infect Dis*. 2018 Apr 9;3(2):40. doi: 10.3390/tropicalmed3020040
6. Ahmed A, Mollah MA et al. Melioidosis in a patient with Type 1 diabetes Mellitus-A case report. *Bangladesh J child health* 2018;Vol42(1):46-53
7. Halder D, Zainal N Haq JA. Neonatal meningitis and septicemia caused by *Pseudomonas pseudomallei*. *Annals of Tropical pediatrics* 1998;18:161-64
8. Halder D, Zainal N Haq JA. Neonatal meningitis and septicemia caused by *Pseudomonas pseudomallei*. *Annals of Tropical pediatrics* 1998;18:161-64
9. Vidyalakshmi KS, Shrikala B, Bharathi B, Suchitra U. Melioidosis: An under-diagnosed entity in western coastal India: A clinicomicrobiological analysis. *Indian J Med Microbiol* 2007;25:245-8
10. Cheng AC, Currie BJ. Melioidosis: epidemiology, pathophysiology, and management. *Clin Microbiol Rev*. 2005;18(2):383-416. pmid:15831829
11. Zueter AR, Yean CY, Abumarzouq M, Rahman ZA, Deris ZZ, Harun A. The epidemiology and clinical spectrum of melioidosis in a teaching hospital in a North-Eastern state of Malaysia: a fifteen year Review. *BMC Infect Dis* 2016; 16:333
12. Rachlin A, Dittrich S, Phommasone K, Douangnouvong A, Phetsouvanh R, Newton PN, et al. Investigation of Recurrent Melioidosis in Lao People's Democratic Republic by Multilocus Sequence Typing. *Am J Trop Med Hyg*. 2016 Jun; 94(6):1208-11
13. Chowdhury FR, Jilani MSA, Barai L, Rahman T, Saha MR, Amin MR, et al. Melioidosis in Bangladesh: A Clinical and Epidemiological Analysis of Culture-Confirmed Cases. *Trop Med Infect Dis* [Internet]. 2018 Apr 9;3(2):40. Available from: <https://pubmed.ncbi.nlm.nih.gov/30274436>
14. F Chowdhury FR, Roy CK, et al. Review Article Melioidosis: A Neglected Infection in Bangladesh. *J MEDICINE* 2021; 22: 13.
15. Barman P, Sidhwa H, Shirkhande PA. Melioidosis: a case report. *J Glob Infect Dis*. 2011 Apr;3(2):183-6. doi: 10.4103/0974-777X.81697