

Case Report

Intra-abdominal Testicular Seminoma in a Middle Aged Male: A Case Report

Md Jahangir Alam¹, Din Mohammad², Farhad Uddin Ahmed³, Rumi Farhad Ara⁴,
Md. Mahe Alam⁵

Abstract

Cryptorchidism is a common risk factor for the testicular germ cell tumors (TGCTs). The risk of malignancy in an undescended testis is 10% with the highest risk in an intra-abdominal testis. It usually presents with non-specific symptoms so a complete systemic physical examination should not be neglected in an elderly patient with intra-abdominal mass. We here present a case of an intra-abdominal testicular seminoma in middle aged man as an asymptomatic abdominal mass. [*Journal of Science Foundation, January 2017;15(1):26-28*]

Keywords: Cryptorchidism, Male, Neoplasms, Seminoma, Testicular Neoplasms

Introduction

Cryptorchidism is the most common congenital genitourinary anomaly in men (Alshyarba 2010). It is a well-known risk factor for the testicular germ cell tumors (TGCTs). The risk of malignancy in an undescended testis is 10% with the highest risk in an intra-abdominal testis (Cristián Palma et al., 2007). We here present a case of an intra-abdominal testicular seminoma in middle aged man as an asymptomatic abdominal mass.

Case Presentation

A 36-year fertile male was admitted with complaint of left lower abdominal mass for last 11 month & occasional pain in this same reason for same duration. On clinical examination, there was a well-defined mass in left lower abdomen extending left iliac left lumbar, umbilical & part of hypogastric. Testes were not felt in the scrotum. Scrotum was under developed. Computerized tomography (CT Scan) abdomen showed a fairly large lobulated soft tissue mass measuring (14x13x10)cm having tiny calcifications and hypodense necrotic areas is seen in lower abdomen occupying umbilical, left iliac, hypogastric regions vertically extending from L4 to S2 level [Figure 1]. The mass cause splaying of small gut peripherally and compresses the urinary bladder from above. After iv contrast moderate heterogenous enhancement of mass is seen. Rounded soft tissue density mass measuring (3.3x3.6) is seen in left paraaortic region, suggesting enlarged discrete lymphnode [Figure 3]. While image guided aspiration cytology reported it as malignant lesion with indeterminate histology, the core needle biopsy showed cells present in poorly demarcated lobules with clear cytoplasm, well defined cell borders, pleomorphic vesicular nuclei and occasionally prominent nucleoli interspersed by fibrous septas with lymphoplasmocytic infiltration which confirmed as seminoma [Figure 2]. Among tumor markers, Alfa fetoprotein was marginally raised and rest were within normal limits. Metastatic workup and other routine investigation were within normal limits. Patient underwent exploratory laparotomy where a solid mass of size 15x15x10 cm was found. Final histology report confirmed it as seminoma. Patient then received chemotherapy and post-operative tumor markers were within normal limits.

¹Associate Professor, Department of Surgery, Shaheed Suhrawardy Medical College, Dhaka, Bangladesh

²Assistant Professor, Department of Surgery, Shaheed Suhrawardy Medical College, Dhaka, Bangladesh

³Junior Consultant, Department of Surgery, Shaheed Suhrawardy Medical College Hospital, Dhaka, Bangladesh

⁴Associate Professor, Department of Gynaecology & Obstetrics, Kushtia Medical College, Kushtia, Bangladesh

⁵Honorary Medical Officer, Department of Surgery, Shaheed Suhrawardy Medical College Hospital, Dhaka, Bangladesh



Fig-1: CT Abdomen shows well defined extra intestinal mass.

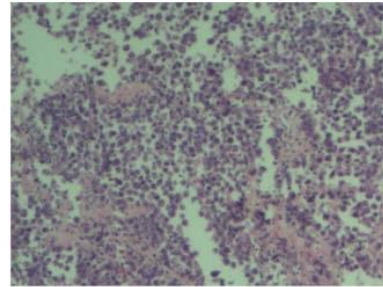


Fig-2: Tumor Cells Present in Poorly Demarcated lobules with clear cytoplasm, well defined cell borders, pleomorphic vesicular nuclei and occasionally prominent nucleoli interspersed by fibrous septas with lymphoplasmocytic infiltration

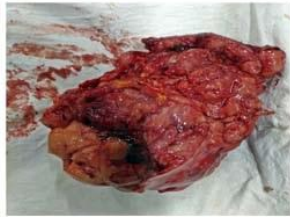


Fig-3: A mass of size 15 x 15 x 10 cm

Discussion

The testis is an intra-abdominal organ during development which descends into the scrotal sac, usually between 28 to 32 weeks. It may get arrested anywhere along its tract (cryptorchidism) or may migrate into an abnormal position (ectopic testis) during descent. The most common sites of undescended testis are high scrotal (50%), canalicular (20%), and abdominal (10%) (Dahnert 2003). The risk of cancer in undescended testis is 10% (Cristián Palma et al., 2007).

Cryptorchidism is a main risk factor for TGCT. The incidence of carcinogenesis is 40 times higher in an undescended testis than in a normal scrotal testis. Furthermore, the malignant degeneration of an abdominal testis (5%) is four times more likely than an inguinal testis (1.25%) (Whitaker 1981). The incidence curve of malignancy in undescended testes increases steeply after the onset of the puberty, usually peaks in the third or fourth decade of life (Alshyarba 2010). However, the cause of carcinogenesis is still an enigma. The most common clinical presentation in abdominal cryptorchid testis cancer is painless enlarging abdominal mass and occasionally with vague abdomen pain and secondary symptoms from effects of the mass (Koh 1996). The rare presentations of the intra-abdominal germ cell tumors reported in literature are acute abdomen with intestinal perforation and haemorrhagic shock with tumor rupture (Watkins 1970; Hutcheson et al., 1996).

Seminoma (90%) is the most common histology of tumors in undescended testis, particularly in the intra-abdominal testis (Woodward et al., 2004). CT-scan and MRI are the best imaging tool for the diagnosis (Bree and Hoang 1996). In an elderly male with nonspecific intra-abdominal mass, the differential diagnosis could be sarcoma, lymphoma or other malignancies. The laparoscopy is a minimal invasive procedure to diagnose and locate the intra-abdominal testis. The image guided core needle biopsy is the most valuable for histological diagnosis but has the risk of peritoneal seeding. The seminoma is PLAP and CK7 positive which helps in confirming the diagnosis (Batata et al., 1982). The germ cell tumors spread to retroperitoneal lymph nodes, except choriocarcinoma, which has early hematogenous spread. The excision of seminoma is the primary treatment irrespective of location and the adjuvant therapy is according to pathological stage. In present case it was seminoma stage II and patient was given adjuvant chemotherapy.

Post-operative serum tumor markers has significance in both seminoma and non-seminoma germ cell tumors. Raised AFP, beta-HCG and LDH level is suggestive of advanced disease (Woodward 2004). The

prognostic factors in seminoma are age of the patient, tumor size, lymphovascular invasion, mitotic count, necrosis, giant cells and lymphocytic infiltration.

Conclusion

The abdominal cryptorchid testis is rare and carries the highest risk of malignant transformation to seminoma among undescended testis variants. It usually presents with non-specific symptoms so complete systemic physical examination should not be neglected in an elderly patient with intra-abdominal mass. In developing country like ours, poor educational level of patient and inaccessibility of health care facilities leads to delayed presentation of the patient. However, awareness regarding undescended testis and its related complications must be increased at various levels by the parents, school medical officer and the patient himself.

References

- Alshyarba MH. A giant intra-abdominal testicular seminoma. *Biomed Res.* 2010;21(3):227-229
- Batata M, Chu F, Harris B, et al. Testicular cancer in cryptorchids. *Cancer.* 1982; 49:1023-1030
- Bree RL, Hoang DT. Scrotal ultrasound. *Radiol Clin North Am.* 1996;6:1183-1205
- Cristián Palma C, Cristóbal B, Maccioni R. Seminoma in an adult cryptorchid testis (intra-abdominal): a case report. *Actas Urol Esp.* 2007;31(2):160-3
- Dahnert W. Testicular tumor. In: *Radiology review manual (5th ed).* Williams and Wilkins; 2003:925
- Hutcheson JC, Khorasani R, Capelouto CC, Moore FD Jr, Silverman SG, Loughlin KR. Torsion of intraabdominal testicular tumors. A case report. *Cancer.* 1996;77:339-343
- Koh KB. Beware the undescended testis and abdominal mass. *Aust N Z Surg.* 1996;66:851-853
- Watkins GL. Massive hemoperitoneum resulting from rupture of a seminoma in an undescended testicle. *J Urol.* 1970;103:447-448
- Whitaker RH. The undescended testis the risk of malignant degeneration. *Monogr Paediatr* 1981;12:104-108
- Woodward PJ. Seminoma in an undescended testis. *Radiology.* 2004;231:388-392