



## Case Report

### MUCINOUS CARCINOMA OF THE BREAST: REPORT OF TWO CASES

A Rahman<sup>1</sup>, M Rahman<sup>2</sup>, M Momotaz<sup>3</sup>, R Alam<sup>3</sup>, M Hossain<sup>4</sup>, MM Hussain<sup>5</sup>.

#### Abstract

Mucinous carcinoma of the breast is one of 16 rare varieties of malignant lesions of epithelial origin in breast. They account for 1-6% of all breast cancer. Variations in presentation, clinical course and prognosis has been observed in these patients. In this communication we report two cases of pure mucinous carcinoma of the breast. Both the cases were unusual, first one of them having early presentation with pulmonary and bone metastasis less commonly seen in this type of breast carcinoma and the second case had lymph node involvement that is seen in less than one fifth of the cases of mucinous carcinoma of breast. A brief review about mucinous carcinoma is supplemented with the report.

#### Introduction

Breast cancer is a heterogeneous disease in its presentation, pathological classification and clinical course. Most breast tumors are derived from mammary ductal epithelium, predominantly the terminal duct-lobular unit, and up to 75% of the diagnosed infiltrating ductal carcinoma are defined pathologically as invasive ductal carcinoma, not otherwise specified (IDC-NOS). Lobular variety, comprising 5-15% stands as second common type. 16 other epithelial types has been classified and described by the WHO system. Recently, immunohistochemical and genetic profile of tumors and these classifications are evolving as a standard part of the diagnostic process.<sup>1,2</sup>

The mucinous neoplasms are characterized by the production of abundant extracellular and/or intracellular mucin. Pure mucinous carcinomas represent 1%–2% of all breast cancers, with a reputation of presenting at one of the oldest median ages.<sup>2,4</sup> Often, despite having a large tumor size, the axillary lymph nodes are not involved. Traditionally, pure and mixed variants of mucinous carcinoma have been described.<sup>4-6</sup> These are mostly well-differentiated lesions frequently

associated with positive ERs (>90%) and PRs (81.5%) and HER-2-negative disease. Pure mucinous carcinoma has a far better prognosis than the mixed variety noted in several studies<sup>2-4</sup>. The WHO classification divides this tumor into three different subtypes: (i) mucinous carcinoma (ii) cystadenocarcinoma and columnar cell mucinous carcinoma and (iii) signet ring cell carcinoma.<sup>1,2</sup>

Two cases were treated in our surgical unit. One of them had bilateral pulmonary metastasis and also involvement of sternum. Surgery and adjuvant chemotherapy and radiotherapy was required. Review enabled us optimization of management of these two patients.

#### Case report

##### Case-1

A 40-year-old woman was admitted into Dhaka Medical College Hospital (DMCH) Surgical Unit -II with the complaint of a lump in her left breast for 4 years. There was no pain or discharge from the nipple, but the lump continued to grow in size. Excision of the lump was carried out by a surgeon about 2 years back. She gives no history of any other subsequent treatment. The lump re-appeared soon after and has continued to increase in size for about last 2 years. For last 3-4 months ulceration developed over the swelling. No history of application of any topical ointment or indigenous substance could be elicited. There was no other swelling in any part of body and she had no other obvious problems. She had no other co morbidity.

1. Assistant Professor of Surgery, Dhaka Medical College & Hospital.
2. Registrar, Dhaka Medical College & Hospital.
3. FCPS Part-II Student (Surgery),
4. Professor of Pathology, Dhaka Medical College.
5. Professor of Surgery, Dhaka Medical College.

**Correspondence to:** Dr. Atiar Rahman, FCPS (Surgery), Assistant Professor of Surgery, Dhaka Medical College & Hospital.

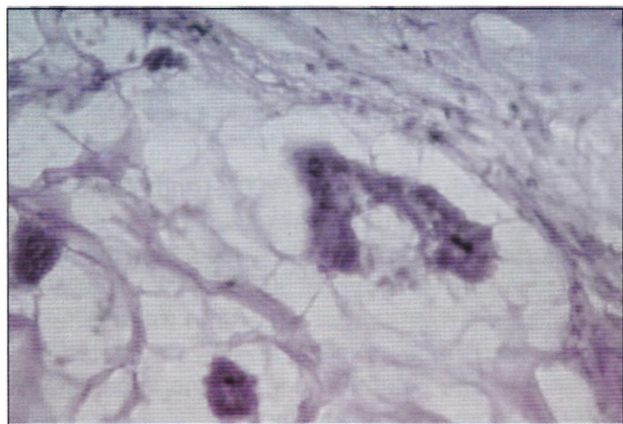
**Received:** 21 October 2012 **Accepted:** 05 January 2013



On examination, she was moderately anemic, vital signs were normal. There was a tender lump of about 12cmx12 cm size involving most of the left breast, hard in consistency; it was freely mobile over the chest wall and also there was no pectoral fixation. A 4cmx4cm ulcer was present over the left side of the nipple with partial destruction of nipple very close to scar of previous surgical procedure. No axillary lymph node was palpable. Supra clavicular nodes were also not palpable. Right breast, nipple and axilla were found normal.

Her lungs were clear to auscultation. Liver was not palpable. No other evidence of secondary deposits were detectable clinically.

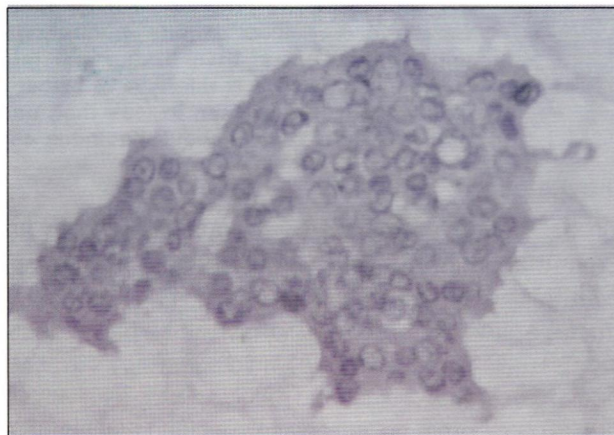
The routine biochemical profiles were within normal limits. Chest X-ray (P/A view) showed multiple nodular opacities suggestive of secondary deposits in lungs.



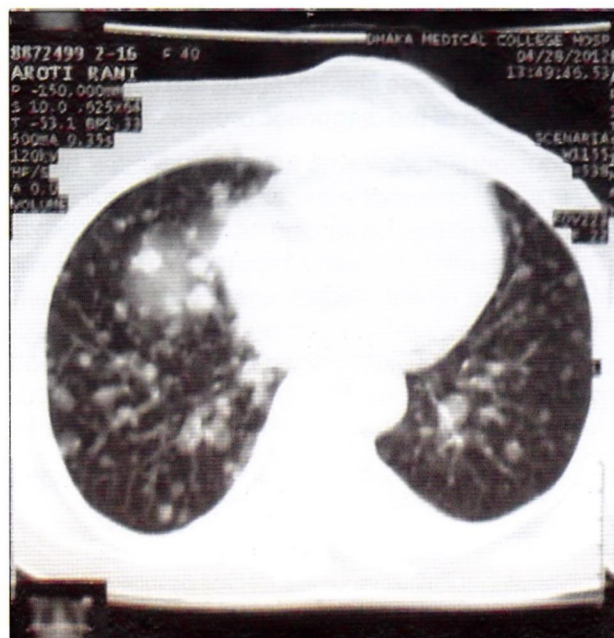
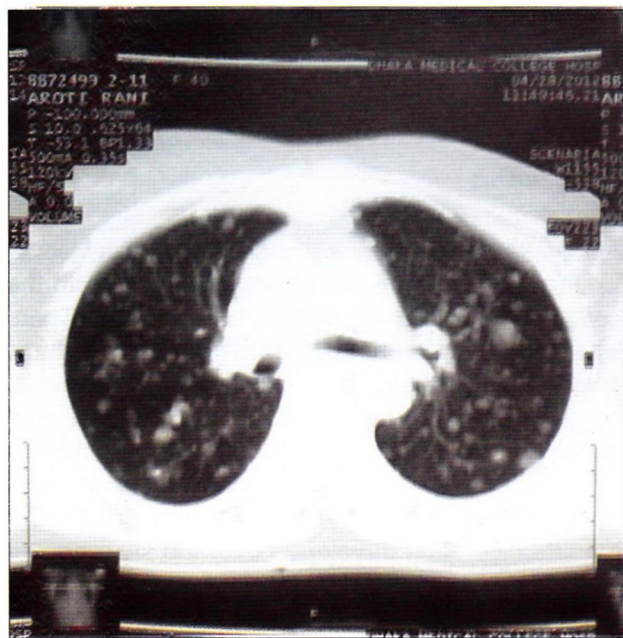
Whole body bones scan revealed infiltrative bony lesions in upper and lower part of sternum. Abdominal ultrasound was normal except a broad cervix.

After admission on 01.04.2012, incision biopsy was carried out. as FNAC was inconclusive. This revealed infiltrating mucinous carcinoma. Simple Mastectomy (left) was carried out under general anesthesia through an elliptical incision on 10<sup>th</sup> April 2012. Axillary exploration was not done. Specimen was sent for histopathology. Histopathology revealed –Mucinous Carcinoma Breast. (Pathological staging, TNM: pT4N<sub>x</sub>M not applicable.)

The patient had an uneventful postoperative recovery. Post operatively for confirmation of distant metastasis, CT scan of chest was done. This revealed multiple nodular density with irregular margin distributed over both lung fields in all zone suggestive of secondaries.

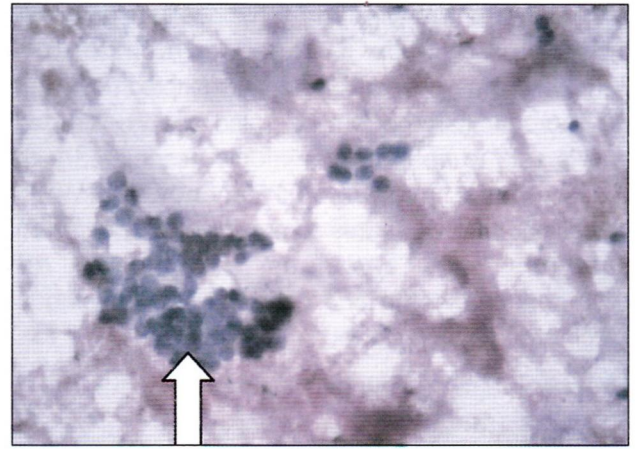
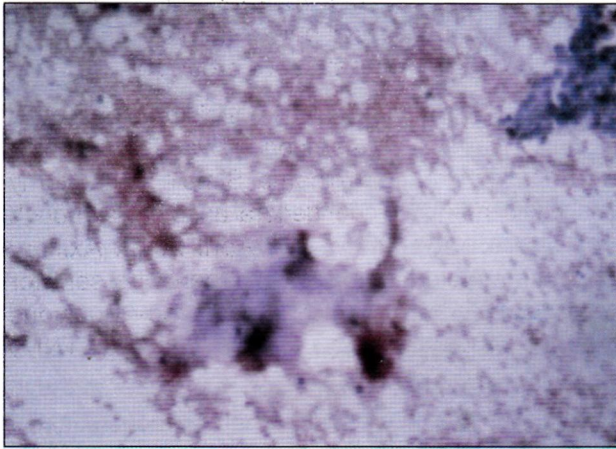


**Fig.-1:** The classic histological appearance of mucinous carcinoma of breast showing clusters of tumor cells floating in pools of extracellular mucin. (Case:1)



**Fig.-2:** CT scan of chest demonstrates that multiple secondaries in lungs (Case: 1).





**Fig.-3:** (Lung tissue): Anaplastic epithelial cells arranged in small sheets and groups in a background of mucin and blood (Case: 1).

CT guided FNAC from the pulmonary lesion revealed- "Metastatic Mucinous Carcinoma".

After consultation with the oncology department, chemotherapy (3 weekly cycle, total 6 cycles) was prescribed. She received chemotherapy (C<sub>1</sub>CT) with inj. Cyclophosphamide (800mg), inj. Doxorubicin (70mg) and inj.5 FU (750mg). Patient tolerated chemotherapy well . Endocrine therapy was continued. She is now on follow up.

### Case -2

A 50-year-old lady was admitted into DMCH under SU-II on 27.05.2012 with a lump in the right breast for 1 year. This was gradually increasing in size & was not associated with pain, any skin changes or nipple discharge. She did not notice any other swelling in axilla or any other parts of body.

On examination, she was moderately anemic, pulse rate was 78/min and B.P was 110/80 mm of Hg. There was a non-tender lump, approximately 5 cm x 4 cm in size, involving upper outer quadrant of right breast. The lump was hard in consistency, free from underlying structures and the overlying skin was freely mobile and normal. Left breast was normal.

One lymph node was palpable in right axilla, in the pectoral group, about 2cm x 1.5 cm in size, hard in consistency but mobile. Left axilla had no palpable lymph nodes.

The routine biochemical profiles were within normal limit. USG of right breast showed a mass in the right breast. Right breast lump FNAC report revealed-proliferative breast lesion with atypical cells.

Modified radical mastectomy was done on 14.06.2012. The specimen was sent for histopathology and for

estrogen progesterone receptor status. Histopathology report revealed Pure mucinous carcinoma. Pathological staging TNM: pT2 N1 M not applicable. ER, PR status was positive.

The patient had an uneventful postoperative recovery. Patient has completed chemotherapy as per advice from oncology department .She also was prescribed anti estrogen therapy.

### Discussion

Mucinous carcinomas produce intracellular and extracellular mucin. Different terminologies like colloid carcinoma etc. has been used. They are known to occur in ovaries, lungs, appendix colon and rectum and other parts of G I tract, pancreas , skin and other sites. Mucinous carcinomas of the breast are well-differentiated rare histological type of invasive ductal carcinoma.

Although it was first described in 1826,<sup>7</sup> mucinous carcinoma of the breast has remained one of the uncommon pathologic findings. The reported incidence of mucinous carcinoma has varied between 1% and 6% of all breast malignancies. Initially, any malignancy containing a mucinous component was classified as mucinous carcinoma. Mucinous carcinoma has been redefined as having a mucinous component of at least 50%. This type of tumor is sub classified into two groups: 'pure' mucinous carcinoma that consists solely of tumor tissue with extracellular mucin production and 'mixed' mucinous carcinoma that also contains infiltrating carcinoma without mucin. Mixed mucinous carcinomas have high grade nuclei and poorly differentiated cells.<sup>1-4,8,9</sup> Pure mucinous variety



was further sub classified as hypocellular / type A and cellular / type B based on cellularity , neuroendocrine differentiation or nuclear pleomorphism . A micropapillary pattern has also been described and is said to be more commonly associated with Axillary nodal involvement. Recently, the WHO classification divides this tumor into three different subtypes: (i) mucinous carcinoma (ii) cystadenocarcinoma and columnar cell mucinous carcinoma and (iii) signet ring cell carcinoma.<sup>1,2</sup>

The mean age at diagnosis in PMBC and MMBC is 60 years (range 34–91) and 63 years (39–90), respectively Mean age at presentation is 57 years having a lower frequency of metastasis to an axillary lymph node and a better survival rate.

Mucinous carcinoma may also occur in males. Dimitrios P and colleagues<sup>10</sup> reported a case of Mucinous breast carcinoma presenting as Paget's disease of the nipple in a man. Ingle P. and colleagues reported a case of mucinous carcinoma in a male who had Axillary lymph node involvement.<sup>11</sup> Others suggested breast conservation in early stage lesions.<sup>12</sup> A case of Pure mucinous breast carcinoma with lung metastasis in a young male patient was reported by Kertmen N and co workers.<sup>13</sup> On the other hand a case of Synchronous bilateral mucinous carcinoma of the breast was reported by Chang YW and his colleagues from Korea.<sup>14</sup>

Both the cases of this report were pure mucinous type of breast carcinoma. The reported first case presented at earlier age than is usual. This patient also had pulmonary metastasis and skeletal metastasis which is uncommon in this type of malignancy. Pulmonary metastasis also revealed same histo pathological pattern. The second case of this report is an elderly lady and had Axillary metastasis removed as a part of definitive surgical procedure. In the first of the two cases Axillary dissection was not done as none were palpable and also on the view that Axillary metastasis was not common in mucinous carcinoma and there are proponents against routine axillary dissection in such cases.<sup>11,12</sup> Both were given adjuvant chemotherapy scheduled for carcinoma breast along with anti-estrogen therapy.

Pure mucinous carcinoma has a less aggressive growth pattern, i.e. smaller tumor size, a lower frequency of adherence to the overlying skin and underlying fasciae and primary axillary lymph node

metastasis and a higher percentage of positive estrogen receptor, compared with non- mucinous carcinoma. The first case showed opposite different features i.e. larger tumor size, involvement of the overlying skin and pulmonary metastasis.

Since these tumors have low incidence of axillary metastases, some authors advocate that axillary node staging maybe unnecessary in these patients.<sup>(11,12)</sup> In our first case axilla was not explored but the second case required Axillary clearance for clinically palpable nodes. Late distant metastases may occur in these patients.<sup>(2,8)</sup> Adjuvant chemotherapy consisting of cyclophosphamide, adriamycin and 5-fluorouracil (5-FU) is given at every 3 weeks interval for 6 cycles..

Pure mucinous carcinoma of the breast has a favorable prognosis. Some studies showed a remarkably good prognosis, whereas others showed survival lasting only a few years after diagnosis. Prognosis for 'pure' lesions, with a prominent mucinous component is, much better than for the 'mixed' histology, which displayed a more prominent invasive epithelial component.

Tumor size does not appear to significantly impact survival, perhaps because the large volume of mucin may lead to overestimation of tumor burden. The number of involved axillary lymph nodes was the only significant predictor of death from disease.

#### References:

1. Yerushalmi R, Hayes M.M, and Gelmon K.A. Breast carcinoma-rare types: review of the literature, *Ann Oncol* 2009; 20 (11): 1763-1770.
2. Ranade A , Batra R, Sandhu G, Chitale R A, Balderacchi J. Clinicopathological evaluation of 100 cases of mucinous carcinoma of breast with emphasis on axillary staging and special reference to a micropapillary pattern . *J Clin Pathol* 2010; 63:1043-1047 .
3. Scoopsi L, Andreola S, Pillotti S, Bufalino R, Baldini MT, Testori A, et al. Mucinous carcinoma of the breast. A clinicopathologic, histochemical, and immunocytochemical study with special reference to neuroendocrine differentiation. *Am J Surg Pathol.* 1994; 18:702–11
4. Toikkanen S, Kujari H. Pure and mixed mucinous carcinomas of the breast: a clinicopathologic analysis of 61 cases with long-term follow-up. *Hum Pathol.* 1989; 20: 758–64

5. Komaki K, Sakamoto G, Sugano H, Morimoto T, Monden Y. Mucinous carcinoma of the breast in Japan. A prognostic analysis based on morphologic features. *Cancer*. 1988; 61:989–96.
6. Rosen PP, Lesser ML, Kinne DW. Breast carcinoma at the extremes of age: a comparison of patients younger than 35 years older than 75 years. *J Surg Oncol* 1985; 28: 90-6
7. Geschicter CF. Gelatinous mammary cancer, *Ann Surg* 1938; 108: 321-46. Cited by Komenaka I K , El-Tamer M B et al . *Am J Surg* 2004 ; 187 : 528-532.
8. Komenaka I K , El-Tamer M B , Troxel A Hamele=Bena D, Schnabel F R. Pure mucinous carcinoma of the breast . *Am J Surg* 2004 ; 187 : 528- 532.
9. Peng Li. Sun Q, Liang Z, Zhou Y, Mao F GuanJing-hong . Pure mucinous carcinoma of the breast. A clinic-pathologic analysis with 56 patients. *Chin Med Sci J* 2010 ; 25 ( 2 ) 115-118
10. Dragoumis DM, Assimaki AS, Tsiftoglou AP. Pure mucinous carcinoma with axillary lymph node metastasis in a male breast. *Breast Cancer*. 2012 ; 19(4):365-8.
11. Ingle AP, Kulkarni AS, Patil SP, Kumbhakarna NR, Bindu RS. Mucinous carcinoma of the male breast with axillary lymph node metastasis: Report of a case based on fine needle aspiration cytology; *Journal of Cytology* ; 2012; Vol. 29 : 1, p72
12. Barkley C R, Ligibel J A, Wong J S, Lipsitz S, Smith B L, Golshan M. Mucinous breast carcinoma : a large contemporary series. *Am J Sur*. 2008; 196: 549-551.
13. Kertmen N, Dogan E, Altundag K. Pure mucinous breast carcinoma with lung metastasis in a young male patient. *Am Surg*. 2010 ;76(8):E146.
14. Chang YW, Kwon KH, Lee DW *Clin Imaging*. Synchronous bilateral mucinous carcinoma of the breast: case report. 2009;33(1):62-6.