



Case Report

CAVERNOUS HEMANGIOMA OF SIGMOID COLON AND ANO-RECTUM: A RARE CAUSE OF HAEMATOCHEZIA

Tariq Akhtar Khan¹, Md. Shahadot Hossain Sheikh², Md. Ahsan Habib¹, Ismat Jahan Lima³, Md. Rayhanur Rahman⁴, Nigar Nahid⁵, Md. Omar Faruk⁶

Abstract

Cavernous hemangioma of colon and rectum is a rare disease, with no more than 200 cases reported in the literature so far. The rectosigmoid is the most common site of this disease in the gastrointestinal tract. We report a case of a 32-year-old male with recurrent episodes of per-rectal bleeding, who was finally diagnosed of cavernous hemangioma of sigmoid colon and ano-rectum. The lesion, 23 cm in length, occupied the whole circumference of the sigmoid colon and rectum extending up to the margin of the anal sphincter. Ultra-low anterior resection with hand-sewn colo-anal anastomosis and temporary loop ileostomy was carried out. The patient is in regular follow up. He is now symptom free.

Key Words: Cavernous hemangioma, Hemangioma of rectum and colon, Haematochezia.

Introduction

Cavernous hemangioma of colon and rectum is a rare disease. Since Philips' original description in 1839 of cavernous hemangiomas of the large intestine, near about 200 cases have been reported in the literature so far.¹⁻³ The recto-sigmoid is the most common site of this disease in the gastrointestinal tract.^{1,3} Lack of awareness of clinical presentation may lead to misdiagnosis, inappropriate therapy and a high mortality.^{2,4-7}. Diffuse cavernous hemangioma is the

most common type, with 50-70 percent of them located in the rectosigmoid.⁸⁻¹⁰. Recurrent, painless hemochezia is the most common presenting problem.^{1,3}.

Case Report

A 32-year-old male patient was admitted in colo-rectal surgery unit of Bangabandhu Sheikh Mujib Medical University, Dhaka with the complaints of occasional per rectal bleeding for 15 years, alteration of bowel habit and tenesmus for 8 years. Bleeding was sometimes profuse and fresh, and sometimes in the form of passage of small amount of altered blood. Bleeding was with or without bowel motion and was associated with mild abdominal pain. He was diagnosed to have hemorrhoidal disease and underwent hemorrhoidectomy 13 years back. He was asymptomatic for about 3 months there after and then his symptoms recurred. He had an attack of profuse per rectal bleeding three years back, for which he received two units of blood transfusion.

On examination he was found mildly anaemic. There was an intra-abdominal mass in left iliac region extending upto the supra-pubic region measuring about 10 cm in length, placed obliquely, nontender,

1. Junior Consultant (Surgery), MS (Phase B resident), Colo-rectal surgery, Bangabandhu Sheikh Mujib Medical University
2. Professor of colorectal surgery, Bangabandhu Sheikh Mujib Medical University
3. Junior Consultant (Surgery), MS (Thesis part student), colorectal surgery, Bangabandhu Sheikh Mujib Medical University
4. Assistant Professor (Surgery), Pabna Medical College, Pabna.
5. MD (Thesis part student), Radiology and imaging, Dhaka Medical College, Dhaka.
6. Medical Officer, Department of Surgery, Bangabandhu Sheikh Mujib Medical University, Shahbag, Dhaka.

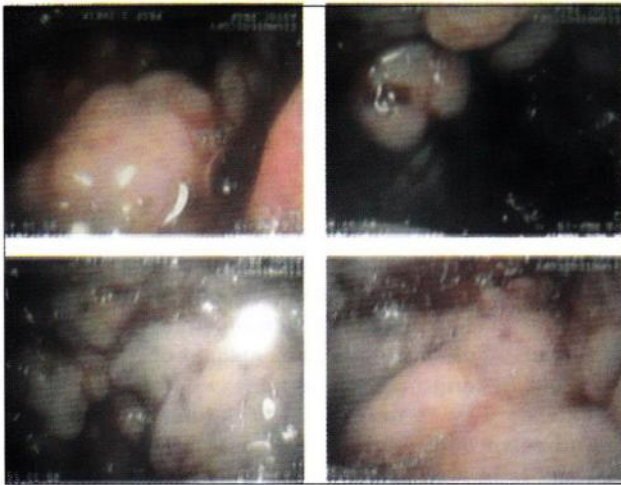
Correspondence to: Dr. Tariq Akhtar Khan, MS (Phase B resident), Colo-rectal surgery, Room no: 631, Block- C, Bangabandhu Sheikh Mujib Medical University, Shahbag, Dhaka, E-mail: tariqsurgeon@yahoo.com Tel.: +88 0171 7659303

Received 15 December 2013 **Accepted** 15 January 2014

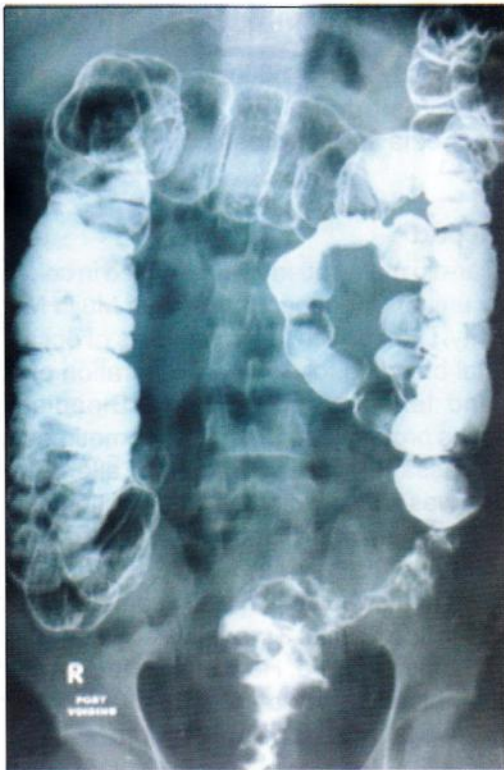with smooth surface, firm in consistency, without indentation and tympanic on percussion. Anal tone was mildly reduced. There were multiple nodular masses all around the anus, starting from 3cm of anal verge; upper limit could not be reached. The masses were firm, overlying mucosa was free. Mobility of rectal wall was reduced. Colonoscopy showed nodular protrusions (photograph-1) found 3cm to 30 cm from anal verge. Colonoscopic biopsies were taken from three sites of sigmoid colon and rectum. Histopathological report came as non specific colitis. Colonoscopy and biopsy was repeated and came as

intestinal lymphangiectasia. Ultrasonography suggested of bowel mass and multiple hepatic cysts of variable sizes. Largest one measuring about 2.3x 2.2 cm in postero-lateral aspect of the right lobe of liver. Double contrast Barium enema impression was simulating carcinoma of sigmoid colon (photograph-2). CEA level was normal. CT scan was not done due to financial constrains.

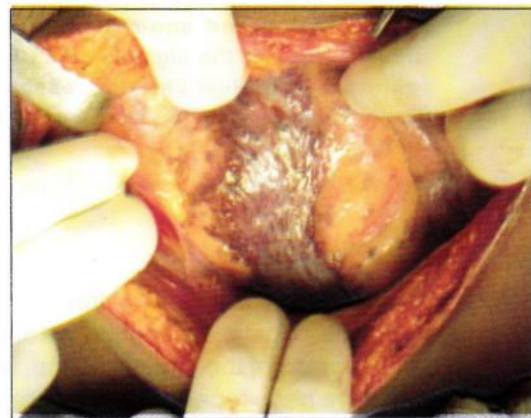
With the intention of ultra low anterior resection abdomen was opened. Large hemangioma was found in the sigmoid colon (photograph-3), rectum and anal canal near to the sphincter (photograph-4). No invasion to other organ was noticed. During pelvic dissection there was hemorrhage from unusual blood vessels. Ultra low anterior resection with colo-anal anastomosis and temporary loop ileostomy was done. On opening the 25 cm long post operative specimen (photograph-5), mucosa showed cobble stone appearance (photograph-6). Grossly two calcified nodules were found in the serosa. Histopathological sections revealed thin walled, dilated, cavernous hemangioma



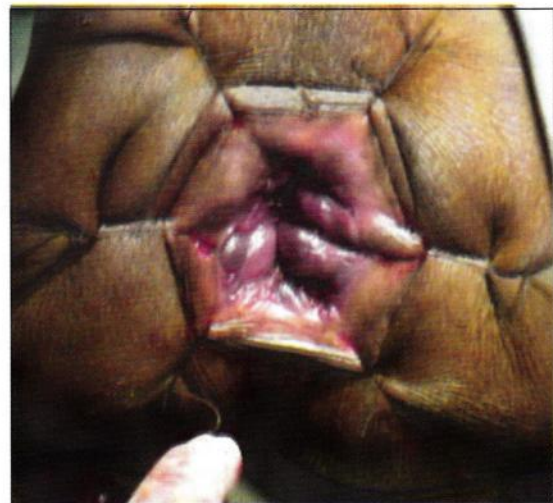Photograph-1



Photograph-2

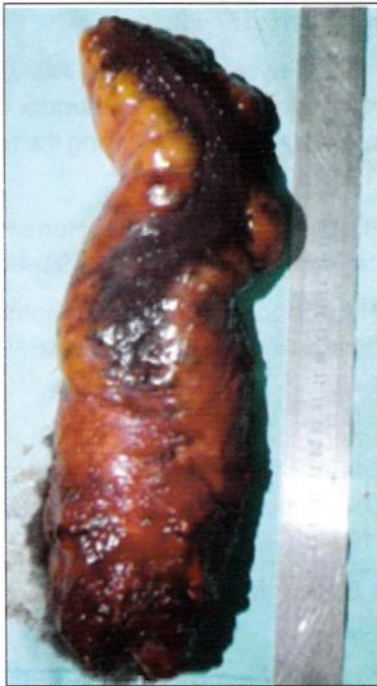

Photograph-3

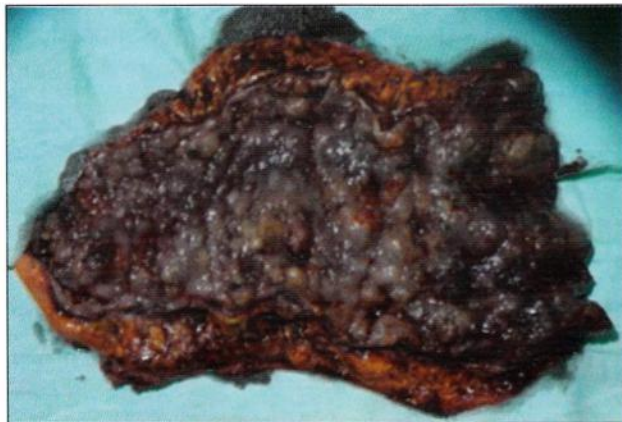


Photograph-4

filled with blood and thrombi. Distal resection margin was involved. Patient developed minor wound infection revealed on the fifth post operative day. He also developed retention of urine on removal of the urinary catheter on the third post operative day. He was catheterized again and it was removed on the fourteenth post operative day. He was discharged from the hospital on the same day with advice to come for regular follow up. He is now symptom free.



Photograph-5



Photograph-6

Discussion

Colo-rectal hemangiomas are less frequent vascular malformations. Kaiser, in 1936, popularized the pathologic classification of hemangiomas of the gastro-

intestinal tract¹². He distinguished among multiple phlebectasis, capillary and cavernous hemangiomas. The later can be circumscribed, diffuse, infiltrating, or mixed capillary. Coppa et al. reviewed the world literature and found only 85 histologically proven diffuse cavernous hemangiomas of the rectosigmoid⁹. Histologically 75 to 80 percent are the cavernous type and contain large, thin-walled, vascular channels, without true encapsulation, and typically contain more smooth muscle fibers than capillary lesions. In our case, there was a broad spectrum of vascular and lymphatic anomalies. These varied histologic findings may be explained by the three stages of embryologic development of the mesodermal stem cell. It is believed that capillary hemangiomas are an anomaly of the first stage, cavernous hemangiomas are an anomaly of the second stage, and arteriovenous fistulas are an anomaly of the third stage of stem cell development.³

The clinical presentation of a cavernous hemangioma of colon and rectum is usually acute, recurrent or chronic rectal bleeding. In 17 to 25 percent of patients, intestinal obstruction is the presenting complaint^{6,8}. Abdominal pain may be the principal complaint¹⁷. Possible compression or invasion of adjacent structures may present as lumbar or perianal pain, metrorrhagia, hematuria, etc¹. This tumor can be diagnosed as solitary, multiple, or part of a more complex syndrome with coexisting similar lesion of the gastro-intestinal tract, accessory organs, intestinal mesentery, retroperitoneal space^{8,15-16} and cutaneous manifestations^{1,3}. Local pelvic infiltration into the uterus or urinary bladder has also been described with cavernous hemangiomas^{8,16,17}. This disease commonly presents in younger age group. Colonoscopy is the diagnostic technique of choice and it allows to establish the localization, morphology, and total extension of the lesion; its characteristic image is a red-purplish nodule with great vascular congestion. But due to lack of awareness for hemangioma, we didn't noticed the typical colour. According to the opinion of most authors, biopsy is not advisable during colonoscopy^{1,3}, since imaging techniques are sufficient for an accurate diagnosis, and the risk of bleeding while manipulating this lesion is not negligible. However we didn't notice excessive bleeding from biopsy site. Shunting blood away from the submucosa and rendering the colon ischemic explain the nonspecific inflammatory changes. Abdominal radiograph shows multiple ectopic pelvic phleboliths.^{3,17} Computed tomography and particularly

magnetic resonance imaging, given their high precision to delineate the lesion and its relations to adjacent structures. Imaging studies are therefore mandatory before surgical treatment. We didn't do CT/MRI due to financial constrains. Other techniques such as selective angiography, barium enema, gastrointestinal transit, and upper-tract endoscopy may be supplementary and help locate more lesions along the gastrointestinal tract. Failure to recognize the exact diagnosis and extent of diffuse cavernous hemangioma may lead to failed surgical treatment and severe complications. Complete surgical excision of the lesion with a sphincter-saving procedure (with temporary loop ileostomy) is the primary mode of treatment and preferred by most of the author^{1,3} as it has low morbidity and preferred by the patients; though Coppa et al. advocated for abdomino perineal resection¹⁰.

Conclusion

Though colonoscopy is said to be the diagnostic technique of choice, high index of suspicion for hemangioma is needed. Otherwise one may mistake it as other neoplasm. We have a proposition that when a patient with per-rectal bleeding with or without family history or hemangioma in other sites is found to have multiple nodular growth with apparently normal looking mucosa on colonoscopy and abdominal plain X-ray shows multiple ectopic pelvic phleboliths, one should carefully look for red-purplish color of nodules during colonoscopy. Biopsy should be avoided and an abdominal CT scan or MRI should be performed to exclude hemangioma. Proper management may avoid the potential morbidity and mortality of the disease.

References

- Hervías D, Turrión JP, Herrera M, Navajas León J, Pajares Villarroya R, Manceñido N, Castillo P, Segura JM. : Diffuse cavernous hemangioma of the rectum: an atypical cause of rectal bleeding. *Rev Esp Enferm Dig.* 2004 May;96(5):346-52.
- Lyon DT, Mantia AG. Large-bowel hemangiomas. *Dis Colon Rectum* 1984;27:404-14.
- Aylward CA, Guy RO, George WL, Victor WF.: Diffuse cavernous hemangioma of the rectosigmoid-CT scan, a new diagnostic modality, and surgical management using sphincter-saving procedures, report of three cases. *Dis Colon Rectum* 1988 October;797-802
- Figliolini FJ, Cutait DE, de Oliveira MR, da Silva Bastos E. Rectosigmoidal hemangioma: report of two cases. *Dis Colon Rectum* 1961;4:349-55
- Westerholm p. A case of diffuse haemangiomas of the colon and rectum. *Acta Chir Scand* 1967;133:173-6
- Bell GA, McKenzie, Emmons H. Diffuse cavernous hemangioma of the rectum: report of a case and review of the literature. *Dis Colon Rectum* 1972;15:377-82.
- Jeffrey PJ, Hawley PR, Parks AG. Colo-anal sleeve anastomosis in the treatment of diffuse cavernous hemangioma involving the rectum. *Br J Surg* 1976;63:678-82.
- Head HD, Baker JQ, Munir RW, Hemangioma of the colon. *Am J Surg* 1973;126:691-41.
- Allred HW, Spencer RJ. Hemangiomas of the colon, rectum and anus. *Mayo Clinic Proc* 1974; 49: 739-41.
- Coppa GF, Eng k, Localio SA. Surgical management of diffuse cavernous hemangioma of the colon, rectum and anus. *Surge Gynecol Obstet* 1984;159:17-22.
- Phillips B. Surgical cases. *London Med Gax* 1839; 23: 14-7.
- Kaiser RU. Hamangiome der tractus gastrointestinalis. *Arch Klin Chir* 1936;187:351-3.
- Bland KI, Abney HT, MacGragor AM, Hawkins IF Jr. Hemangiomas of the colon and anorectum: case report and review of the literature. *Am Surg* 1974; 40: 625-35.
- Shackleford RT. Diagnosis of surgical disease. Philadelphia: WB Saunders, 1969;3
- Marishita R. Gastric hemangiomas. *Jpn Arch Intern Med* 1965;12:223-6
- Robbins SL, Cotran RS. Pathologic basis of disease. 2nd ed. Philadelphia: WB Saunders, 1979: 635-6
- Varela Gutiérrez G, Cervera Servin JA, Fernández Sobrino G, Rodríguez Delgado NA, Flores Armenta J, Robles C. [Cavernous hemangioma of the colon. Case report and review of the literature]. *Rev Gastroenterol Mex.* 2004; 69(2): 94-9. [Article in Spanish].