



## Original Article

# COMPLICATIONS OF LAPAROSCOPIC CHOLECYSTECTOMY

A.B.M. Khurshid Alam<sup>1</sup>, Mashrur Akbar Khan<sup>2</sup>, Rashed Uz Zaman<sup>3</sup>, Md. Ali Akbar<sup>4</sup>, Md. Abul Bashar<sup>5</sup>

### Abstract

**Background:** laparoscopic cholecystectomy is now regarded as the “Gold Standard” treatment option for benign gallbladder disease. But it is not free of procedure related complications.

**Objective:** To review the complications of laparoscopic cholecystectomy for gall stone disease.

**Materials & Method:** A prospective observational study was carried out over a period of 9 years beginning from 1<sup>st</sup> of July 2003 till 30<sup>th</sup> of June 2012 in Comilla Medical College Hospital and several private hospitals of Comilla. A total of 946 patients who underwent laparoscopic cholecystectomy for symptomatic and asymptomatic gallstone disease as confirmed by ultrasound scan were included. Patient having cirrhosis of liver, ischermic heart disease, suspected carcinoma of gall bladder were excluded from the study. The outcome including the complications was analyzed.

**Result:** Out of 946 patients 632 (66.80%) were females and 314 (33.19%) were males. Most (92.3%) of them were between 21-50 years of age. The commonest immediate complication was bleeding from liver bed (9.40%), from vascular injury in Callot’s triangle (5.17%) and from the trocar site (4%). There was spillage of gallstones in 104(10.99%) cases. Bowel injury was seen in only one(0.10%) case. Bile leakage was observed in 4(.42%) cases that also include CBD injury in 3 cases. The procedure was converted to open surgery in 11(1.17%) cases. Port site infection was seen in 43 (4.54%) cases. Late complications include port site hernia in 6 (0.63%) cases, port site keloid in 1 (.1%) case and CBD stricture in 5 (0.54%) cases. Mortality was unavoidable in in 2(0.21%) cases.

**Conclusion:** With increasing experience laparoscopic cholecystectomy can be a safe and effective procedure for most patients with cholelithiasis. Proper training and sound knowledge of possible complications can yield favorable results and lesser complications.

**Key words:** Laparoscopic Cholecystectomy, Cholelithiasis, Bile duct injury, Bile Duct stricture.

1. Professor & Head, Department of Surgery, Comilla Medical College Hospital.
2. Indoor Medical Officer, Department of Surgery, Comilla Medical College Hospital.
3. Registrar, Department of Surgery, Comilla Medical College Hospital.
4. Associate Professor, Department of Surgery, Department of Surgery, Comilla Medical College Hospital.
5. Junior Consultant, Department of Anaesthesiology, Comilla Medical College Hospital.

**Correspondence to:** Prof. A. B. M. Khurshid Alam, Professor & Head, Department of Surgery, Comilla Medical College & Hospital, Comilla, E-mail: alamdr2003@yahoo.com

**Received** 06 November 2012 **Accepted** 15 December 2012

### Introduction:

Open surgery has been replaced by laparoscopic cholecystectomy (LC) for the treatment of cholelithiasis. It is now regarded as the first and the “Gold Standard” treatment option for benign gallbladder disease.<sup>1,2</sup> However, During Laparoscopic cholecystectomy the risk of intraoperative injury to different structures of abdominal cavity is higher than in open cholecystectomy.<sup>3,4</sup> Still then, it is expected to

lessen the burden of procedure related injury as the surgeon performing LC gains experience.<sup>4</sup> About a million patients are newly diagnosed annually with gall stone disease in USA alone. Among them approximately 600,000 undergo surgery each year where more than 75% are done by laparoscopy.<sup>5</sup>

Laparoscopic cholecystectomy has the added advantages of minimal invasive surgery. As Laparoscopic cholecystectomy is gaining wide spread approval, the spectrum of complications in gallstone surgery has changed. The major intraoperative complications of Laparoscopic cholecystectomy include bowel, vascular and bile duct injuries. Nevertheless, this tend to decrease in time due to the increased experience of the surgeons, popularity of the procedure and introduction of newer and safer instruments.

This study presents a nine-year experience of Laparoscopic cholecystectomy and aims to evaluate its complications.

#### Material and Methods:

This prospective observational study was carried out in Comilla Medical College Hospital & several private clinics of Comilla from 1<sup>st</sup> of July 2003 till 30<sup>th</sup> of June 2012. A total of 946 patients who underwent laparoscopic cholecystectomy for symptomatic and asymptomatic gallstone disease as confirmed by ultrasound scan were included. Patient having cirrhosis of liver, ischeremic heart disease, suspected carcinoma of gall bladder were excluded from the study. Structures questionnaire was designed and pretested. Data were collected on it to include demographic profile, history & findings of clinical examination & investigations. It also included techniques and procedure of the operation, any complications with their management and follow up as well. Prophylactic antibiotics were given to all patients preoperatively. Classical Four-port approach was done in all cases. In case of suspected oozing a drain was introduced through the right iliac fossa. Patient were mobilized on the next morning and discharged on the second day with advice for follow up visit after one week to asses any complication.

#### Result:

The study included a total of 946 patients who had Laparoscopic cholecystectomy. 632 (66.8%) patients were females while rest 314(33.2%) were males. Majority (92.3%) of the patients were aged between 21-50 years. 36 (3.8%) patients were aged between 51-60 years, 25 patients (2.64%) were aged below 20 years and 11 patients (1.16%) were aged above 60 years. (Table 1)

**Table 1**  
*Distribution of patients according to Age & Sex (n=946)*

Age Group	No. of patients	%
Age<20years	25	2.64%
21-50 years	874	92.3%
51-60 years	36	3.80%
Above 60 years	11	1.16%

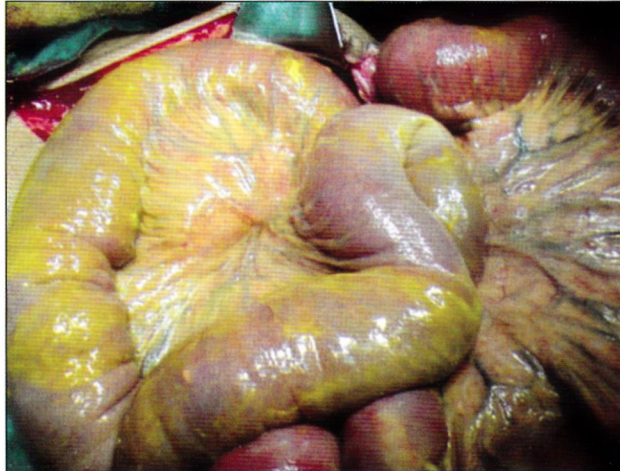
  

Sex	No. of patients	%
Male	314	33.19%
Female	632	66.80%

Routine preoperative investigations were done in all cases while liver function test (LFTs) were performed in selected cases with clinical jaundice. Ultrasonography was done in all cases. (Table-2) Gallbladder was sent for histopathology for selected cases only. Total data could not be recorded properly but 3 cases were reported as adenocarcinoma of gallbladder.

Immediate complications include bleeding during the procedure as the commonest 176(18.5%) (Table 2). Bleeding from trocar site occurred in 38(4%) cases, from vascular injury in the Callot's triangle in 49(5.1%) cases and from liver bed in 89(9.4%) cases. Gallstone spillage was the next common complication observed in 104 (10.54%) cases. In these cases most of the stones were retrieved during the procedure. Four (0.41%) patients had bile leakage. Of them three (0.31%) were due to bile duct injury. In 2 cases there were complete while partial transection occurred in one case. All 3 recognized preoperatively with laparotomy and primary repair of injured bile duct over

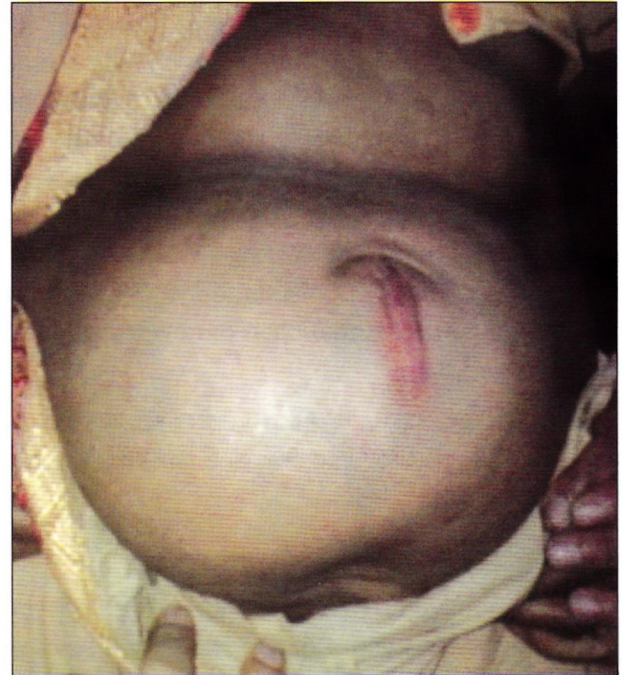a T tube. One complete and the partial injury recovered completely. But the other complete transection required re-laparotomy followed by Roux-en-Y hepatico jejunostomy. But the patient expired in postoperative period. Another patient had bile leakage that was not identified preoperatively and developed post-operative biliary peritonitis. (Figure 1)



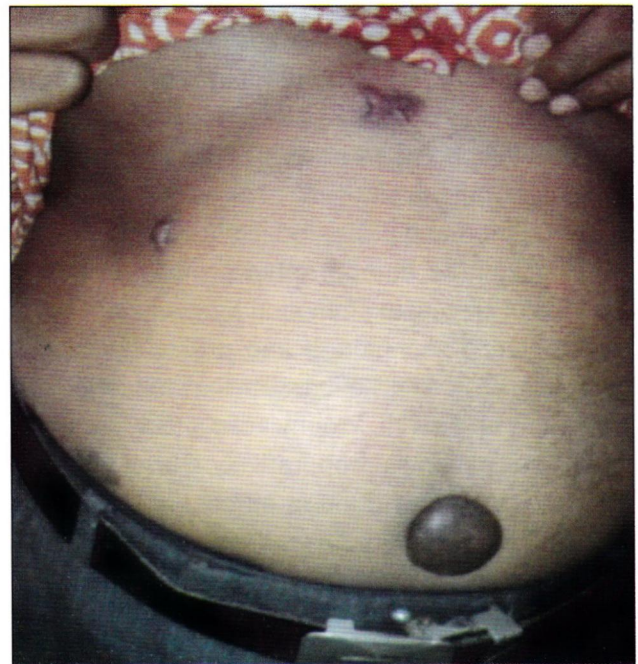**Fig.-1:** *Biliary Peritonitis*

Exploratory laparotomy failed to localize any site of injury. The patient was referred to higher center. But he did not survive. Bowel injury in the ileum occurred only in one (0.10%) patient. But unfortunately it was not recognized during the procedure and the patient required exploration on the 3<sup>rd</sup> day. Loop ileostomy was done with subsequent closure after 4 months. Conversion to open surgery was done in 11 (1.16%) cases; 3 of which were due to severe adhesion of the gallbladder to surrounding structures, 3 due to abnormal anatomy and 5 due to uncontrolled bleeding during the procedure. Early complications include port site infection in 43(4.54%) cases. Three patients (0.31%) developed basal pneumonia postoperatively which recovered after treatment with broad spectrum antibiotics and chest physiotherapy. (0.1%) patient developed localized biliary peritonitis with carbapenam resistant organism who recovered after conservative treatment with amikacin. Five (0.52%) patients came to follow up with common bile duct (CBD) stricture at late complications. All these cases develop Jaundice. Port site hernia and port site keloid were also late complications that occurred

in 6(.63%) cases and one (0.1%) case respectively (figure 2 & 3) in this series mortality was quiet low with only 2 cases (0.21%) cases, both being males and had bile duct injury with subsequent biliary peritonitis and died possibly due to septic shock. 641 patients reported for follow up after one week while the rest were lost to follow up.



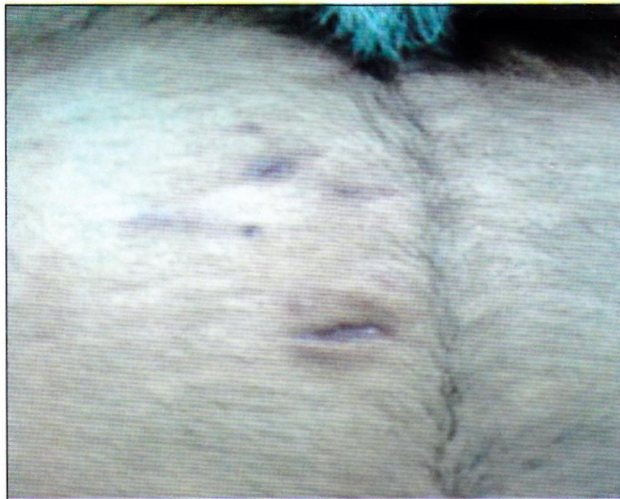**Fig.2:** *Port Hernia*



**Fig.-3:** *Port site keloid*

**Table-II**  
Complications (n=946)

	Complications	No. of Cases	Percentage(%)
<b>INTERMEDIATE or peroperative</b>	Bleeding		
	• Trocar site	38	4.00%
	• Callot's triangle	49	5.17%
	• Liver Bed	89	9.4%
	Spilled gallstones	104	10.99%
	Bile Duct Injury		
	• Complete transection	2	0.21%
	• Partial transection	1	0.10%
	Lesion not identified	1	0.10%
	Bowel injury		
	• Large bowel	1	0.1%
	Conversion to open Surgery		
	• Dense adhesions	3	0.31%
• Abnormal anatomy	3	0.31%	
• Uncontrolled bleeding	5	0.52%	
<b>EARLY</b>	Localized biliary peritonitis	1	0.10%
	Basal Pneumonia	3	0.31%
	Port site infection	43	4.54%
	• Non-Specific	38	4.00%
	• Tubercular	5	0.52%
<b>LATE</b>	Port Hernia	6	0.63%
	Port site keloid	1	0.10%
	Biliary stricture	5	0.52%
<b>MORTALITY</b>		2	0.21%



**Fig.-4:** Port site infection( tubercular)

### Discussion

Laparoscopic cholecystectomy has become gold standard treatment symptomatic cholelithiasis and chronic cholecystitis and it has practically replaced conventional open cholecystectomy. <sup>6,7</sup> Early

Laparoscopic cholecystectomy can be done in acute cholecystitis. But the results are variable with higher conversion rates. <sup>6</sup>

The laparoscopic technique for cholecystectomy is gaining wide spread popularity and approval at present it's performed in almost all major cities and medical college hospitals in our country. Laparoscopic surgery has several benefits at the cost of increased complication rate especially in training facilities. <sup>7</sup>

This study was designed to highlight different preoperative and post-operative complications of Laparoscopic cholecystectomy. In this study majority (92.3%) of the patients belonged to the age group 21-50 years while 25 (2.64%) were less than 20 years of age, mainly children with the ratio of male and female of 1:2.01. the mean age of 43.7 years with a female to male ratio of 4.5:1 was observed in a study of Laparoscopic cholecystectomy in acute cholecystitis. <sup>6</sup> In a separate study of Laparoscopic cholecystectomy on 281 cases there were 140 men and 141 women with a mean age of 56.9 years (range 23-89 years). <sup>8</sup>

We used to classical four port approach in Laparoscopic cholecystectomy in all 946 cases. In recent times needlescopic cholecystectomy using two port with 3 mm miniaturized instruments has been shown to be feasible and may yield better results in terms of pain and cosmesis.<sup>9,10</sup>

In search of better cosmesis, attempts have also been made for single incision Laparoscopic cholecystectomy with a varying results.<sup>11</sup> In our study we used open method of creating pneumoperitoneum. In one of the studies of Laparoscopic cholecystectomy, direct trocar insertion without pneumoperitoneum was shown to be safe, rapid and easily learnt technique that reduces the trocar insertion related complications.<sup>12</sup> Incidence of injuries from trocars and veress needle has been reported 0.2%.<sup>5</sup>

One of the severe and potentially fatal complication of Laparoscopic cholecystectomy is the bile duct injury and the reported incidence from several studies range from 0.5%-1.4%.<sup>13</sup> Cystic duct leak occurs in frequently. But it possess potentially serious threat. It can be reduced if locking clips are used instead of simple clips.<sup>14</sup> Bile duct injury was minimum in our series occurring in only 3(0.31%) cases. In 2 cases there were complete transection and in 1 case partial transection. All 3 cases were identified preoperatively followed by laparotomy and primary repair of injured bile duct over a T tube. One complete & partial injury recovered completely. But the other complete transection required re laparotomy followed by Roux-en-Y hepatico jejunostomy. Unfortunately, the patient died. Another case of bile leakage occurred that was not identified preoperatively. The patient developed biliary peritonitis. Exploration was done on the 3<sup>rd</sup> post-operative day. No lesion could be identified on the laparotomy. The patient was transferred to higher center but did not survive possibly overwhelming sepsis.

Commonly encountered complication in our series was vascular injury. There were 38(4%) cases of trocar site bleeding. Among them 36 cases were controlled with pressure alone while 2 cases required port site exploration and ligation of vessels. Vascular injury in the Calot's Triangle During dissection occurred in 49 (5.17%) cases and in 44 cases bleeding was controlled with clip application. However 5 cases needed conversion to open cholecystectomy for control of bleeding. Bleeding from gall bladder fossa of the liver was controlled with diathermy. In a few cases with

doubtful oozing a drain was introduced. Available data on the real incidence of bleeding complication in Laparoscopic cholecystectomy are scanty. However in a meta-analysis 163 patients out of 15,596 suffered vascular injury & required conversion with a rate of 8%.<sup>8</sup> The overall morbidity increases in concomitant vascular injuries during Laparoscopic cholecystectomy.<sup>15</sup>

During Laparoscopic cholecystectomy gallstones can get spilled into peritonea cavity frequently. It is usually due to gallbladder perforation during dissection from liver bed or during extraction through the port. It can cause complications. Every attempt should be made to retrieve spilled gallstone. But for this conversion is not mandatory.<sup>16-18</sup> The reported incidence 10 to 30%.<sup>5</sup> Formation of abscess or fistula in abdominal wall has been reported after stone spillage.<sup>16</sup> Only 1.4% of patients with spillage of gallstones during Laparoscopic cholecystectomy developed serious postoperative complications as per a retrospective study from Switzerland.<sup>5</sup> In this study, spillage of gallstone occurred in 104(10.99%) cases and ,most were retrieved during this procedure. There was no recorded postoperative complication due to spilled gallstones.

Surgical site infection occurred in 43 (4.53%) cases. 38 were non specific infection treated with antibiotics, daily dressing and debridement. Interestingly 5 were tubercular infection and needed anti-TB with other measures. One of the major benefits of minimally invasive surgery is the significant reduction in the post operative infection. The rate of surgical site infection is 2% as compared to 8% in open surgery.<sup>19</sup> In another study its reported as 1.4% in laparoscopic surgeries versus 14.8% in open cases.<sup>20</sup>

Incidence of bowel injuries in Laparoscopic cholecystectomy ranges from 0.07-0.7%. it occurs mostly during insertion of trocars and infrequently during dissection or adhesiolysis. They often remain undetected during operations.<sup>5</sup> There was only 1(0.1%) case of bowel injury in our study. It was only recognized when the patient developed postoperative abdominal distension, rigidity and other features of perforation peritonitis. She was initially treated conservatively but laparotomy was performed on the 4<sup>th</sup> day, where a perforation in ileum with edematous gut covered with was found. The affected area was trimmed followed by loop ileostomy. Closure of ileostomy was done after 4 months of interval. There have been reports of intestinal ischemia and evisceration of small bowel following Laparoscopic

cholecystectomy.<sup>21,22</sup> Open method of trocar placement under direct vision and inspection of abdomen before withdrawing laparoscope can prevent bowel injury.<sup>5</sup>

In this series conversion to open surgery was done in 11(3.13%) patients. It was due to the severe adhesion of the gallbladder with the surrounding structures namely duodenum and transverse colon in 3 cases. In 5 cases it was due to vascular injury during Laparoscopic cholecystitis where bleeding could not be controlled with routine methods and in 3 cases it was due to the abnormal anatomy. Tayeb M et al, identified in their study two

preoperative risk factors for conversion namely ultrasonographic signs of inflammation and age more than 60 years.<sup>23</sup> According to Al Salamah, distorted anatomy in the region of Calot's triangle is the most common cause of conversion observed in 41.5% of converted cases. Male gender, age over 65 years, high leukocyte count, gallbladder wall thickness more than 4 mm on USG were other significant determinants for conversion to open procedure.<sup>6</sup> In a series of 1220 patient from a single centre reported the conversion rate of 1.88%.<sup>24</sup>

One of the dreadful complications of Laparoscopic cholecystectomy is Bile duct injury. It may cause post operative benign biliary stricture after a few months. It increase the morbidity and mortality related to the procedure.<sup>25</sup> Late post operative strictures are usually the result of biliary reconstruction for injury following cholecystectomy or excessive use of electrocautery near CBD.<sup>26</sup> In this series CBD injury occurred in 4 case with 2 fatal outcome. Rest of the 2 patient did not report any late biliary stricture. Surprisingly five other patients reported later on with development of mild jaundice postoperatively. All these patients had post-operative ultrasound scan of mild dilatation of proximal biliary tract. They were diagnosed as cases of post-operative biliary stricture and were referred to higher center for further management like ERCP.

Other complications in our study include port site hernia in 6 cases, all being at the umbilical port and port site keloid in one case. Repair of port site ventral hernia was done at an interval of 4 months to 2 years with only polypropylene mesh in early period and with mixed polypropylene and polygalactin mesh in recent time. Port site defects bigger than 5mm diameter should be closed at facial level. Removal of gallbladder

should be done through the epigastric port to prevent enlargement of umbilical port with subsequent development of port site hernia.<sup>22</sup> One of our patients developed localized biliary peritonitis with carbapenam resistant strains of organism. The patient will initially treated with 4<sup>th</sup> generation cephalosporine but ultimate improved after introduction of Amikacin. Three patients developed basal pneumonia post operatively but recovered after treatment with broad spectrum antibiotics and chest physiotherapy.

We were fortunate to have low mortality in our series with only 2 cases(0.21%) both were males and had biliary injury with its subsequent complications. Others have reported a morbidity of 2.9% with no mortality.<sup>6</sup>

Average hospital stay was 2 days in our study. Similar report as 2.29 days including the prolonged stay in complicated cases was shown in a study from a single centre.<sup>23</sup> Despite the above mentioned complications the overall outcome was satisfactory with better acceptance of the procedure by the patients.

### Conclusion:

In the era of wide spread adoption of laparoscopic technique for various surgical procedures Laparoscopic cholecystectomy remains the most frequently performed minimally invasive surgery. The associated mortality and morbidity is quite low. It's the proven safety and efficacy for almost all patient with cholelithiasis. The main factors behind the complications are lack of experience and/or knowledge of the typical errors.

To accomplish favorable outcome the surgeon should acquire adequate training, and select rationally patients with proper preoperative work-up to lower the threshold for conversion and have the detailed knowledge of possible complications to make it a safer procedure.

### References:

1. Ji W, Li LT, Li JS. Role of laparoscopic subtotal cholecystectomy in the treatment of complicated cholecystitis. *Hepato Biliary Pancreatic Dis Int* 2006; 5(4): 584-9
2. Ros A, Carlsson P, Rahmqvist M, Bachman K, Nilsson E. Non randomized patients in a cholecystectomy trial: Characteristics, Procedure & outcomes. *BMC Surge* 2006;6:17
3. Hasl DM, Ruiz OR, Baumart J, Gerace C, et al. A prospective study of bile leaks after laparoscopic

- cholecystectomy surgEndosc 2001;15:1299-1300
4. Hobbs MS, Mai Q, Knuiman MW, et al. Surgeon experience and trends in intraoperative complication in laparoscopic cholecystectomy
  5. Shamiyeh A, Wanyand W. Laparoscopic cholecystectomy: early and late complication and their treatment, Langenbecks arch. Surg 2004;389:164-17
  6. Al-Salamah SM. Outcome of laparoscopic cholecystectomy in acute cholecystitis. J Coll Physicians Surg Pak 2005;15(7):400-3
  7. Cawich SO, Mitchell DI, Newnham MS, Arthurs M. A comparison of open and laparoscopic cholecystectomy done by a surgeon in training. West Indian Med J 2006;55(2):103-9
  8. Chau CH, Siu WT, Tang CN, Ha PY, et al. Laparoscopic cholecystectomy for acute cholecystitis: The evolving trend in an institution. Asian J Surg 2006;29(3):120-4
  9. Curro G, Lapichino G, Lorenzini C, Palmeri R, Cucinotta E. Laparoscopic cholecystectomy in children with chronic hemolytic anemia. Is the outcome related to the timing of the procedure? SurgEndosc 2006;20(20):252-5
  10. Lee KW, Poon CM, Leung KF, Lee DW, Ko CW. Two port needlescopic cholecystectomy: Prospective study of 100 cases. Hong Kong, Med J 2005;11(1):30-5
  11. Mehmood Z, Subhan A, Ali N, et al. Four port versus single incision laparoscopic cholecystectomy. J of Surgery Pakistan (International) 2010;15(3):122-124
  12. Prieto Diazchavez E, Median Chavez J, L Gonzalez Ojeda A, et al. Direct trocar insertion without pneumoperitoneum and the veress needle in laparoscopic cholecystectomy: a comparative study. ActaChirBleg 2006;106(5)
  13. Frilling A, Li J, Weber F, Fruhaus NR, et al. Major bile duct injuries after laparoscopic cholecystectomy: a tertiary center experience. J GastrointestSurg 2004;8(6):679-85
  14. Rohatgi A, Widdison AL. An audit of cystic duct closure in laparoscopic cholecystectomies. SurgEndos 2006;20(6):875-7
  15. Tzovaras G, Dernvenis C. Vascular injuries in laparoscopic cholecystectomy: an underestimated problem. Dig Surg 2006;23(5-6):370-4
  16. Lin CH, Chu HC, Hsieh HF, Jin JS, et al. Xanthogranulomatous panniculitis after spillage of gallstones during laparoscopic cholecystectomy mimics intra-abdominal malignancy. SurgLaparoscEndoscPercutan Tech 2006;16(4):248-50
  17. Loffeld RJ. The consequence of lost gallstones during laparoscopic cholecystectomy. Neth J Med 2006;64(10):364-6
  18. Zehetner J, Shamiyeh A, Wayand W. Lost gallstones in laparoscopic cholecystectomy: all possible complications. Am J Surg 2007;193(1):73-8.
  19. Boni L, Benevento A, Rovera F, Dionigi G, et al. Infective complications in laparoscopic surgery. Surg Infect(Larchmet) 2006;2006;7supply2:5109-11
  20. Chuang SC, Lee KT, Chang WT, Wand SN, et al. Risk factors for wound infection after cholecystectomy. J Formos Med Asso 2004;103(8)
  21. Leduc LJ, Metchell A. Intestinal ischemia after laparoscopic cholecystectomy. JSLS 2006;10(2):236-8
  22. Baldassarre GE, Valenti G, Torino G, Prosperi Porta I, et al. Small bowel evisceration after laparoscopic cholecystectomy report of an unusual case. Minerva Chir 2006;6(2):167-9
  23. Tayab M, Raza SA, Khan MR, Azami R. Conversion from laparoscopic to open cholecystectomy; multivariate analysis of preoperative risk factors J Postgrad Med 2005;51(1):17-20;21-2
  24. Vagenas K, Karacankos SN, Spyropoulos C, et al. Pararoscopic cholecystectomy: a report from a single center. World J Gastroenterol 2006;12(24):3887-90.
  25. Sikora SS, Pottakkar B, Srikanth, et al. Postcholecystectomy benign biliary strictures - long term results. Dig Surg 2006; 23(5-6):304-12
  26. Hochstader H, Bekavac Beslin M, Doko M, et al. Functional Liver damage during laparoscopic cholecystectomy