



## Original Article

# MANAGEMENT OF DISTAL PENILE HYPOSPADIAS BY TUBULARIZED INCISED PLATE URETHROPLASTY: STUDY OF 30 CASES

Nasir Uddin Mahmud<sup>1</sup>, Md. Serajul Haque<sup>2</sup>

### Abstract

**Background:** Hypospadias is the result of failure of fusion of the urethral folds on the ventral aspect of the penis. It usually occurs 1 in every 300 male children. Reconstruction of urethra in childhood is the only hope of cure. The aim of this study is to find out the outcome of tubularized incised plate urethroplasty for distal penile hypospadias and to show that this procedure will end up in a better cosmetic appearance.

**Methods:** This prospective study was conducted in a private medical college hospital, Comilla between July 2011 to June 2012 on 30 patients using Snodgrass technique of hypospadias surgery. All cases were consecutively selected. Data were processed and analysed using software SPSS (Statistical Package for social Sciences) version 11.5 and the test statistics used to analyse the data were descriptive statistics and Z-test for proportion. The variables studied were age, socioeconomic condition, post-operative complications, such as infection rate, urethrocutaneous fistula, meatal stenosis, wound dehiscence etc. & cosmetic outcome such as size of the meatus, shape of the glans studied.

**Results:** Satisfactory results were obtained in 21 (70%) patients and only 8 (26.67%) had urethrocutaneous fistula, 1 (3.33%) had retrusive meatus and 7 (23.33%) had wound infection. The final outcome was evaluated based on urethrocutaneous fistula and cosmesis. Out of 30 patients, 21 (70%) did not have urethrocutaneous fistula and were cosmetically acceptable. Binomial test based on Z-approximation reveals that observed proportion of patients with satisfactory outcome was statistically significant ( $p = 0.05$ ).

**Conclusion:** This study concludes that Snodgrass urethroplasty has better cosmetic outcome. Thus we recommended it as the primary treatment for the children with distal hypospadias.

**Key words:** Penile hypospadias, Urethroplasty, Reconstruction of urethra.

### Introduction:

Hypospadiology is defined as the study of art and science of surgical correction of hypospadias, is currently flourishing. The term 'hypospadias' is derived from the Greek language and refers as a rent (spadon) on the ventrum of the penis.<sup>1</sup>

It is occurring in approximately 3.2 per 1000 male livebirths<sup>2</sup>. Among them 65% are of distal variety

(Glanular, Coronal & ant. penile)<sup>3</sup>. Fathers of affected boy's have an 8% incidence of hypospadias; male sublings 14%<sup>4</sup>.

Hypospadias may be manifested classically as an association of three anatomical anomalies of the penis: (1) an abnormal ventral opening of the urethral meatus which can be located anywhere on the ventral aspect of the penis or in the perineum, (2) an abnormal ventral curvature of the penis (chordee), and (3) an abnormal distribution of the foreskin around the glans with the ventrally deficient hooded foreskin. The chordee and the hooded foreskin are common but not constant. Significant degree of chordee are present in about

1. Assistant Professor of Surgery, Central Medical College,  
2. Associate Professor of Urology, Comilla Medical College, Comilla  
**Correspondence to:** Dr. Nasir Uddin Mahmud, Assistant Professor of Surgery, Central Medical College, Comilla, Email: drnasir\_mahmud@yahoo.com

Received: 23 July 2012

Accepted: 20 May 2013



35% of patients with hypospadias; the most common anomalies associated with hypospadias other than chordee and hooded foreskin, are undescended testes and inguinal hernia. A 9.3% of patients with hypospadias had an undescended testes<sup>5</sup>.

Hypospadias repair is technically difficult and the results are often far from optimal. Despite extensive advances in surgical technique, the use of fine materials, delicate instrument, proper tissue handling, advances in anesthesia, hypospadiac patients faces a lot of complications.

>80% patients with hypospadias have a meatus in coronal and subcoronal position<sup>6</sup>.

Warren Snodgrass (1994) described a procedure for distal hypospadias repair with combination of incising urethral plate and a meatal based flap with a low complication rate and better cosmetic outcome<sup>7</sup>.

The aim of surgical repair is to provide a normal looking straight penis with vertically oriented meatal opening at the tip of the glans with good flow of urine.

Very few works have been done on hypospadias in Bangladesh. This problem requires to be studied more for its further development in our country. Thus we at Central Medical College Hospital in department of surgery started hypospadias surgery during the last few years. We are facing a lot of postoperative complications. Among them stent blockage, signs of infection, sloughing of skin flap, persistence of cordee, meatal stenosis, urethrocutaneous fistula are more marked and urethrocutaneous fistula is the most common complication.

To overcome our problems, we modified our surgical technique and suture material but still the result is not satisfactory. The aim of surgical repair is to provide a normal looking straight penis with meatal opening at the tip in a single-stage procedure and our previous experience showed that this could be achieved easily in majority cases with distal hypoapadias by tubularized incised plate urethroplasty (Snodgrass procedure).

**Materials and methods:**

This is an interventional prospective study. Patients of distal penile hypospadias (coronal, subcoronal, distal penile), age 2 years to 15 years with no history of pervious operation in the genital organ attending at Central medical college hospital for surgical correction were selected.

Patients with distal hypospadias age bellow 1 year and over 15 years, having glanular, mid penile & proximal variety of hypospadias, ambiguous genitalia

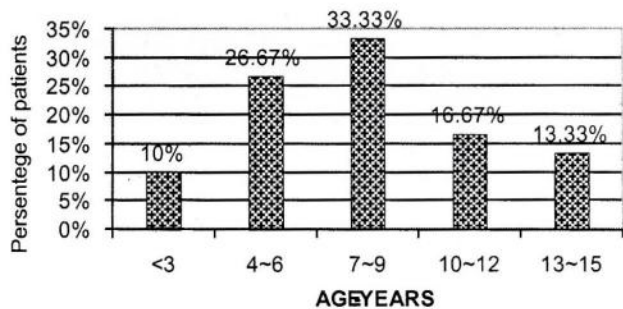
and with other major surgical problems e.g. myelomeningocele, malignant disease were excluded. All guardian of the patients were given an explanation of the study and informed consents were obtained. Their knowledge and attitude about inclusion and exclusion criteria were assessed by talking interview using a standardized questionnaire.

Total 30 cases were selected for clinical study, all patients were treated surgically by Snodgrass technique. All these 30 patients were followed up at 3 months and maximum up to 6 months. In this series post-operative analgesia was maintained with per rectal diclofenac suppository and paracetamol and also by the effect of caudal anaesthesia. To minimized bladder spasm antispasmodic was used liberally. In few cases injection pethidine was used through intramuscular route. The post-operative hospital stay was 7-10 days.

**Results:**

**1. Age distribution:**

Patients who were between 3 to 15 years old were selected in the study. The mean age was found 7.5 years.

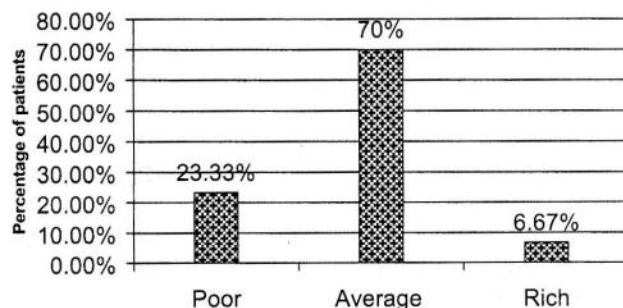


**Fig.-1:** Age Variation at the time of presentation of study group.

**2. Socio-economic conditions:**

In our study, we considered the socio-economic conditions of the hypospadias patients and the highest percentage of patients belonging to average families, constituting a number of 70%.

**3. Consanguinity:**



**Fig.-2:** Socio-economic conditions of study group of patients.



In this study one patient was detected as coming from consanguineous family.

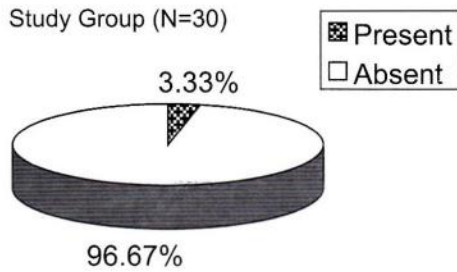


Fig.-3: Consanguinity.

**4. Presence of chordee and meatal stenosis:**

In our study 21 patients presented with chordee and 16 patients presented with meatal stenosis. Distribution regarding chordee and meatal stenosis has been shown in table.

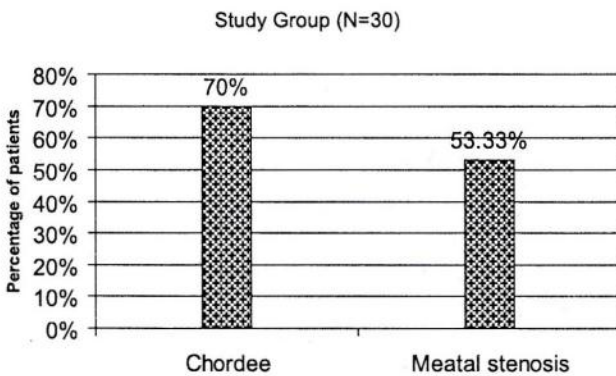


Fig.-4: Presence of chordee and meatal stenosis in the study group.

**5. Associated anomalies:**

In our observations, associated hernia was two patients and only one patient presented with undescended testes.

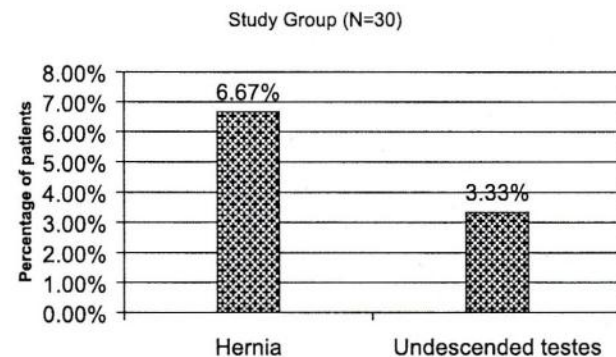


Fig.-5: Presence of associated anomalies in the study group.

**6. Complications:**

- A) Urethrocutaneous fistula: Urine coming out other than neourethral orifice and opening found in and around the neourethral line. Urethrocutaneous fistula developed in 8 (26.67%) patients.
- B) Meatal stenosis: patients complaining of narrow stream and urethral opening found to be narrowed. Meatal stenosis developed in 4 (13.33%) patients.
- C) Unsatisfactory glans cosmesis: patients or patients parents are not satisfied with glans appearance and confirmed by examination. Glans appearance was unsatisfactory in 3 (10%) patients.
- D) Retrusive meatus: the newly constructed meatus was not in the place of penile tip as complained and examined. Retrusive meatus developed in 1 (3.33%) patient.
- E) Sloughing of skin: the rotated flap skin was found to be blackened and sloughed. Sloughing of skin flap occurred in 3 (10%) patients.
- F) Deflected flow of urine: the urine flow was not oriented vertically or horizontally as noticed by patients and confirmed by observation. Deflected stream of urine noticed in 2 (6.67%) patients.
- G) Infection: discharge was noticed at operation site and confirmed by culture and sensitivity. Post-operative infection rate was present in 7 (23.33%) patients.

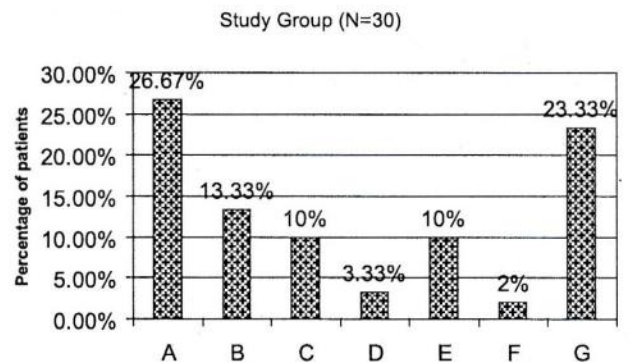


Fig.-6: Complications after surgical method in the study group.

- A - Urethrocutaneous fistula, B – Meatal stenosis, C – Unsatisfactory glans cosmesis, D – Retrusive meatus, E – Sloughing of skin flaps, F – Deflected flow of urine, G – Infection.



### 7. Post-operative final outcome:

Table-I shows the distribution of patient by final outcome. The final outcome was measured as satisfactory or unsatisfactory. Of the total 30 patients 70% exhibited satisfactory outcome in terms of no urethrocutaneous fistula and acceptable cosmetic appearance. Z-test demonstrates that observed proportion of is statistically significant ( $p = 0.05$ ).

**Table-1**

*Distribution of subjects by final outcome (n = 30)*

Final outcome	Frequency	Percentage	Z-value	p-value
Satisfactory	21	70.0	> 1.96	0.043 <sup>S</sup>
Unsatisfactory	09	30.0		

S = Significant

### Discussion:

In the present study average age of the patients was 7.58 years. We have found that most of the patients presented to the hospital at their 3-7 years of age which were comparable to other studies<sup>8</sup>. No conclusive data have been sorted out on the timing of presentation of hypospadias. Schultz and Colleagues<sup>9</sup> pointed out that an ideal time for hypospadias repair should be age 6-18 months to minimize the emotional effect of this traumatic insult. Our observation is that parents of this group of anomaly usually like to treat the problem before school going age.

Children from average families constituted 21(70%) was the highest sufferer followed by the poor class 7(23.33%) and the least was in rich class 2(6.67%), which was comparable to another study.

Majority (70%) of the hypospadias patients was rural residents whose monthly family income was found to range from 5000 – 10000 Tks. This finding contrasts with findings of Masud (1998), Alam (2000) and Haque (2005) who reported preponderance of poor patients in their studies (65%, 60% and 75% respectively). Only one patient has had the history consanguinity (3.33%). Although genetic factors is the etiology of hypospadias are certainly indicated by the higher incidence of the anomaly in the first-degree relatives of hypospadias patients<sup>10</sup>.

Chordee was present in 21 (70%) patients. The chordee was composed of only skin or only fibrous tissue or a mixture of both. Hundrad percent of scrotal

or perineal hypospadias has severe chordee<sup>11</sup>. Chordee was present 86.46%, 93.33% & 73.33% in (Masud, 1998; Alam, 2000; Haque, 2005) study respectively.

The abnormal location of the meatus and the tendency towards meatal stenosis results in a ventrally deflected and splayed stream of urine in hypospadias. Mild to moderate or severe form of meatal stenosis may be associated with any variety of hypospadias in our study. Over half (53.33%) had meatal stenosis ranging from mild to moderate grade which is consistent with the findings (60%) of Haque (2005).

Nine to thirteen percent hypospadias are associated with hernia and undescended testis, with higher incidence when the meatus is more proximal in location<sup>12</sup>, in this study two (6.67%) patient has associated hernia and one (3.33%) has undescended testis.

The operative procedure performed in our patients was Snodgrass procedure. For all cases, we followed the principles of plastic surgery regarding fine instruments and fine suture materials along with precise and delicate tissue handling.

All patients were operated under general anaesthesia. Skin hooks were used to prevent over handling of the tissues. We preferred 5/0 Polyglycolic acid suture material with a continuous running suture for constructing the neourethra and chromic 5/0 catgut suture for the skin. Hemostasis was maintained by tourniquet for 20 to 30 minutes duration and by using a low current diathermy.

Urinary diversion was provided by means of placing a feeding tube (6Fr, 7Fr, 8Fr etc.) in the neourethra and sutured to the glans and attached to thigh by micropore to prevent traction injury. The outer sheath of 3cc disposable syringe was interposed between feeding tube and urobag. A compression dressing was applied with gouge soaked with povidon iodine to provide immobilization with prevention of hematoma and oedema. Although distal hypospadias repair can be performed without a stent, the complication rate is lower when a stent is left indwelling for 3 to 6 days<sup>13</sup>.

In our study mean operation time consumed was 93 minutes. In original study by Snow et al., (1995)<sup>14</sup> additional 15-20 minutes of operative time is mentioned.

Urethrocutaneous fistula was developed in 8 (26.67%) patients. It was 34.38%, 33.33% and 23.3% in



different studies in of Bangladesh (Masud, 1998; Alam, 2000; Haque, 2005). Urethrocutaneous fistulas are likely to remain an inherent risk of hypospadias repair for many years afterward. The result from failure of healing at some points along the neourathral suture line and can range from pin point to large enough for all voided urine to exit at this point. Fistulas may be associated with stenosis or distal stricture. Occasionally, small fistulas seen early post-operatively may close spontaneously. No attempt should be made to close the fistula for 6 months. To avoid fistulation, it is important to test the repair by injecting saline to identify the gaps in the suture line Duckett,(1995); Marshal, (1998)<sup>15</sup>.

Post-operative infection developed in 7 (23.33%) cases. It developed in 10% in Haque, (2005) study. Every effort should be made to prevent wound infections. Separation of the foreskin adherent to the glans and removal of desquamated epithelial debris should be done under anaesthesia prior to skin preparation.

Prophylactic antibiotics are of little value in avoiding wound infections in hypospadias surgery. However, post-operatively, trimethoprim-sulpa or nitrofurantoin suppression may be helpful to prevent cystitis.

Retrusive meatus developed in 1 (3.33%) cases. It is caused by the failure of the glans closure or the breakdown of the devascularised neourethra. Correction can usually be accomplished by a repeat glansplasty or a meatal based flap. It is comparable to other series (Haque, 2005).

Meatal stenosis was presents in 4 (13.33%) cases, which is similar to another study (Haque, 2005). The meatus become stenotic by crusting, oedema or synachia. A stent left in place usually avoids all three complications. A narrowing of the meatus may be alleviated by simply elevating a glans flap, excising the scar beneath, and interdigitating the skin flap.

Unsatisfactory glans cosmesis was noticed in 3 (10%) cases. Glanuloplasty and in situ tabularization of the urethral plate is an excellent technique for the majority of the boys with distal hypospadias, producing a cosmetic result superior to the Mathieu procedure or MAGPI. Skin necrosis was noticed in 3 (10%) cases. It is due primarily to ischemic flaps. If care is taken during the procedure, the problem should be avoided. Deflected stream of urine was a problem in 2 (6.67%) cases.

Satisfactory operative outcome resulted from Snodgrass technique might be due to following factors

- The key step in the procedure is the deep sagittal incision of the urethral plate, which allows for its subsequent tubularization. This step essentially mimic normal closure of the urethral folds.
- Additional skin flaps are not required to create neourethra.
- In this technique only one suture line is necessary, saving operating time and decreases the possible risk of urethrocutaneous fistula.
- The deep incision of the urethral plate does not compromise its viability.
- The dorsal incision into the urethral plate re-epithelializes without obvious scarring.

The final outcome was evaluated based on urethrocutaneous fistula and cosmesis. Out of 30 patients, 21(70%) did not have urethrocutaneous fistula and were cosmetically acceptable. Binomial test based on Z-approximation reveals that observed proportion of patients with satisfactory outcome was statistically significant ( $p = 0.05$  as calculation was done by SPSS).

#### Conclusion:

Perfect repair of hypospadias is yet challenging in our perspect. Resultant neourethra should be uniform in caliber; a vertically oriented slit-like normal appearing meatus should be formed at the tip of the glans which is cosmetically more acceptable. The glans configuration should also normal looking conical in shape.

#### References:

1. Mouriquand, Persad PDE, Sharma RS. Hypospadias repair: Current principles and procedures. *Brit. J. Urol* 1995; (Suppl 3):9-12.
2. Arey L. The incidence of Hypospadias in Sweden. *Scand J Plast Reconstr Surg* 1975; 11:15-23.
3. Sevensson, J. Berg, G. Operated Hypospadias: late follow up, Social, Sexual and psychological adaptation. *J paediatric surg* 1981; 16:134-5.
4. Duckett JW. Hypospadias repair, in O, donnel. B(ed) *Paediatric urology*, ed 3. Surrey, England, Butterworth Co. 1997; 551-68.
5. Moreno MA., Slijper M., Slob AK. Satisfaction with penile appearance after hypospadias

- surgery: The patient and surgeon view. The journal of urology 1996; 155: 703-706.
6. Devine CJ, Horton CEA. one stage Hypospadias repair. J. Urol. 1961; 85: 166-172.
  7. Snodgrass W. 1994, Tubularized, incised plate urethroplasty for distal hypospadias, the journal of urology 1994; 164: 464-465.
  8. Masud AKMM. Hypospadias surgery: A short outcome (Thesis) Dhaka university 1998 ;61-70.
  9. Schultz JR, Klykylo WN, and Wacksman J. Timing of elective Hypospadias repair in children. Pediatrics 1983;71:342-351.
  10. Bauer SB, Retik AB, Colodony AH. Genetic Aspects of Hypospadias . Urol Clin North Am 1981 ;8: 559-564.
  11. Retik AB, Mandell, J, Bauer, Atala BS. A Meatal based hypospadias repair with the use of a dorsal sub coetaneous flap to prevent Urethrocutaneous fistula, The journal of urology 1994; 152: 1229-1231.
  12. Khuri, Hardy FJ, Churchill BE. Urologic anomalies associated with Hypospadias, Urol clin N Am 1981; 8: 565-571.
  13. Buson, Smiley H, Reinberg DY. Distal hypospadias repair without stents: Is it better. The journal of urology 1994; 151: 1059-1060.
  14. Snow BW, Cartwright PC, Unger K. Tunica vaginalis blanket wrap to prevent Urethrocutaneous fistula: An 8 year Experience. J Urol 1995; 153:472-3.
  15. Marshall M, Johnson SH, Price SE. Urethroplasty with concurrent scrotoplasty for repair of Hypospadias . J Urol 1979;121:335-339.