



## Case Report

### CASE REPORT ADRENAL MYELOLIPOMA

Abu Taher Md Ashaduzzaman<sup>1</sup>, M Ibrhim Khalil<sup>1</sup>, ABM Jamal<sup>2</sup>.

#### Abstract

Adrenal myelolipoma is a rare tumor that is benign in nature, usually asymptomatic, unilateral and nonsecreting. With the widespread use of imaging modalities such as ultrasonography the incidental detection of these tumors are increasing in frequency. We report a case of adrenal myelolipoma in a 45-year-old female who presented with pain in the right upper abdomen, headache and hypertension. Myelolipoma as an incidental diagnosis might keep in mind and evaluate accordingly to validated protocol because of surgical emergencies such as spontaneous retroperitoneal hemorrhage.

**Key words:** Adrenal tumor, Myelolipoma, Adrenalectomy

#### Introduction

Adrenal myelolipoma is a rare benign tumour of the adrenal gland. These tumors were initially described by Giercke in 1905, and 24 years later, Oberling coined the term myelolipoma.<sup>1</sup> They are composed of mature adipocytes and normal hematopoietic tissue.<sup>2</sup> Lately, due to widespread use of radiological studies such as Ultrasonography, CT and magnetic resonance imaging (MRI), incidental discovery of indolent adrenal myelolipomas has become more common.<sup>3</sup> According to Akamatsu et al, its incidental detection has become more common, reaching up to 7% of the adrenal masses. Most of the time these tumors are asymptomatic. When they are symptomatic they usually present with pain abdomen. The well recognized complication of adrenal myelolipoma is spontaneous retroperitoneal hemorrhage and vomiting. There was no history of haematemesis

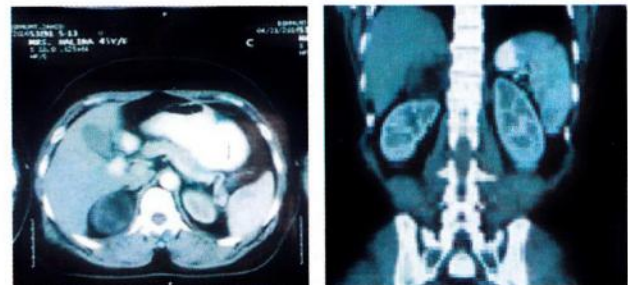or melena, and her bowel & bladder habit is normal. She was newly diagnosed hypertensive for last 4 months which was not associated with palpitation, dyspnoea or pallor and was under control with antihypertensive drugs (amlodipine 5 mg). Patient also complaint of mild headache over the last 1 month which was not associated with excessive sweating or blurred vision. Patient gave no history of weight loss, anorexia or bone pain. Patient is non diabetic and non asthmatic. The physical examination was unremarkable. Routine investigations such as haematological parameters were within normal limit. Serum electrolytes were within normal limit. Plain X-Ray abdomen shows no abnormal soft tissue mass lesion /any calcification. X -Ray chest and echocardiography shows normal findings. Ultrasonography revealed echogenic SOL in right lobe of liver measuring 5.09 x 4.23 cm in size just above the upper pole of right kidney. Contrast enhanced CT scan of abdomen showed well defined mildly enhancing mixed density lesion measuring about 5.8 cm x 4.7 cm is noted in right adrenal gland suggestive of myelolipoma. (Figure 1)

#### Case presentation

A 45-year-old female patient presented with pain in the right upper abdomen for last one month. The pain was continuous, dull aching, gradual in onset, not associated with fever

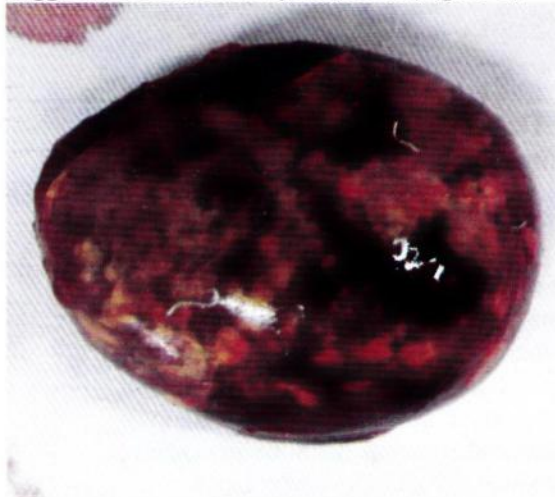
1. Assistant Professor, Department of Surgery, Dhaka Medical College Hospital, Dhaka.
2. Associate Professor, Department of Surgery, Dhaka Medical College Hospital, Dhaka.

**Correspondence to :** Dr. Abu Taher Md. Ashaduzzaman, Assistant Professor, Department of Surgery, Dhaka Medical College Hospital, Dhaka. Mobile No: 01712521953, Email: atmasad2014@gmail.com

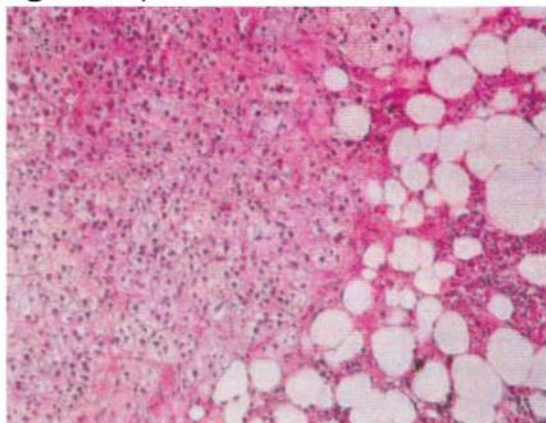


**Figure 1.** CT scan of mass

The 24 hours urinary excretion of cortisol and VMA level were normal. She underwent open right adrenalectomy through right subcostal incision. The specimen size was 5.5 x 4 cm (Figure 2). Postoperative recovery was uneventful. Histopathologic examination was suggestive of adrenal myelolipoma (Figure 3).



**Figure 2.** Specimen after removal



**Figure 3.** Histopathological photograph

### Discussion

Myelolipoma is a rare, benign and endocrinologically inactive neoplasm. The reported incidence of adrenal myelolipoma ranges from 0.08 to 0.4% and constitutes 15% of all adrenal incidental masses. This tumour affects both genders equally and is commonly found in the fifth to seventh decade.<sup>4</sup> In the majority of the cases, adrenal myelolipomas are unilateral and rarely exceeds 4 cm. However, very large and bilateral myelolipomas have been reported. Tumours exceeding 8 cm are referred to as giant myelolipomas.<sup>5</sup> Adrenal myelolipoma in association with Cushing's syndrome, Conn's syndrome and congenital adrenal hyperplasia due to 21 alpha-hydroxylase or 17 alpha-hydroxylase deficiencies have been reported.<sup>6</sup> Ultrasonography, computed tomography and MRI are all effective in diagnosing more than 90% of adrenal

myelolipoma on the basis of identification of fat, with CT scan being the most sensitive.<sup>7</sup> Due to their high fat content, they have a very characteristic appearance on imaging studies. Myelolipoma of the adrenal and extra-adrenal gland are usually asymptomatic but larger lesions can cause symptoms from mass effect, necrosis or haemorrhage.<sup>8</sup> Myelolipoma in our patient was found with hypertension, headache and upper abdominal pain. There is no proven link between hypertension, headache and myelolipoma. Occasionally there are clinical symptoms such as abdominal pain or flank pain as in our patient. Spontaneous retroperitoneal haemorrhage in association with myelolipoma has been described.<sup>9</sup> The differential diagnosis should include renal angiomyolipoma, retroperitoneal lipoma and liposarcoma.<sup>10</sup> The asymptomatic small lesions of less than 4 cm should be followed up with CT scan or MRI; though some advocate just a clinical follow-up without routine follow-up with radiological investigations. Surgery is indicated in patients who are symptomatic, or lesions of more than 4 cm in size due to rare chance of rupture,<sup>11</sup> or if malignancy is suspected. Trans catheter embolization prior to surgical resection has been used successfully to achieve haemostasis in cases of ruptured myelolipomas leading to retroperitoneal haemorrhage.<sup>12</sup> If CT shows non-homogenous characteristics or if the diagnosis is in doubt, an image guided needle biopsy could be performed to confirm the diagnosis but this approach bears the risk of rupture and bleeding.

### Conclusion

Adrenal myelolipoma is a relatively rare tumour. Cross sectional imaging is helpful in making a pre-operative diagnosis. In order to prevent serious morbidity or to exclude malignancy, criteria for surgical intervention should include size of tumour though it has no definite consensus, or increase in size, change in appearance or presence of symptom at presentation.

### References

1. Novitsky YW, Czerniach DR, Kercher KW, Perugini RA, Kelly JJ, Litwin DE. Feasibility of laparoscopic adrenalectomy for large adrenal masses. *Surg Laparosc Endosc Percutan Tech* 2003 Apr;13(2):106-10.
2. Lack EE. Tumours of the adrenal gland and extraadrenal paraganglia. Washington, DC: Armed Forces Institute of Pathology; 1970.
3. Akamatsu H, Koseki M, Nakaba H, Sunoda S, Ito A, Teramoto S, Miyata M. Giant adrenal myelolipoma: report of a case. *Surg Today* 2004;34(3):283-5.

4. Doddi S, Singhal T, leake T, Sinha P. "Management of an incidentally found large adrenal myelolipoma:a case report". Cases journal,2009 ,vol. 2, no.9, article 8414.
5. Cha JC, Shin YS, Kim MK, Kim HJ," Myelolipomas of both adrenal glands", Korean journal of Urology2011;52(8):582-85.
6. Rao P, Kenney PJ, Wagner BJ, Davidson AJ: Imaging and pathologic features of adrenal myelolipoma. Radiographics1997;17:1373-1385
7. Daneshmand S ,Quek MK, "Adrenal myelolipoma: diagnosis and management", Journal of Urology2006;3:71-74.
8. Meaglia JP, Schmidt JD: Natural history of an adrenal myelolipoma. J Urol 1992;147:1089-1090
9. Lawler LP,Pickhardt PJ. Giant adrenal myelolipoma presenting with spontaneous hemorrhage: CT, MR and pathology correlation.Ir Med J 2001;94:231.
10. Repassy RS, Csata C, Sterlik G and Ivanyi A,"Giant adrenal myelolipoma, "Pathology&Oncology research 2001;7:72-73.
11. Kuan-Chou Chen, Han-Sun Chiang,Yun-Ho Lin:Adrenal myelolipoma: A case report with literature review. J Urol R O C 2000;11:185-189
12. Hisamatsu H,Sakai H, Tsuda S,Shigematsu K, Kanetake H: Combined adrenal adenoma and myelolipoma in a patient with Cushings syndrome: case report and review of the literature. Int J Urol 2004;11:416-418.