

Case Report

IDIOPATHIC SCLEROSING ENCAPSULATING PERITONITIS: ABDOMINAL COCOON IN A 50 YEAR OLD MALE

SM Quamrul Akther¹, Md. Mamunur Rahman¹, Mozammel Hoque¹, Syed Masud Reza¹, Sharmin Islam², Md. Golam Rabbani³

Abstract

Idiopathic Sclerosing Encapsulating Peritonitis (or abdominal cocoon) is a rare cause of small bowel obstruction, especially in adult population. Diagnosis is usually incidental at laparotomy. We report one such rare case, outlining the fact that an intra-operative surprise diagnosis could have been facilitated by previous investigations.

Key Words : Idiopathic sclerosing encapsulating peritonitis, abdominal cocoon, adhesiolysis.

Introduction

Sclerosing encapsulating peritonitis is a rare cause of small bowel obstruction, and can be classified as idiopathic or secondary (most importantly and most frequently due to chronic ambulatory peritoneal dialysis)¹. It affects mainly young females from tropical and subtropical regions, but adult case reports from temperate zones can be encountered in literature. It is characterized by a thick, fibrotic, cocoon-like membrane, partially or totally encasing the small bowel. Clinically, it presents with recurrent episodes of acute or subacute small bowel obstruction, weight loss, nausea and anorexia, and at times with a palpable abdominal mass². Most cases are diagnosed incidentally at laparotomy, as in the case presented, although a preoperative diagnosis can be made feasible

by a combination of barium follow-through (concertina pattern or cauliflower sign and delayed transit of contrast medium) and computed tomography of the abdomen (small bowel loops congregated to the center of the abdomen encased by a soft-tissue density mantle)^{3,4}. However, preoperative diagnosis requires a high index of clinical suspicion. Surgery (membrane dissection and extensive adhesiolysis) is the treatment of choice, and there is usually no need for bowel loop resection, especially when a preoperative diagnosis is feasible. Resection is indicated only if the bowel is non-viable. An excellent long-term postoperative prognosis is guaranteed in most of the times⁵. We report a rare case of Idiopathic sclerosing encapsulating peritonitis (abdominal cocoon) in a 50 year old male diagnosed preoperatively in Dept. of Surgery, Shaheed Suhrawardi Medical College Hospital.

Case Report :

A 50 year-old man was admitted in the department of surgery, Shaheed Suhrawardi Hospital with the complaints of vomiting for 2 months, which was profuse in amount, projectile in nature, greenish in colour, spontaneous after taking food that contained

1. Assistant Professor, Department of Surgery, Shaheed Suhrawardi Medical College, Hospital, Dhaka.
2. Registrar, Department of Surgery, Shaheed Suhrawardi Medical College, Hospital, Dhaka.
3. Assistant Registrar, Department of Surgery, Shaheed Suhrawardi Medical College, Hospital, Dhaka.

Corresponding Author: Dr. Sharmin Islam, Registrar, Surgery, Shaheed Suhrawardi Medical College, Hospital, Dhaka. e-mail: sharmy_zm@yahoo.co.uk

Received March 13 2015

Accepted April 07 2015

undigested food particles, bitter in taste and not mixed with blood. He also complained of non progressive central abdominal distension for 1 month that was associated with occasional pain which was central, colicky in nature, moderate in intensity, having no radiation, aggravated after taking meal and usually relieved after vomiting. He gave history of alteration of bowel habit in the form of constipation that moved every 4-5 days interval. Patient had significant weight loss (5 kg in 1 month) in spite of good appetite. Patient gave no history of fever, loss of appetite, jaundice, cough, haemoptysis and per rectal bleeding. His bladder habit was normal.

On general examination, the patient was ill looking with average body build, mildly anaemic and mildly dehydrated. Vital parameters were normal (Pulse 78 beats/min, blood pressure 120/70 mm Hg). On abdominal examination, an ill defined lump was found, occupying the umbilical and part of hypogastric region. It was non-tender, doughy in consistency, slightly mobile from side to side and from above downwards with a smooth surface. Its maximum transverse and vertical diameters were approximately 12 cm and 10 cm respectively. There was visible peristalsis in the epigastric region (Figure-1). There were no abdominal scars, external hernias or organomegaly. Digital rectal examination revealed no abnormality. Percussion note was tympanic all over the abdomen and over the lump. Bowel sound was exaggerated. All other systemic examinations revealed no abnormality.

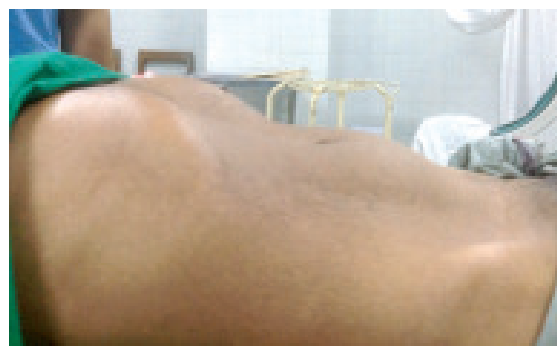

Fig.-1 : Preoperative photograph of the patient

Blood profile and urine analyses were within normal limits. Plain abdominal skiagram in erect posture showed multiple air-fluid levels located centrally without free gas under the diaphragm. USG of abdomen revealed localized distended bowel loops with exaggerated peristalsis in umbilical region more towards left side which appeared to be constricted laterally. Barium meal study of Stomach, Duodenum and Small bowel follow-through performed in another hospital before admission showed a dilated stomach, markedly dilated duodenum proximal to duodeno-jejunal junction and cauliflower like appearance of small bowel in lower abdomen and pelvis (Figure-2).

Endoscopy of upper GIT revealed congestive gastropathy with proximal bowel obstruction. Contrast enhanced abdominal computed tomography showed part of jejunum is introduced within the proximal part of jejunum resulting in dilatation of duodenum. Coronal reconstruction shows thickened mesentery with fan shaped thick walled small gut. CT scan was suggestive of Duodeno-jejunal Intussusception with Cocoon formation (Figure-3).

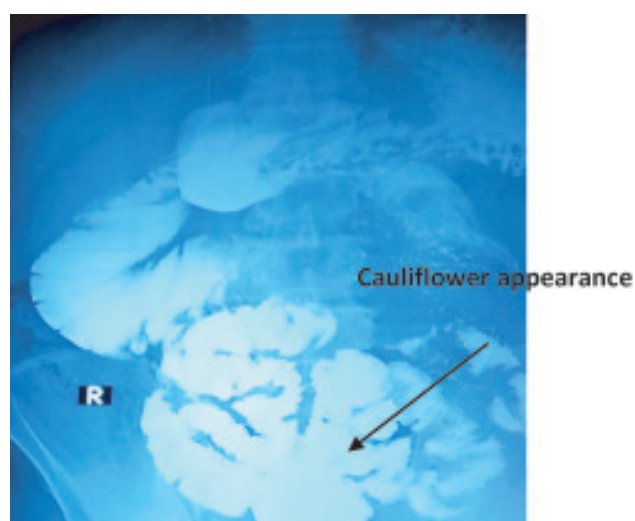
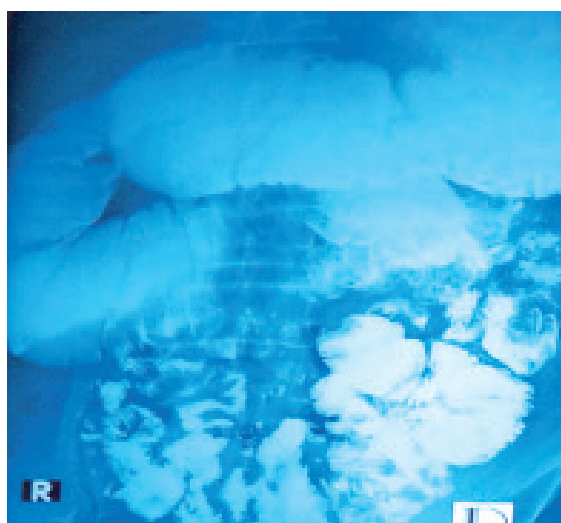


Fig.-2: Barium meal study of stomach, duodenum and small bowel follow through after 4 hours and 7 hours respectively showing marked dilatation of duodenum proximal to duodeno-jejunal junction and cauliflower appearance of small bowel in lower abdomen and pelvis.

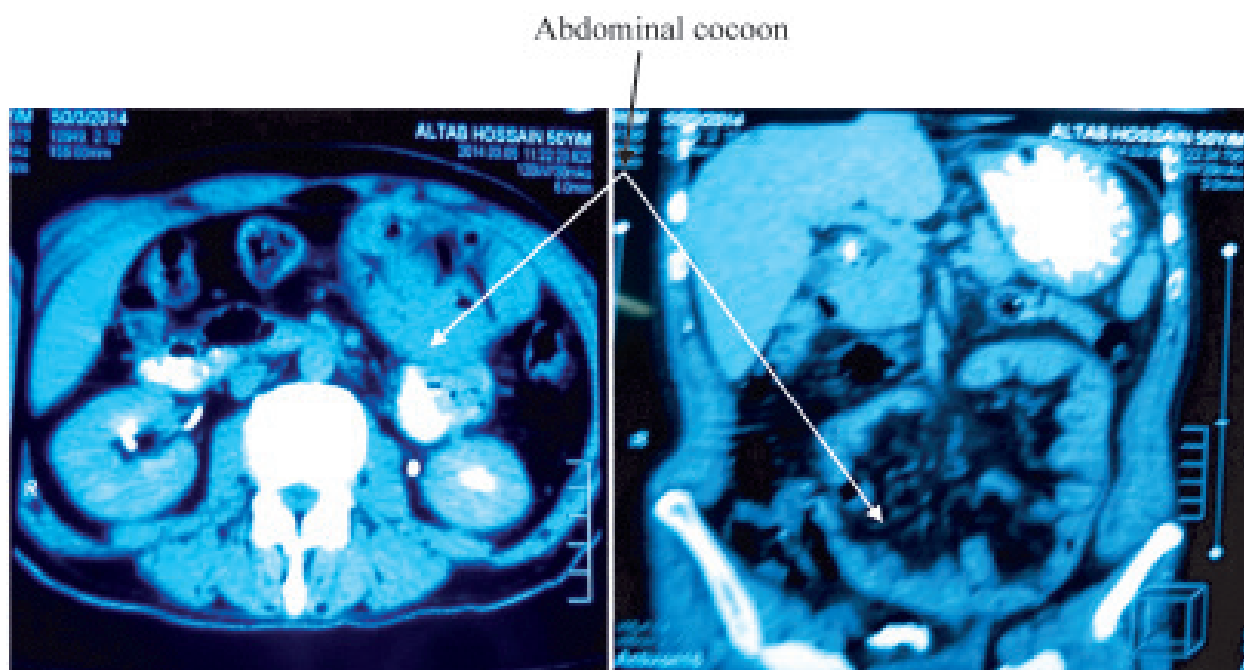


Fig.-3 : CT scan of whole abdomen showing Abdominal Cocoon

With this working diagnosis, after adequate preparation of the patient, exploratory laparotomy was done. Peritoneum was found thick, adherent with underlying structures and separated from that. There was no ascites and no tubercle was found. Whole of the small intestine including portion of stomach, ascending colon and transverse colon was covered by thick fibrous sheath (Picture 4). Descending colon, rectum and rest of the stomach was free but sigmoid colon was incorporated within the sheath. The thick sheath was excised gently by sharp and blunt dissection. Gut wall was apparently normal looking and there was no stricture. Duodenum was mobilized

and found hugely dilated. There was no intussusception anywhere in small intestine. Portion of the thick sheath was excised and was sent for histopathology. There was no lymphadenopathy. Peritoneal toileting was done with warm normal saline. Abdominal cavity was closed in layers after keeping a drain tube in pelvic cavity. Post-operative period was uneventful and patient was started oral feeding from 3rd post-operative day.

Histopathology of excised portion of the sheath revealed few inflammatory cells, sheets of dense collagenous tissue and no malignant cell was found.

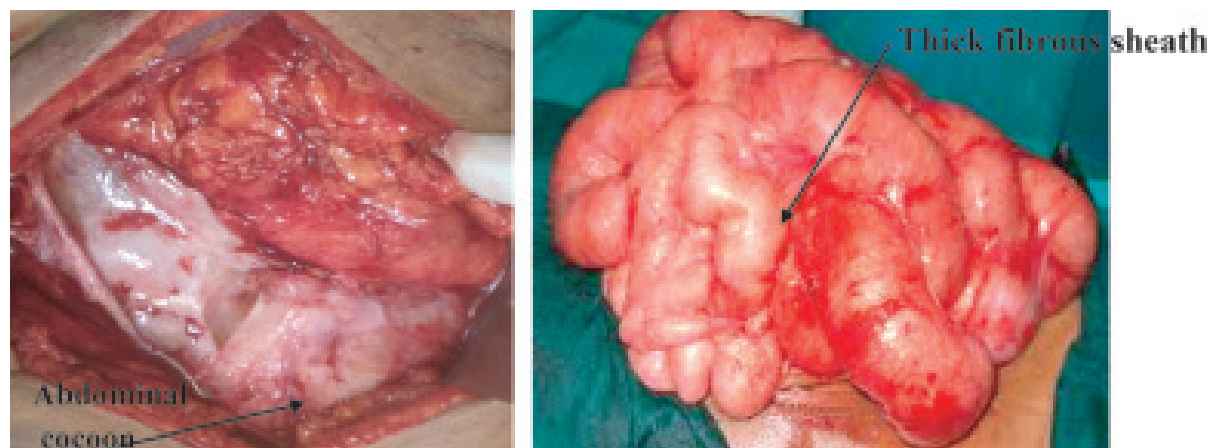


Fig.-4: Peroperative view of abdominal cocoon

Discussion:

Abdominal cocoon syndrome (or idiopathic encapsulating peritonitis) is a rare disease of the peritoneum and almost invariably presents as an acute or subacute intestinal obstruction with or without a mass, which is usually diagnosed incidentally at laparotomy⁶. It was first described by Foo et al. in 1978¹. Characteristically the bowel is found totally or partially coiled up in a concertina fashion under the encased thick fibrous white membrane and still up to date of an unknown aetiology^{7,8}. Some authors have implicated prolonged administration of practalol therapy as a possible aetiology in some cases, meconium peritonitis, sarcoidosis, orthotopic liver transplantation, indwelling abdominal catheters, or even tuberculous infection of the female genital tract⁹. These conditions may predispose patients to chronic peritoneal irritation and inflammation, which as a final effect leads to peritoneal fibrogenesis. Cell-mediated immunological tissue damage initiated by microorganisms assessed by immune-fluorescent studies has been documented in some cases as possible cause. Preoperative tissue culture of peritoneal membrane may also contribute in future in the further evaluation of the aetiology of abdominal cocoon syndrome⁶.

In clinical presentation, abdominal cocoon is presented by recurrent attacks of acute or subacute small bowel obstruction, nausea, weight loss and anorexia and sometimes with palpable abdominal mass. Most patients are diagnosed incidentally at laparotomy and preoperative diagnosis requires a high index of clinical suspicion². WBC count, C-reactive protein level, hypoalbuminemia and anemia are common findings in SPE cases but no significant sign was observed in this case. Imaging has an important role in the diagnosis of abdominal cocoon. Barium X-ray and contrast CT are useful for the diagnosis of abdominal cocoon preoperatively¹⁰. Dilated bowel loops with multiple air-fluid levels may be shown in conventional abdominal X-ray but they are nonspecific^{10,11}. The classic findings of abdominal CT consist of small bowel loops congregation in the center of abdomen with a non-enhancement fibrous membrane surrounding the bowel loops that is best visualized on computed axial tomography scan^{10,12,13}. Surgical dissection and excision of the membrane and adhesiolysis remain the cornerstone in the treatment of abdominal cocoon^{14,10}. In this case a

dilated small bowel with an edematous mesentery and a dense whitish membrane covering the small bowel, portion of the stomach, ascending colon and transverse colon observed per-operatively was suggestive of idiopathic sclerosing peritonitis.

Despite anecdotal reports of a preoperative diagnosis especially by medical imaging, in the majority of cases of idiopathic encapsulating peritonitis, it is a fortuitous finding. A high index of clinical suspicion^{15,16}, with good history detailing some of the previously mentioned associated causes combined with relevant imaging findings^{17,18}, is recommended in enhancing pre-operative diagnosis of abdominal cocoon syndrome.

Conclusions:

Clinicians must rigorously pursue a preoperative diagnosis, as it may prevent a "surprise" upon laparotomy and unnecessary procedures for the patient, such as bowel resection. In general, prognosis of abdominal cocoon after surgery is satisfactory and excision of the thick membrane and release of the small intestine leads to complete recovery.

References

1. Foo KT, Ng KC, Rauff A, Foong WC, Sinniah R: Unusual small intestinal obstruction in adolescent girls: the abdominal cocoon. *Br J Surg* 1978, 65:427-30.
2. Kawaguchi Y, Kawanishi H, Mujais S, Topley N, Oreopoulos DG: Encapsulating peritoneal sclerosis: definition, etiology, diagnosis, and treatment. International Society for Peritoneal Dialysis Ad Hoc Committee on Ultrafiltration Management in Peritoneal Dialysis. *Perit Dial Int* 2000, 20 Suppl 4:43-55.
3. Deeb LS, Mourad FH, El-Zein YR, Uthman SM: Abdominal cocoon in a man: preoperative diagnosis and literature review. *J Clin Gastroenterol* 1998, 26:148-50.
4. Hur J, Kim KW, Park MS, Yu JS: Abdominal cocoon: preoperative diagnostic clues from radiologic imaging with pathologic correlation. *Am J Roentgenol* 2004, 182:639-41.
5. Celicout B, Levard H, Hay J, Msika S, Fingerhut A, Pelissier E: Sclerosing encapsulating peritonitis: early and late results of surgical management in 32 cases. French Associations for Surgical Research. *Dig Surg* 1998, 15:697-702.

6. Sieck JO, Cowgill R, Larkworthy W. Peritoneal encapsulation and abdominal cocoon. Case reports and a review of the literature. *Gastroenterol* 1983; 84(6): 1597–1601
7. Rao PLNG, Mitra SK, Pathak IC. Abdominal cocoon—a cause of intestinal obstruction in a 4 years old girl. *Indian Pediatrics* 1979; 16(11): 1047–8
8. Rajagopal AS, Rajagopal R. Conundrum of the cocoon: report of a case and review of the literature. *Dis Colon Rectum* 2003;46(8) : 1141–3
9. Rastogi R. Abdominal cocoon secondary to tuberculosis. *Saudi J Gastroenterol* 2008;14(3): 139–41
10. Wei B, Wei HB, Guo WP, Zheng ZH, Huang Y, Hu BG, Huang JL. Diagnosis and treatment of abdominal cocoon: a report of 24 cases. *Am J Surg*. 2009 Sep;198(3):348-53.
11. Devay AO, Gomceli I, Korukluoglu B, Kusdemir A: An unusual and difficult diagnosis of intestinal obstruction: The abdominal cocoon. Case report and review of the literature. *World J Emerg Surg* 2006, 1:8.
12. Xu p, Chen LH, Li YM: Idiopathic sclerotizing encapsulating peritonitis (or abdominal cocoon): A report of 5 Cases. *World J Gastroenterol* 2007; 13(26): 3649-51.
13. Wig JD, Gupta SK: Computed tomography in abdominal cocoon. *J Clin Gastroenterol* 1998, 26:156-7.
14. Tombak MC, Apaydin FD, Colak T, Duce MN, Balci Y, Yazici M, Kara E: An unusual cause of intestinal obstruction: Abdominal Cocoon. *Am J Roentgenol* 2010; 194:176-8.
15. Macklin J, Hall C, Feldman MA. Unusual cause of small bowel obstruction in adolescent girls: the abdominal cocoon. *J R Coll Surg Edin* 1991; 36(1): 50–2
16. Matone J, Herbella F, Del Grande JC. Abdominal cocoon syndrome. *Clinic Gastroenterol Hepatol* 2006; 4(5):31
17. Yoon YW, Chung JP, Park HJ et al. A case of abdominal cocoon. *J K Med Sci* 1995 ; 10(3): 220–5
18. Kumar M, Deb M, Parshad R. Abdominal cocoon: report of a case. *Surgery Today* 2000; 30 (10): 950–3