

Comparative Study of Saline Sono Salpingography (SSG) and Laparoscopy with Chromopertubation in Evaluation of Tubal Patency

Ghani A¹, Ila IJ², Tasmin KS³, Zakaria R⁴, Ferdows JA⁵, Sultana N⁶, Sultana J⁷

Abstract

Conflict of Interest: None

Received: 18-04-2019

Accepted: 07-05-2019

www.banglajol.info/index.php/JSSMC

Background In the field of infertility, tubal factor has a great role. So the assessment of tubal patency belongs to the initial diagnostic tests in the work-up of an infertile woman. During the past few years, sonosalpingography has been suggested as the firstline method to study tubal patency. This comparative study of transvaginal saline SSG to the gold standard method of diagnostic laparoscopy with chromopertubation was performed for the assessment of tubal patency in infertile women.

Methods At first thirty-four patients suffering from primary or secondary infertility were evaluated for tubal patency with sonosalpingography using a pediatric Foley urinary catheter using saline solution as a contrast medium. The uterine tubes were evaluated. One patient conceived and two patients denied before the scheduled laparoscopy. Ultimately they were excluded from the study. In the study, finally 31 patients were enrolled and the results of SSG were compared to the findings of laparoscopy and chromotubation performed independently.

Results The findings of both methods agreed in 26 out of 31 tubes (concordance, 93.5%). The sensitivity of sonosalpingography in diagnosing tubal patency was 96.2% and the specificity 80%. The positive predictive value for tubal patency by sonosalpingography was 96.29% and the negative predictive value 80%. Adverse events of sonosalpingography included mild abdominal pain in some patient. No infectious complications were recorded.

Conclusions The results confirm that sonosalpingography using saline as a contrast medium is a reliable, simple and well-tolerated method to assess tubal patency in an outpatient setting. In addition, the procedure can be performed without prophylactic antibiotics.

Key Words:

Infertility; laparoscopy; sonosalpingography; tubal patency

[J Shaheed Suhrawardy Med Coll 2019; 11(1): 52-58]

DOI: <https://doi.org/10.3329/jssmc.v11i1.43181>

1. Dr. Afroza Ghani, Associate Professor, Department of Obstetrics & Gynaecology, Shaheed Suhrawardy Medical College, Dhaka
2. Dr. Israt Jahan Ila, Associate Professor, Department of Obstetrics & Gynaecology, Shaheed Suhrawardy Medical College, Dhaka
3. Dr. Khandaker Shehneela Tasmin, Junior Consultant, Obstetrics & Gynaecology, Shaheed Suhrawardy Medical College, Dhaka
4. Dr. Rooh-e Zakaria, Assistant Professor, Department of Obstetrics & Gynaecology, Shaheed Suhrawardy Medical College, Dhaka
5. Dr. Jannat Ara Ferdows, Associate Professor, Department of Obstetrics & Gynaecology, Shaheed Suhrawardy Medical College, Dhaka
6. Dr. Nasrin Sultana, Junior Consultant, Obstetrics & Gynaecology, Mohammadpur Fertility Services & Training Center, Dhaka
7. Dr. Jesmin Sultana, Junior Consultant, Obstetrics & Gynaecology, Upazila Health Complex, Rupsha, Khulna

Correspondence to: Dr. Afroza Ghani, Associate Professor, Department of Obstetrics & Gynaecology, Shaheed Suhrawardy Medical College, Dhaka

Introduction

Infertility is defined as the failure to conceive after one year of regular unprotected intercourse. It affects 10% to 15% of couples¹. Infertility can be primary or secondary. Both male and female factors may be responsible for infertility. Main causes of infertility in women include anovulation, a tubal or peritoneal factor, and uterine, cervical, and idiopathic infertility^{2,3}. The assessment of tubal patency belongs to the initial diagnostic tests in the work-up of an infertile woman⁴. The role of a tubal factor in infertility is increasing, and currently, it determines 30% to 35% of all infertility cases⁵. Precise evaluation of the patency of fallopian tubes is an important step in infertility assessment. There are multiple etiologic factors responsible for the involvement of the fallopian tube in infertility, which include tubal damage from pelvic inflammatory disease

(PID), endometriosis, use of intrauterine devices, a history of a perforated appendicitis, ectopic pregnancy, and septic abortion. Tubal adhesions and tubal obstruction can result in infertility⁶. Gonorrhoea, chlamydial infection or salpingitis following septic abortion or puerperal infections are amongst the common causes of blockage of fallopian tubes⁷. Ever since Rubin described the tubal insufflation test in 1920 by using carbon dioxide, numerous methods have been developed for evaluation of factors. Hysterosalpingography (HSG) and laparoscopy with chromopertubation are the most commonly used methods to examine tubal patency^{6,8}. Bilateral proximal obstruction of the tube at its junction with the uterus can occur because of a tubal spasm during HSG, which is induced by the injection of dye during the procedure. Contractions of the uterus can also lead to transient spasms in the interstitial part of the fallopian tube, which can be mistaken for tubal obstruction during HSG, and this entity needs to be carefully distinguished from pathologic conditions⁸. Furthermore, the unavoidable exposure of germ cells to radiation and low patient compliance due to pain, are disadvantages associated with HSG⁴. In comparison with laparoscopy, HSG has shown low sensitivity in the determination of patent fallopian tubes, and the diagnosis of fallopian tube obstruction based on HSG carries as high as 60% probability of actually patent fallopian tubes. This is the reason why bilateral proximal obstruction of uterine tubes diagnosed by HSG should be subsequently confirmed by laparoscopy⁸. On the other hand, laparoscopy and dye insufflation test is generally regarded as being the gold standard for direct visualization of tubal patency and fimbrial architecture, but is an invasive diagnostic method that requires general anesthesia and carries the risk of severe adverse effects, including injury to pelvic blood vessels, intestinal loops, and the urinary bladder^{8,9}. Recently the newer technique of sonohysterosalpingography popularly known as Sono Salpingography (SSG) is evolved⁶.

The clinical evaluation of infertile women should be based on an evaluation of the risk benefit and cost benefit ratio of diagnostic tools. A low cost and low risk methodological approach should be the first choice of investigations, later followed by more complex or invasive procedures. Recent advances in gynaecological ultrasound can replace routine invasive investigative procedures. This will make the basic infertility investigation less time consuming, less expensive and more acceptable¹⁰.

Sonohystero-graphy (SHG) is a simple, safe, and well-tolerated examination technique used for investigation of the uterine cavity and fallopian tubes with very few adverse effects and a low occurrence of complications. It

consists of an instillation of sterile saline through a Foley catheter inserted through the cervix with simultaneous transvaginal sonography and the risks of adverse effects during the procedure itself are minimal. It may also be provided as an outpatient procedure⁸.

A few comparative studies using laparoscopy and chromotubation as the 'gold standard' have demonstrated sonosalpingography to be a reliable and simple preliminary test to investigate uterine and tubal patency and sonosalpingographic examinations also exhibit good reproducibility. In this study, our goal was to determine the diagnostic value of SHG for the diagnosis of tubal obstruction by comparison of SHG with laparoscopic results.

Material and methods

At first 34 patients registered in the infertility clinic of Gynae OPD of Department of Obstetrics and Gynecology, Shaheed Suhrawardy Medical College and Hospital between October 2018 to March 2019 suffering from either primary or secondary sub-fertility, were enrolled in the study group and all of them were undergone SSG. Subsequently one patient conceived before the scheduled laparoscopy and two patients disagreed for laparoscopic evaluation, were excluded from the study. So finally total 31 patients were included in this study. The age of the women ranged from 25 to 42 years (mean \pm s.d.; 31.2 \pm 4.5 years).

It was a comparative study of transvaginal saline SSG to the gold standard method of diagnostic laparoscopy with chromopertubation for the assessment of tubal patency in infertile women.

The procedures were explained to all enrolled infertile women. Written informed consent was taken from the patient after a thorough explanation of the procedure. Patients with acute PID, active genital TB, pelvic abscess, genital tract anomaly and also azoospermia in male partner were excluded from the study. No premedications (such as antibiotics or sedatives) were given prior to Sono Salpingography.

After getting Ethical and Research Committee clearance, a prospective study was undergone involving a series of 31 women including both primary and secondary infertility registered in the infertility clinic, Obstetrics and Gynaecology department, Shaheed Suhrawardy Medical College and Hospital for six months (October 2018 to March 2019). These patients after initial evaluation were subjected to Sono Salpingography. This was followed by laparoscopy with chromopertubation within next two to four weeks. The results of the two tests were compared to determine the accuracy of SSG.

In all these patients' detailed history with respect to nature and duration of infertility and history suggestive of etiological factors like pelvic inflammatory diseases, tuberculosis and previous surgeries were taken. Menstrual history, past obstetric history in cases of secondary infertility and significant personal and past history were recorded. History regarding male factor infertility was also taken.

The patients were subjected to a general examination, abdominal and pelvic examination to detect any obvious pathology. Routine investigations, husband's semen analysis, and other relevant investigations were done in all these cases.

All women were in their proliferative phase of the menstrual cycle. Sonosalpingography was performed prior to laparoscopy between 7th and 12th day of their menstrual cycles. The patient was instructed to abstain from sexual intercourse from the time menstrual bleeding ends until the day of the study to avoid a potential pregnancy.

Initially, transvaginal sonographic examination of the pelvis was performed in dorsal lithotomy position using an Toshiba Nemio XG, high resolution vaginal probe (PVM-620ST 7.0 MHZ). This was to assess normal free fluid in cul de sac as a baseline data. Minimal free fluid detected in cul de sac before performing the procedure in some cases would be recorded and imaged with an ultrasonographic picture. Antiseptic cleaning of cervix and vagina were done with povidone solution. A speculum was gently inserted in the vagina. The anterior lip of the cervix was grasped with a vulsellum. The number-8 pediatric Foley catheter with semirigid catheter guide was inserted about 5 cm into the endocervix and passed above the level of the internal os. The balloon was then inflated with 2 ml of isotonic saline solution and pulled down gently so the balloon fitted against the internal os. The semirigid catheter guide in Foley and the speculum were removed together. The transvaginal probe was reinserted followed by intermittent injection of total 30-40 ml of sterile isotonic saline solution through the pediatric Foley catheter into the uterine cavity. Thorough evaluation of the cavity and the adenexa was done to see free spillage of saline (waterfall sign). Then, observed the collection of fluid in the cul-de-sac for 2 minutes. The collection of fluid in the cul-de-sac (Fig. 2) or an increased volume of the preexisting free fluid in cul-de-sac was considered as the evidence of at least unilateral tubal patency (positive test). Bilateral tubal occlusion was diagnosed by the absence of fluid collection in the cul-de-sac or static level of fluid in the cul de sac after the procedure (negative test). After this procedure, the patient would be observed at rest for few minutes.

After completing both the procedures, results of SSG were correlated to the results of laparoscopy.

Results

At first 34 patients registered in the infertility clinic of Gynae OPD suffering from either primary or secondary sub fertility, were enrolled in the study group and all of them were undergone SSG. Subsequently one patient conceived before the scheduled laparoscopy and two patient disagreed for lapaorscopic evaluation, were excluded from the study. So finally total 31 patients were included in this study.

All the subjects were in the age range between 25-42 years. In table 1; majority of patient 13 (41.9%) were in 30-34 years age group and the mean age was 31.2 years. Out of 30 patient, education level of 14 patients (45.1%) were upto primary level. 20 (64.5%) patients were house wife while only 8 (25.8%) patients were service holder. 20 (64.5%) patient were nulliparus and 11 (36.67%) patient were multiparus.

Table 1

Socio-Demographic features of the study population

Variable	Frequency	Percent
Age group		
25-29	11	35.5 %
30-34	13	41.9 %
35-39	5	16.1 %
40-42	2	6.5 %
Level of education		
Primary	14	45.1 %
SSC	7	22.6 %
HSC	4	12.8 %
Graduation	6	19.5 %
Occupation		
Service Holder	8	25.8 %
House wife	20	64.5 %
Others	3	9.7 %
Parity		
Nullipara	20	64.5 %
Multipara	11	35.5 %

Fig.-1 showed that out of 30 patients 19 (63.33%) were of primary infertility while 11(36.67 %) were of secondary sub-fertility.

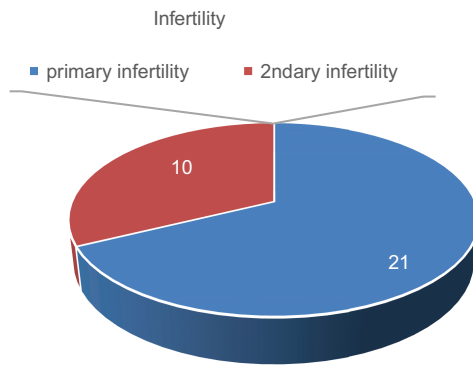


Fig.-1: Parity of Infertility Patients

Table-II

Tubal findings in primary/ secondary infertility on SSG

Salinesonosalingography SSG(n= 31)		
Patency of tube	Frequency	Percentage
Patent tube	26	83.9%
Non patent tube	5	16.1%

Table -II shows, there were 26 (83.9%) cases where at least one tube was found patent in SSG and non patency were found in 5 (16.1) cases.

Table-III

Tubal findings in primary/ secondary infertility on Laparoscopy and chromopertubation

Laparoscopy and chromopertubation (n= 31)		
Patency of tube	Frequency	Percentage
Bilateral Patent tube	23	74.2%
Unilateral patent tube	3	9.7%
Non patent tube	5	16.1%

Table -III shows after laparoscopy 26 (86.67%) patients had bilateral patent tubes, 3(10%) had non patent tube and 1(3.3%) had unilateral tubal block.

Table-IV

Accuracy of Trans vaginal Saline Sono Salpingography (SSG) in diagnosing tubal patency

Laparoscopy and chromopertubation (n= 31)		
Trans vaginal Saline Sono Salpingography (SSG)	Unilateral or bilateral tubal patency	Bilateral tubal occlusion
Patent tube 26	25	01
Non patent tube 05	01	04
Total 31		

Table-IV shows that data obtained after analysis of SSG and laparoscopic chromopertubation, among the 26 patients having patent tubes found in SSG, only one patient was found having tubal block, 23 patients having bilateral patent tubes and 2 patients having unilateral patent tubes(total 25) in laparoscopic chromopertubation. Among the 5 patients having non patent tubes found in SSG, 4 patients were found having non patent tubes and only 1 patient was found having unilateral patent tube in laparoscopic chromopertubation.

Table-V

Evaluation of the value of transvaginal saline sono salpingography in assessment of tubal patency.

Results	Percentage %
Sensitivity	96.2%
Specificity	80%
False positive rate	20%
False negative rate	3.8%
Likely hood ratio	4.8%
Positive predictive value	96.2%
Negative predictive value	80%
Accuracy (Overall concordance)	93.5%

Table V shows that comparison of transvaginal saline sono salpingography (SSG) with the gold standard laparoscopy and chromopertubation, in diagnosing tubal patency, sensitivity of the study was 96.2% and specificity was 80%. False positive rate(100 - specificity) was 20% and false negative rate was 3.8%. the likely hood ratio(sensitivity/ false positive rate) for patent tube was 4.8%. The tubal patency found in 26 patients by SSG was confirmed by laparoscopy in 25 patients (positive predictive value, 96.29%). The tubal occlusion found in 05 patients by SSG was confirmed by laparoscopy in 04 patients (negative predictive value, 80%). So the Accuracy i.e Overall concordance (total number of patency and non patency in both methods/total number of patients) of the study was 93.5%.

Discussion

Tubal disease is one of the most frequent cause of female infertility. In the infertile patient, transvaginal sonography is widely used as a means to evaluate the morphology of inner genital tract and to monitor follicular development in stimulated and natural cycles. Transvaginal sonography can give important data about the morphologically altered tubes, very infrequently the normal salpinx can be visualized except for the interstitial part¹⁰. One of the major

causes of infertility is blockage of the fallopian tubes. In the investigation and treatment of infertility, it is important to establish that the tubes are patent⁴. In the past two decades there was lot of advancement in the medical technology and management of infertility. With the advent of ultrasound, trends have been towards the application of sonographic hydrotubation for the assessment of tubal patency in a greater manner¹¹. Transvaginal saline SSG compared with the conventional methods (i.e. HSG, and laparoscopy with chromopertubation), is easier and safer to perform. It can be used to avoid some disadvantages of HSG, such as exposure to ionizing radiation or allergy to iodinated contrast material in sensitized patient¹¹. Compared to diagnostic laparoscopy which is the gold standard test for tubal study, although SSG is less accurate in evaluation of tubal patency and direct visualization of pelvic pathology is not possible but anesthetic and surgical risk from the former procedure can be avoided¹¹. Saline infusion sonohysterography or SSG, a low-tech, low-cost is the term for ultrasound imaging of the uterine cavity, using sterile saline solution as a negative contrast medium. Evaluation of tubal patency is necessary because any treatment, such as induction of ovulation and artificial insemination, given without making sure that the tubes are patent may be a futile effort. There has been a rising demand for accurate and non-invasive diagnostic procedures, and this has fostered significant innovations in the technique and equipment used for evaluating infertility¹².

This study was conducted to bring into focus the value of sonosalpingogram in assessing tubal patency in order to overcome the radiation hazard associated with hysterosalpingogram (HSG), reduce cost of examination and encourage it as first-line out-patient procedure for management of female infertility⁹.

There are few studies done by researchers to assess the diagnostic accuracy of ultrasound in assessing the tubal patency. Tüfekçi EC et al evaluated tubal patency by transvaginal sonosalpingography and on the basis of results concluded that transvaginal sonosalpingography, with its accuracy and safety, is a promising screening and diagnostic technique in the evaluation of tubal patency on ambulatory basis⁹.

Seal Subrata Lall et al did a comparative study of sonosalpingography, hysterosalpingography and laparoscopy for determination of tubal patency to find out whether sonosalpingography, which is a less invasive method, can be used for assessment of tubal factor in cases of primary and secondary infertility initially instead of the invasive methods like hysterosalpingography and diagnostic laparoscopy with chromopertubation which are

associated with significant morbidity and even some mortality. The results were sonosalpingography had 97.3% sensitivity and 92% specificity in comparison to laparoscopic chromopertubation whereas hysterosalpingography had 94.6% sensitivity and 84% specificity¹³.

Suttipichate J et al performed a prospective study to evaluate the characteristics of transvaginal saline sonosalpingography (SSG) for the assessment of tubal patency in comparison to the findings from the standard diagnostic laparoscopy with chromopertubation. The results confirmed that transvaginal saline SSG is a simple, well-tolerated and reliable screening method for the assessment of tubal patency in an outpatient setting with minimal adverse effect^{9,13}. Moreover transvaginal saline SSG may also be used to assess the tubal status after microsurgery for reanastomosis in an out patient setting¹¹. Another study conducted by Seal Subrata Lall et al, showed that SSG had high sensitivity and specific and was less invasive¹³.

Suttipichata J et al, assessed tubal patency transcervically by injecting isotonic saline solution. Patency of at least one fallopian tube was detected by demonstrating the collection of free fluid in cul de sac¹¹. In our study we also went to the same conclusion. The accuracy in establishing which tube was patent in this study was not in our scope because it would be time consuming and need extra skill for interpretation. Case AM and Pierson RA studied, clinical use of Sonohysterography in the evaluation of infertility and concluded that Sonohysterography can offer detailed assessment of the female pelvis, and has the potential to replace HSG as a routine, first-line infertility investigation. Zvanca M, Andrei C examined patients of infertility by sono-hysterosalpingography & checked their results by laparoscopy also concluded the same⁹. Panchal S and Nagori C in their study for assessment of tubal status, said that HSG is painful and inconvenient for patient. Laparoscopy is considered to be the gold standard for tubal evaluation, but is an operative procedure and needs anesthesia. SSG can demonstrate a patent tube but if blocked, the site of block cannot be demonstrated⁹. One study done by Suttipichate J et al, Transvaginal saline SSG could detect almost all cases of the tubal patency with high percentage of accuracy, 95.24%. It yielded sensitivity of 96.97% and specificity of 88.89%. When it predicted good tubal patency, only one case of tubal occlusion was diagnosed by laparoscopy with chromopertubation (false positive rate = 11.11, PPV = 96.97%, likelihood ratio if test positive = 8.73). However, when the test showed nine cases of tubal occlusion, one case had tubal patency by laparoscopy with

chromopertubation (false negative rate = 3.03, NPV = 88.89%, likelihood ratio if test negative = 0.03). in our study , in diagnosing tubal patency, sensitivity of the study was 96.2% and specificity was 80%. False positive rate was 20% and false negative rate was 3.8%. the likely hood ratio for patent tube was 4.8%. The tubal patency found in 26 patients by SSG was confirmed by laparoscopy in 25 patients (positive predictive value, 96.29%). The tubal occlusion found in 05 patients by SSG was confirmed by laparoscopy in 04 patients (negative predictive value, 80%). So the Accuracy (Overall concordance) of the study was 93.5%. There was broad agreement between the tubal findings from transvaginal saline SSG and laparoscopy with chromopertubation¹¹. Our study revealed one false positive case. She had free fluid detected in cul de sac before performing the test and seemed to have increased fluid level after the test. Since the indicator of an unobstructed tubal passage used in this study was collection of free fluid in the cul de sac. This was probably due to interpretation error of ultrasonographic picture. False negative was detected in one case. This might be explained by the tubal spasm caused by injection of the media into the uterine cavity. Hence if suspected of tubal spasm, it was better to wait for a while until the patient feels relaxed and then the test was reattempted. With this step we could easily demonstrate the collection of fluid in some cases. In Suttipichate J et al study the causes of false positive and false negative results correlated with our study¹¹. In two patients they got false positive results (in left tube) i.e., patent tubes on sonosalpingography but blockage on laparoscopy and/or HSG. In both the cases there was hydrosalpinx which may itself be the reason for the false positive result since the turbulence of flow of saline through the dilated tubes may simulate spillage on USG screen. In two patients false negative results were elicited i.e., tubes were blocked on SSG but patent on HSG and laparoscopy. This may be due to tubocornual spasm, mucous plugs blocking the tubes, and technical or human error¹³.

We found certain advantages in techniques of SSG:

- It is outpatient procedure and can be performed while doing first routine ultrasound of infertile women, hence cost effective also.
- It helps in diagnosis of various uterine and tubal pathologies.
- There are no radiation hazards.
- No allergic reaction.
- If done under aseptic precautions there is no infectious morbidity.
- It can be done in Primary Health Centers also.

15 From this information, it appears that transvaginal saline SSG is a good screening test of tubal patency. Nevertheless when it shows tubal occlusion, the test should be confirmed by other tests due to possible false negative finding. 16 Regarding to the adverse effects, other studies did not report any serious side effects including infectious complication.(3-13) In our study, we found only 2 out of 31 patients experienced mild pelvic pain. They were relieved with oral analgesics and rest for 30 minutes. No other complications were encountered in this study. Hence the study clearly showed that SSG can be used as baseline investigation in all infertile women.

Limitations of study

1. The study period and number of patients were not adequate for reaching appropriate conclusion, we need to do further studies on large number of patients for more duration, so as to give conclusive results.
2. There are also some limitations such as tubal spasm, mucous plugs blocking the tubes, which may lead to the diagnosis of false tubal occlusion.
3. In hydrosalpinx, tubal flow may give a false impression of tubal patency resulting in false positive case.
4. If free fluid are detected in cul de sac before performing the test, sometimes it seems to have increased fluid level after the test, resulting in false positive case.
5. The findings are subjective.

Conclusion

Transvaginal Saline Sono Salpingography (SSG) is a reliable, simple, relatively inexpensive, convenient and effective method in evaluation of fallopian tube patency. It can be used as an alternative method to assess tubal patency in order to avoid many potential disadvantages of the conventional methods. With expected improvement in this techniques, it is believed that SSG will be a first line screening test for tubal patency on OPD basis. Easy availability and accessibility of ultrasound in all primary health care centers definitely can prove superior to conventional methods of diagnosis of tubal patency. However tubal block suspected on Sono Salpingography needs confirmation by diagnostic Laparoscopy.

References

1. Berek JS. Berek and Novak's Gynecology. 14th ed. Philadelphia, PA: Lippincott Williams & Wilkins; 2007.
2. Speroff L. Clinical Gynecology and Infertility. 7th ed. Philadelphia, PA: Lippincott Williams & Wilkins; 2005.
3. Ranaweera AKP, Batcha M, Kalansooriya H, Ranaweera AKP. Research Article Value of sonographic hydrotubation using agitated saline as a screening test for tubal patency. [cited 2015 Jan 4]; Available from: <http://saspublisher.com/wp-content/uploads/2013/04/SJAMS12122-130.pdf>

- International Journal of Scientific and Research Publications, Volume 5, Issue 7, July 2015 5 ISSN 2250-3153
4. Pirjo I, Pertti P, Leena A. Vaginal sonosalpingography in the evaluation of tubal patency. *Acta Obstet Gynecol Scand* 1998; 7: 978–982.
 5. Ranaweera AKP, Batcha M, Kalansooriya H, Ranaweera AKP. Research Article Value of sonographic hydrotubation using agitated saline as a screening test for tubal patency. [cited 2015 Jan 4]; Available from: <http://saspublisher.com/wp-content/uploads/2013/04/SJAMS12122-130.pdf> International Journal of Scientific and Research Publications, Volume 5, Issue 7, July 2015 5 ISSN 2250-3153.
 6. Kavita S, Supriya R, Anand B. Comparison of sonosalpingography and laparoscopy in evaluation of tubal patency in infertility patients. *International Journal of Scientific and Research Publications*, Volume 5, Issue 7, July 2015. ISSN 2250-3153.
 7. Padubidri VG, Daftary SN. Howkins and Bourne. Shaw's textbook of Gynaecology 15th edition. India: Elsevier; 2011. 210p.
 8. Masomeh H et al. Diagnostic Value of Sonohysterography in the Determination of Fallopian Tube Patency as an Initial Step of Routine Infertility Assessment. *J Ultrasound Med* 2009; 28:1671–1677.
 9. Madhok R et al. Role of sonosalpingogram in correlation to hysterosalpingogram in assessment of infertility. *International Journal of Reproduction, Contraception, Obstetrics and Gynecology*. 2016 Jun;5(6):1936-1943. www.ijrcog.org.
 10. Daniel S et al. A study of sonosalpingogram compared to laparoscopic chromopertubation in the evaluation of tubal patency *International Journal of Reproduction, Contraception, Obstetrics and Gynecology*. 2016 Dec;5(12):4453-4460 www.ijrcog.org.
 11. Junjira S et al. Transvaginal Saline Sonosalpingography for The Assessment of Tubal Patency. *Thai Journal of Obstetrics and Gynaecology* September 2002, Vol. 14, pp. 223-229.
 12. Lakshmi CS et al. Evaluation of tubal patency by sonosalpingography is as good as hysterosalpingography in infertile women. *International Journal of Reproduction, Contraception, Obstetrics and Gynecology*. 2017 Nov;6(11):5129-5134 www.ijrcog.org.
 13. Seal SL et al. Comparative evaluation of sonosalpingography, hysterosalpingography, and laparoscopy for determination of tubal patency. *The Journal of Obstetrics and Gynecology of India*. Vol. 57, No. 2 : March/April 2007, Pg 158-161.