

## An Unusual Diagnosis at Neck: Pilomatricoma in a Young Female: A Case Report

Akther SMQ<sup>1</sup>, Shahriar S<sup>2</sup>, Lima IJ<sup>3</sup>, Islam MS<sup>4</sup>, Sarker RD<sup>5</sup>, Gupta AS<sup>6</sup>, Medha NN<sup>7</sup>, Ishita ZS<sup>8</sup>

**Conflict of Interest:** None

**Received:** 10.01.2021

**Accepted:** 13.04.2021

www.banglajol.info/index.php/JSSMC

### Abstract

*To be true, the name of this specific pathological lesion is not widely encountered in our day-to-day surgical practice, but still, pilomatricoma or pilomatrixoma is notifiable skin neoplasm for which diagnosis can be made histopathological and only after an adequate excision. This case report is of a 23-year-old young female medical student who presented with swelling in neck, that histopathologically diagnosed as pilomatricoma. The purpose of reporting this specific case is that this pathology is rare in occurrence, but more rarely diagnosed because of lack of confirmatory pathological analysis and it is immensely essential to be kept in the differentials of all superficial skin tumors in surgical practice.*

[J Shaheed Suhrawardy Med Coll 2021; 13(1): 86-88]

DOI: <https://doi.org/10.3329/jssmc.v13i1.60938>

### Key Words:

Pilomatricoma, skin neoplasm, histopathology.

### Introduction

This remarkably noticeable lesion may develop on head, neck and upper extremities. This lesion may present with fleshy coloured, erythematous or bluish skin texture and may be variably large in size. Palpation reveals it to be a solitary swelling with firm or firm to hard consistency.<sup>1</sup> Other names to be projected for Pilomatricoma are *pilomatrixoma*, or *calcifying epithelioma of Malherbe* and they are mostly benign skin neoplasia originating from hair follicle matrix cells.<sup>2</sup> The progression of this pathology is usually slow and usually single in number, however multiple lesion were also reported in the same individual, in the skin or just beneath the skin.<sup>3,4</sup> Being truly rare of its kind, pilomatricomas constitutes 0.12% of all skin neoplasms.<sup>5</sup>

### Case Presentataion

A 23-year-old young female presented to General Surgery OPD [SU-III] of Shaheed Suhrawardy Medical College Hospital, patronized and governed by the author himself, with complaints of swelling over the nape of neck on right

for 1 and half year. The onset was gradual and initially the size was very small but slowly over last 6 months it had grown to the size of an almond. It was completely painless at the beginning with no change in skin colour. But just 2 months prior to the excision, there was an occasional dull pain in the swelling, specially when it was touched by patient's hand or garments. There was no associated fever or malaise. The patient did not mention any history of trauma prior to onset. There was no remarkable family history and past history of the disease.

On examination there was swelling in the neck of 2.0 × 1.5 cm size. On palpation, it was smooth and moderately firm to hard in consistency and slightly tender on touch. It could be moved laterally, with some restriction in moving it in caudo-cephalic direction. It appeared to be fixed with the skin and being so much superficial, there was apparently no attachment to the underlying structures. There was no rise of local temperature, scar, sinus, or any other notifiable examination findings. General physical and systemic examination was found as usual for a normal individual.

1. Dr. SM Quamrul Akther, Associate Professor, Department of Surgery, Shaheed Suhrawardy Medical College

2. Dr. Shaon Shahriar, Assistant Professor, Department of Hepatobiliary Surgery, Shaheed Suhrawardy Medical College

3. Dr. Ismat Jahan Lima, Assistant Professor, Department of Colorectal Surgery, Shaheed Suhrawardy Medical College Hospital

4. Dr. Md. Safiqul Islam, Indoor Medical Officer, Department of Surgery, Shaheed Suhrawardy Medical College Hospital

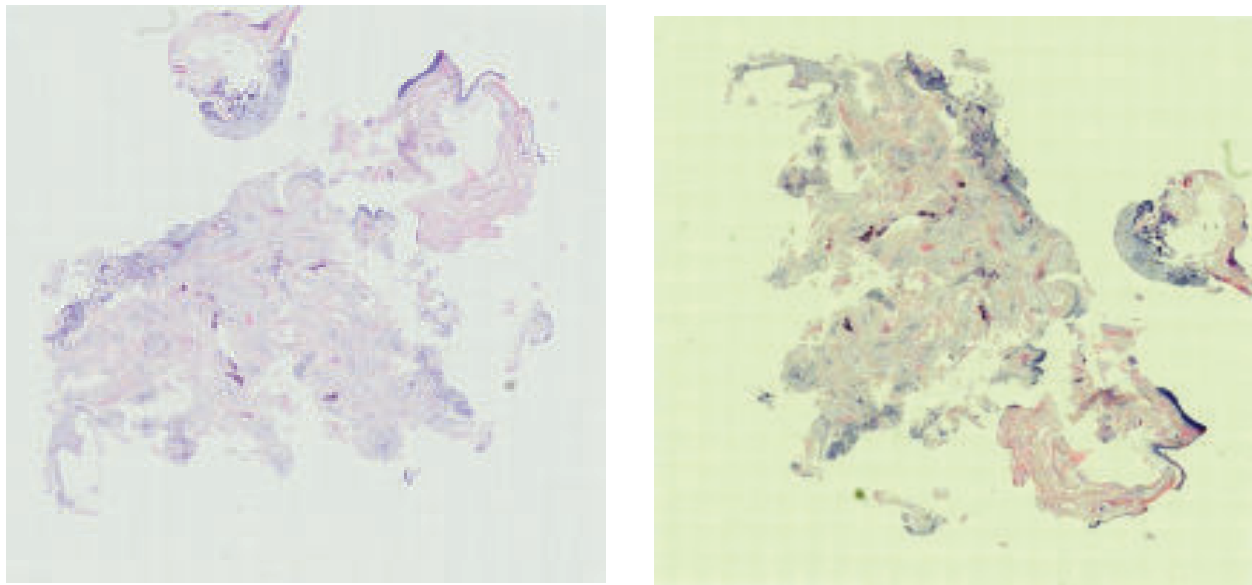
5. Dr. Rajib Dey Sarker, Assistant Registrar, Department of Surgery, Shaheed Suhrawardy Medical College Hospital

6. Dr. Amit Sen Gupta, Assistant Registrar, Department of Surgery, Shaheed Suhrawardy Medical College Hospital

7. Dr. Nuzhat Nawal Medha, Trainee, Department of Surgery, Shaheed Suhrawardy Medical College Hospital

8. Zinnat Sultana Ishita, Trainee, Department of Surgery, Shaheed Suhrawardy Medical College Hospital

**Correspondence:** Dr. S M Quamrul Akther Sanju, Associate Professor and Unit Chief, Department of Surgery, Shaheed Suhrawardy Medical College, Sher-e-Bangla Nagar, Dhaka-1207, Mobile: 01711 059 879, Email: [qa\\_sanju@yahoo.com](mailto:qa_sanju@yahoo.com)



**Fig.-1:** Photomicrograph showing basaloid cell at the periphery and non-nucleated “ghost cells” on the right side of the field (H&E, 100x)

A provisional clinical diagnosis of “sebaceous cyst” was made and planned for excision. So routine serological investigations were progresses. The swelling was excised under local anesthesia (0.5% Bupivacaine and 2% Lidocaine HCl) and sent for histopathological examination. When the histopathology reports arrived, it was nominated and described as suggestive of ‘pilomatricoma’.

### Discussion

Pilomatricoma is a relatively rare neoplasia of ectodermal origin, probably from the outer root sheath cell of the hair follicle.<sup>1</sup> Though age has no influence on this lesion, incidence peaks on the first, second and sixth decades of life. Just alike this case, young women are more prone to develop (Female : Male = 1.5-2.5 : 1). 40% cases were reported to occur before 10 years of age and 60% before 20 years.<sup>2,6</sup> We better to go deep to its pathology that says, when follicles of hair are located in very deep layers of dermis, the act of differentiation induction agents may hamper or do not act with proper intensity. Pilomatricoma is formed from this inaccurate differentiation.<sup>2</sup> Some familial diseases are widely related to this disease, such as Gardner’s syndrome, Steinerd’s disease, and Sarcoidosis.<sup>7</sup>

There may be a great dilemma in reaching diagnosis clinically. Merkel cell carcinoma, Basalioma, Metastatic small cell carcinoma of adults may be mistakenly taken in differentials in favour of the pathology.<sup>8</sup> Sometimes owing to these diagnosis, a more aggressive protocol of treatment gets adopted. A recent study suggests that trisomy-18 is a consistent feature in pilomatricoma, suggesting that genes carried on this chromosome such as that for the

antiapoptotic oncoprotein BCL2 may have a role in the growth and differentiation of this benign self-limited tumor.<sup>9</sup>

Clinically pilomatricoma is a slow developing swelling, with irregular contour, which is fixed to the skin but slides freely over the underlying tissues, often with a discoloration like fleshy or pinkish texture, which varies from red to bluish-purple.<sup>10</sup>

It is quite often to misdiagnose this lesion, even in presence of aberrant clinical features, that mimics quite a lot number of pathologies of its kind. In a series of 51 histologically proven pilomatricomas, Wells et al announced that the diagnosis during reference was incorrect in 94% of cases, and the preoperative diagnosis was incorrect in 57%<sup>11</sup>. In a recent series of 346 pilomatricomas, the preoperative diagnosis was accurate and consistent with the pathological diagnosis of pilomatricoma in only 28.9% of cases<sup>6</sup>. And Kumaran et al reported a correct preoperative clinical diagnosis in 46% following retrospective review of 78 excised pilomatricomas<sup>11</sup>. Incorrect preoperative diagnoses most commonly included unidentified masses, as well as epidermoid cysts, sebaceous cysts, dermoid cysts, nonspecified cysts, and foreign bodies.<sup>6, 12</sup>

Malignant counterpart should also be taken in discussion and differentials, though rare. Pilomatric carcinoma, rarest of its kind, has been narrated and near about 90 cases have been reported in the literature.<sup>15</sup> This locally advanced malignancy has the immense potential of recurrence. In several cases, metastases have been observed. Many key features are similar between these

benign and malignant counterparts; the primary differentiating characteristics include a high mitotic rate with atypical mitoses, central necrosis, infiltration of the skin and soft tissue, and invasion of lymphatics and vasculature.<sup>15, 16</sup>

Histological analysis from well prepared block demonstrates ghost cells in the center with basophilic nucleated cells in the periphery. Calcification may be a key feature in 70%–95%.<sup>2, 13</sup> Presence of nuclear pleomorphism, atypical mitosis, central necrosis is potentially suggestive of malignancy.<sup>14</sup> Cytomorphologic characteristics are reliable enough for correct preoperative diagnosis in adequate specimens. However, FNAC may be great option for reaching a meaningful diagnosis in addition to significant clinical data, but definitely in expert hand and under expert eyes.<sup>8</sup>

The mainstay of treatment is surgical excision with definite clear margins. Incomplete excision may invite recurrence.<sup>10</sup>

### Competing Interest

The authors and coauthors declare that they have no competing interest.

### References

1. T A da Silva et al. Pilomatricoma of the Auricular Region: Case Report, *Braz Dent J* (2003) 14(3): 223-226
2. Fernandes R, Holmes J, Mullenix C. Giant pilomatricoma (epithelioma of Melherbe): Report of a case and review of literature. *J Oral Maxillofac Surg.* 2003;61:634–6.
3. Moehlenbeck FW. Pilomatricoma (calcifying epithelioma).A statistical study. *Arch Dermatol.* 1973;108:132–4.
4. Urvoy M, Legall F, Toulemont PJ, Chevrant-Breton J. [Multiple pilomatricoma. Apropos of a case] *J Fr Ophthalmol.* 1996;19:464–6.
5. Greene RM, McGuff HS, Miller FR. Pilomatricoma of the face: A benign skin appendage mimicking squamous cell carcinoma. *Otolaryngol Head Neck Surg.* 2004;130:483–5.
6. Pirouzmanesh A, Reinisch JF, Gonzalez-Gomez I, Smith EM, Meara JG. Pilomatricoma: A review of 346 cases. *Plast Reconstr Surg.* 2003;112:1784–9.
7. Hubbard VG, Whittaker SJ. Multiple Familial Pilomatricomas. An Unusual Case. *J Cutan Pathol.* 2004;31:281–3.
8. Seili-Bekafigo I, Jonjia N, Stemberger C, Rajkovic-Molek K. Additional cytomorphological criteria in diagnosis of pilomatricoma—benign tumor with bad reputation. *Coll Antropol.* 2010;34:117–22.
9. Agoston AT, Liang CW, Richkind KE, Fletcher JA, Vargas SO. Trisomy 18 is a consistent cytogenetic feature in pilomatricoma. *Mod Pathol.* 2010;23:1147–50.
10. Roche NA, Monstrey SJ, Matton GE. Pilomatricoma in children: Common but often misdiagnosed. *Acta Chir Belg.* 2010;110:250–4.
11. Wells NJ, Blair GK, Magee JF, Whiteman DM. Pilomatricoma: A common, benign childhood skin tumor. *Can J Surg.* 1994;37:483–6.
12. Kumaran N, Azmy A, Carachi R, Raine PA, Macfarlane JH, Howatson AG. Pilomatricoma – accuracy of clinical diagnosis. *J Pediatr Surg.* 2006;41:1755–8.
13. Lan MY, Lan MC, Ho CY, Li WY, Lin CZ. Pilomatricoma of the head and neck: A retrospective review of 179 cases. *Arch Otolaryngol Head Neck Surg.* 2003;129:1327–30.
14. Phyu KK, Bradley PJ. Pilomatricoma in the parotid region. *J Laryngol Otol.* 2001;115:1026–8.
15. Dutta R, Boadle R, Ng T. Pilomatric carcinoma: Case report and review of the literature. *Pathology.* 2001;33:248–51.
16. Mikhaeel NG, Spittle MF. Malignant pilomatricoma with multiple local recurrences and distant metastases: A case report and review of the literature. *Clin Oncol (R Coll Radiol)* 2001;13:386–9.