

## Acute Kidney Injury after ingestion of Star fruit juice in patients with previous history of acute kidney injury: Two case reports

Islam SF<sup>1</sup>, Hadiuzzaman KBM<sup>2</sup>, Morshed SM<sup>3</sup>, Faroque MO<sup>4</sup>, Hamid AH<sup>5</sup>, Hasan MF<sup>6</sup>, Fahad GF<sup>7</sup>

### Abstract

Acute kidney injury can occur due to various reasons. In this case report two cases of acute kidney injury (AKI) were reported after ingestion of 250 ml of starfruit juice presented. In both cases features of nephrotoxicity and neurotoxicity were found and there was mild to moderate rise in serum creatinine. Routine and microscopic examination of urine showed mild degree of proteinuria, no other active urinary sediment was found except calcium oxalate crystals. Renal biopsy was done in both cases which showed features of acute tubular necrosis. These two patients were treated symptomatically and discharged with normal serum creatinine. There is no case report of acute kidney injury due to star fruit ingestion in Bangladesh. Star fruit is very popular, cheap and easily available. But its nephrotoxic effect is not known to general population. These two case reports might be a first time message to the nation. [J Shaheed Suhrawardy Med Coll, December 2015;7(1):33-35]

**Key Words:** Acute kidney injury, nephrotoxicity, starfruit juice

**Received:** July 2014; **Revised:** October 2014; **Accepted:** November 2014

### Introduction

Star fruit, whose scientific name is carambola and as its cross section showed star shaped, so people used to call it 'star fruit'. Star fruits are native to Asia, especially Bangladesh, India, Sri Lanka, Malaysia, acclimatized to many other tropical countries such as Brazil, Southern China, Taiwan and gaining popularity in the United States. It belongs to Oxalidaceae family, species *Averrhoa carambola*. Carambola (Starfruit) is rich in oxalic acid antioxidants, potassium, and vitamin C and Recently identified chemical compound, caramboxin, which is structurally similar to phenylalanine which is a neurotoxin<sup>1</sup>. Oxalic acid ( $H_2C_2O_4$ ) is a colorless crystal. In terms of acid strength, it is about 3,000 times stronger than acetic acid. Its conjugate base, known as oxalate ( $C_2O_4^{2-}$ )-is a reducing agent as well as a chelating agent for metal cations. Oxalic acid binds with calcium to form calcium oxalate crystals which may deposit and cause damage to many areas of the body including the brain, heart, kidneys, and lungs<sup>1</sup>. The most significant effect is accumulation of calcium oxalate crystals in the kidneys

which causes kidney damage leading to oliguric or anuric acute kidney injury<sup>2</sup>. Combined effect of Caramboxin and oxalic acid is double harmful<sup>3</sup>.

There are many case reports and case series of star fruit neurotoxicity and deterioration of renal function in chronic kidney disease patients, before dialysis and also on dialysis treatment<sup>4-6</sup>. There are few case reports of nephrotoxicity after star fruit juice ingestion in individuals with normal renal function<sup>7</sup>. Here two cases of AKI were reported following star fruit juice ingestion having previous history of AKI.

### Case Presentation 1

A 32 years old man, nondiabetic, hypertensive, textile Engineer admitted in the Department of Nephrology at Bangabandhu Sheikh Mujib Medical University (BSMMU), Dhaka with the complaints of upper abdominal discomfort, nausea and vomiting for 3 days. Symptoms developed 4 hours after drinking a glass of star fruit juice. Vomiting was 4-5 times per day, moderate in amount, not

1. Dr. Sayed Fazlul Islam, Medical Officer, Department of Nephrology, Bangabandhu Sheikh Mujib Medical University, Dhaka
2. Dr. KBM Hadizzaman, Assistant Professor, Department of Nephrology, Bangabandhu Sheikh Mujib Medical University, Dhaka
3. Dr. Syed Mahbub Morshed, Assistant Professor Department of Nephrology, Shaheed Suhrawardy Medical College, Dhaka
4. Dr. Md. Omar Faroque, Assistant Professor, Department of Nephrology, Bangabandhu Sheikh Mujib Medical University, Dhaka
5. Dr. AH Hamid Ahmed, Associate Professor, Department of Nephrology, Bangabandhu Sheikh Mujib Medical University, Dhaka
6. Dr. Md. Forhad Hasan, Medical Officer, Mughda General Hospital, Dhaka
7. Dr. Golam Fahad Bhuiyan, Assistant Registrar, Department of Medicine, Shaheed Suhrawardy Medical College Hospital, Dhaka

### Correspondence

Dr. Syed Fazlul Islam, Medical Officer, Department of Nephrology, Bangabandhu Sheikh Mujib Medical University, Dhaka, Bangladesh; Email: milton\_113@yahoo.com; Cell no.:

**Contribution to authors:** SFI, KBMH, MOF & MFH were managed the patients. SMM & GFB wrote the manuscript.

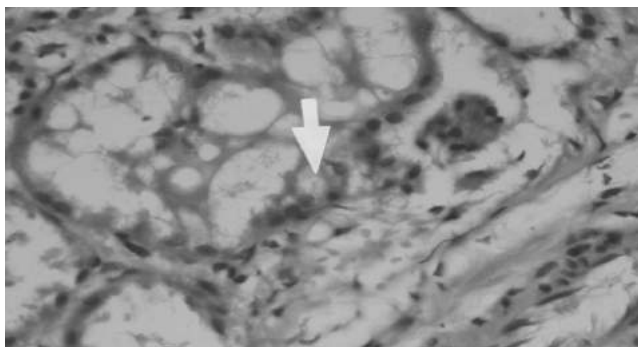


Figure 1: Renal Biopsy (40 magnification) Suggestive of ATN

associated with loose motion. Urine output was reduced. The patient had history of acute kidney injury 6 months back following Gastroenteritis from which the patient was recovered completely. After admission, patient was evaluated properly and on physical examination pulse was normal (80 beat/min) and blood pressure was low (90/60 mmHg). Patient was not anaemic, icteric or edematous. Systemic examination was normal. Bed side urine examination showed mild proteinuria. On routine investigations, urine examination revealed albumin in trace, significant pus cells (10-12/HPF), normal RBC (0-2/HPF), no cast but calcium oxalate crystals were found. Urine specific gravity was 1.002, urine osmolality 400 mosm/kg. 24 hours urinary total protein was 0.4 gm. Complete blood count- Hb 12.6 gm/dl, ESR 50mm in 1st hour, total WBC count was normal (9500/cmm), differential count were N 75%, L 18%, M 05%, E 02%. Serum creatinine was 400  $\mu$ mol/L; urea was normal (6.4 mmol/l), random blood sugar was normal (6.4 mmol/L); serum electrolytes were normal; liver function test was normal. Antinuclear antibody, anti double stranded DNA were negative; C3 and C4 normal; perinuclear antineutrophil cytoplasmic antibody (pANCA) and cytoplasmic antineutrophil cytoplasmic antibody (cANCA) were normal. USG kidneys were normal in size with increased cortical echogenicity. Renal biopsy showed 6 glomeruli. Glomeuli were normal, GBM normal. Most of the tubules were dilated, the lining epithelial cells showed cytoplasmic vacuolation or sloughing. In some tubules lining epithelium was flattened. Few other tubules contain polymorphs and necrotic debris. Interstitium reveals focal infiltration of acute and chronic inflammatory cells. Blood vessels show mild hyaline change features suggestive of acute tubular necrosis (ATN).

### Case Presentation 2

A 45 years old businessman, nondiabetic, normotensive admitted in the Nephrology department of BSMMU with the complaints of nausea and vomiting started after drinking about 250ml(one glass) of star fruit juice. Vomiting was profuse 4-5 times/day associated with reduced urine output. After admission, patient was evaluated and on physical examination found, pulse 80 beats/min, blood pressure-100/70 mm Hg, temperature

98.60 F. Patient was not anaemic, icteric or edematous. Systemic examination revealed no abnormality. He had also history of AKI about 5 yrs back due to acute pyelonephritis with septicaemia. Investigations revealed Hb% - 11gm/dl, ESR - 60 mm in 1st hr, urine R/M/E showed albumin +, pus cell- 6-8/HPF, RBC 1-2/HPF, plenty of oxalate crystals, no cast, urinary total protein - 0.6 gm/24 hrs. Serum creatinine was 2.7 mg/dl on admission which gradually declined to 1.6 mg/dl over week, liver function test was normal, c- ANCA and p-ANCA were negative, complements were normal. Ultrasonography showed normal size kidneys with increased cortical echogenicity. Renal biopsy showed 10 normal glomeruli. Most of the tubules were dilated with flattening of tubular cells. Interstitium showed infiltration of acute inflammatory cells suggestive of acute tubular necrosis(ATN).

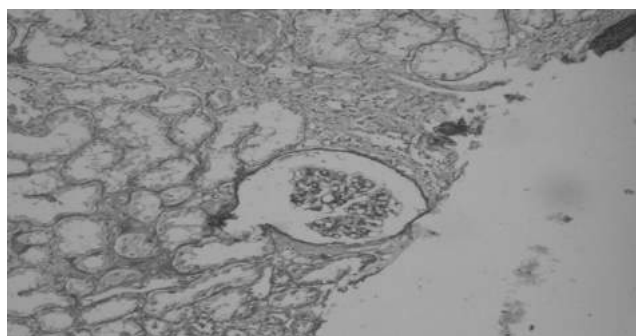


Figure 2: Renal Biopsy(10 magnification) ATN

Both the patients were treated and discharged after clinical improvement and during discharge their serum creatinine level was 1.4 mg/dl.

### Discussion

Ingestion of star fruit and other plants containing oxalates may cause nephrotoxic and neurotoxic effects in humans and animals<sup>8</sup>. Fang et al<sup>9-10</sup> showed that star fruit with abundant oxalate content could cause acute oxalate nephropathy in rats. According to these authors, acute kidney injury is provoked by oxalate not only through the obstructive effect of calcium oxalate crystals but also by inducing apoptosis of renal epithelial cells.

There are only few studies about nephrotoxicity in normal renal function people. Chen et al<sup>11</sup> in their study reported two cases of acute renal failure (ARF) due to acute oxalate nephropathy in patients with previous normal renal function. These patients developed nausea, vomiting, abdominal pain, and backache within hours of ingesting large quantities of sour carambola juice; followed by acute renal failure. Both patients needed hemodialysis for oliguric acute renal failure, and pathologic examinations showed typical changes of acute oxalate nephropathy. The renal function recovered 4 weeks later without specific treatment. Miguel Moyses Neto et al<sup>12</sup> in their study showed five patients with previously normal renal function

who became intoxicated from eating star fruit or drinking star fruit juice and presented simultaneously nephrotoxic and neurotoxic effects. They identified five patients with clinical or histological evidence of ARF associated with star fruit ingestion. Four patients ingested a large amount of star fruit and one ingested 300 mL of pure star fruit juice on an empty stomach. The symptoms started 3-8 h after ingestion; four had acute renal failure, which was associated with back pain in three of the cases; four patients displayed simultaneous neurotoxic (intractable hiccups, vomiting and insomnia) and nephrotoxic effects, and one presented with only neurotoxic effects (intractable hiccups). Renal biopsies performed on 2 patients indicated a typical histological appearance of acute tubular necrosis. Renal sections were analysed under polarized light microscopy and showed colourless oxalate crystals with a pattern of birefringence within the tubular lumina. The oxalate crystals displayed a typical black colour after Von Kossa staining.

So far our concern there is no case report of Acute kidney injury after ingestion of star fruit juice in patients have previous history of acute kidney injury (AKI) due to other causes. In these 2 cases, both patients had history of one episode of AKI previously and developed nephrotoxicity after ingestion of one glass (about 250 ml) of star fruit juice. Urine R/M/E of both patients revealed oxalate crystals. Renal biopsy showed histological features of ATN in both cases, oxalate crystals were not able to identify because of these specimens could not examined under polarized light microscopy or stained with Von Kossa.

### Conclusion

Nephrotoxicity and neurotoxicity provoked by ingestion of the star fruit juice is sometimes fatal and far more frequent

than reported. Individuals with normal renal function should be warned to avoid ingestion of large amounts of star fruit juice especially on an empty stomach.

### References

1. Garcia-Cairasco N, Moyses-Neto M, Del Vecchio F, Oliveira JAC, dos Santos FL, Castro OW, Arisi GM, Dantas Mr, Carolino ROG, Coutinho Netto J. Elucidating the neurotoxicity of the star fruit. *Angewandte Chemie International Edition* 2013;52:13067-13070
2. Brent J. Current management of ethylene glycol poisoning. *Drugs* 2001;61 (7): 979-88
3. Human nutrition, food and animal sciences, university of Hawaii; 8th august 2011
4. Neto MM, Robl F, Netto JC. Intoxication by star fruit (*Averrhoa carambola*) in six dialysis patients? (Preliminary report). *Nephrol Dial Transplant* 1998;13:570-572
5. Chang JM, Hwang SJ, Kuo HT, et al. Fatal outcome after ingestion of star fruit (*Averrhoa carambola*) in uremic patients. *Am J Kidney Dis* 2000;35:189-193
6. Neto MM, Da Costa JA, Garcia-Cairasco N, et al. Intoxication by star fruit (*Averrhoa carambola*) in 32 uraemic patients: treatment and outcome. *Nephrol Dial Transplant* 2003;18:120-125
7. Chen CL, Fang HC, Chou KJ, et al. Acute oxalate nephropathy after ingestion of star fruit. *Am J Kidney Dis* 2001;37:418-422.
8. Sanz P, Reig R. Clinical and pathological findings in fatal plant oxalosis: A review. *Am J Forensic Med Pathol* 1992;13:342-345.
9. Fang HC, Chen CL, Wang JS, et al. Acute oxalate nephropathy induced by star fruit in rats. *Am J Kidney Dis* 2001;38:876-880
10. Fang H-C, Lee P-T, Lu P-J, Chen C-L, Chang T-Y, Hsu C-Y, Chung H-M, Chou K-J. Mechanisms of star fruit-induced acute renal failure. *Food and chemical toxicology* 2008;46:1744-1752
11. Niticharoenpong K, Chalermksanyakorn P, Panvichian R, et al. Acute deterioration of renal function induced by star fruit ingestion in a patient with chronic kidney disease. *J Nephrol* 2006;19:682-686
12. Neto MM, Silva GEB, Costa RS, Neto OMM, Garcia-Cairasco N, Lopes NP, Haendchen PFC, Silveira C, Mendes AR, Ramon Filho R. Star fruit: simultaneous neurotoxic and nephrotoxic effects in people with previously normal renal function. *NDT plus* 2009;2:485-488