

Laparoscopy as a Diagnostic Tool in Various Abdominal Conditions

Ahmed N¹, Aziz NMSB², Ahmad S³, Rahman M⁴, Shams NMSA⁵, Sayeed S⁶, Rayhan F⁷

Conflict of Interest: None

Received:

Accepted:

www.banglajol.info/index.php/JSSMC

Abstract

Background: Laparoscopic surgery is now-a-days an established treatment option for diseases like Cholelithiasis, Appendicitis, Hernia etc. But laparoscopy also has a definite role in diagnosis of abdominal diseases. In many cases diagnostic dilemma remains after all basic investigations are done. In some cases clinical findings and investigation findings get contradictory. In both these issues, laparoscopy can play a vital role to achieve a specific diagnosis. In some cases tissue sample can also be obtained for histological diagnosis.

Methods: It was a prospective cross-sectional study of 60 patients selected by randomized sampling method, both male & female, of various abdominal conditions who couldn't be diagnosed by conventional interventions & gave informed written consent. It was done over two years period. We excluded patients with uncontrolled coagulopathy, hemodynamically unstable patients, patients having undergone multiple previous laparotomies and all patients younger than 12 years. Then the initial diagnosis, the laparoscopic diagnosis and the subsequent outcome of this group of patients were evaluated.

Results: A definitive diagnosis was made in 86.66% (52) of cases after laparoscopy while 13.34% (8) cases had no obvious pathology. Laparoscopy changed the clinical diagnosis in 20% (12) cases. Laparoscopic biopsy was taken in 18.33% (11) cases. Mean Operation time was 20 minutes.

Conclusion: Diagnostic laparoscopy is a simple, rapid, effective and accurate tool in evaluating patients with various abdominal conditions in whom conventional methods of investigation have failed to elicit a certain cause.

Key Words:

Laparoscopy, Diagnostic tool,
Abdominal condition

[J Shaheed Suhrawardy Med Coll 2018; 10(1): 31-35]
DOI: <http://dx.doi.org/10.3329/jssmc.v10i1.38901>

Introduction:

Laparoscopy (Greek lapara = Flank, skopeo = to see) is a modern surgical technique where various surgeries of abdominal cavity is performed through small incisions (0.3-1.2 cm), by specialized instruments and visualization is

done by a camera through one of those incisions and its picture/video is displayed live in a TV monitor. This method is a well-established treatment option for diseases like cholelithiasis, appendicitis, hernia etc. Now a days many advanced abdominal surgeries like Abdomino Perineal excision of Rectum (APR), Hysterectomy, choledocolithotomy are also performed by laparoscopy.¹

Although laparoscopy has vastly developed in last 30 years, the history is not that short. Endoscopic procedures to examine rectum were being performed since the time of Hippocrates. The first experimental laparoscopic surgery was performed in Berlin in 1901 by German surgeon George Kelling, who introduced a cystoscope to look into the abdomen of a dog after insufflating it with air. In 1911, Bertram M. Bernheim of John Hopkins Hospital first introduced laparoscopic surgery in USA. His instrument was a proctoscope with ½ inch diameter and ordinary light source. Phillip Mourett first performed Laparoscopic Cholecystectomy using video technique in 1987. Since

1. Dr. Nadim Ahmed, Senior Consultant, Department of Surgery, Shaheed Suhrawardy Medical College & Hospital, Dhaka
2. Dr. Nur Mohammad Sayed Bin Aziz, Junior Consultant of Surgery, 250 Bedded General Hospital, Jamalpur,
3. Dr. Sami Ahmad, Associate Professor, Department of Surgery, Shaheed Suhrawardy Medical College,
4. Prof. Mustafizur Rahman, Professor of Surgery, Shaheed Suhrawardy Medical College,
5. Dr. Nur Mohammed Sharif As Shams, Junior Consultant of Surgery, Upazilla Health Complex, Nagorkanda, Faridpur,
6. Dr. Shovon Sayeed, Junior Consultant, Department of Surgery, Govt. Employees' Hospital, Fulbaria, Dhaka.
7. Dr. Ferdoush Rayhan, Medical Officer, Department of Surgery, Shaheed Suhrawardy Medical College & Hospital, Dhaka

Correspondence to: Dr. Nadim Ahmed, Senior Consultant, Department of Surgery, Shaheed Suhrawardy Medical College Hospital, Dhaka, E-mail: nadimdrmc@gmail.com

then laparoscopy widened its branches in different areas of surgery and gynaecology.¹⁻³

So we see that laparoscopy was primarily a diagnostic tool in its early age.³ Although the surgery through laparoscopy now a days has become a trend, diagnostic role has its definite place in various abdominal conditions.⁴ In cases where diagnostic dilemma remains after clinical examinations and other investigation tools are used, and where there is contradiction between clinical findings and investigation results, laparoscopy is a very useful tool to reach a certain diagnosis. Not only this, in some cases we can also take laparoscopy guided biopsy from intra-abdominal suspicious lesions for tissue diagnosis.⁵⁻⁷

Thus our aim in this study is to find out whether laparoscopy is an efficient investigation tool or not, in cases where other investigations are inconclusive or contradictory with the clinical findings.

Materials and methods:

This is a prospective observational study which was carried out in surgery department of Shaheed Suhrawardy Medical College Hospital from July 2013 to June 2017 (study period: 4 years) where purposive sampling method was done. Patients with abdominal pathology where initial diagnostic workup were inconclusive and where clinical findings were contradictory to investigation findings, were included. Patients with uncontrolled coagulopathy, haemodynamically unstable patients, patients having undergone previous multiple laparotomies, patient younger than 12 years old, patients who needed immediate laparotomy and patients who refused laparoscopy were excluded from the study. In total, 60 patients were selected for the study.

All the selected cases were evaluated clinically and by relevant haematological, radiological and other special investigations. The findings were noted carefully. All the baseline investigations to check the fitness for laparoscopy were done in all cases. Patients were then sent for pre anesthetic check-up in anesthesia department.

The procedures were performed in the operation theater as routine cases, under general anaesthesia, in presence of both surgical and anesthetic team. At first the laparoscopy machine and the instruments were checked whether they were functioning properly or not. After the patient undergone general anesthesia, proper painting and draping was done and 1 cm umbilical port was made by inserting the trocar in blind method. Then CO2 gas was insufflated in the peritoneal cavity upto the standard pressure required for each individual. Then the Hopkins rod lens was connected with the camera and light source and the picture was checked in the monitor. White balance was done. After submerging the tip of the lens in hot water for 1-2 minutes, the lens was introduced into the peritoneal cavity through the umbilical port. The abdominal cavity was inspected in a clockwise or anticlockwise manner, starting from liver which is 11 O clock in position.

Parietal wall was also inspected. The findings were noted properly. Where there was a suspicious lesion found, another one or two 5 mm ports were made to insert proper instruments, biopsy was done and sent for histopathology.

After completing the procedure, if definite surgery was indicated for the pathology identified, it was performed, if possible, by laparoscopic method, or if exploration was indicated, by open method, in the same sitting.

All the findings and details of the procedure was noted properly.

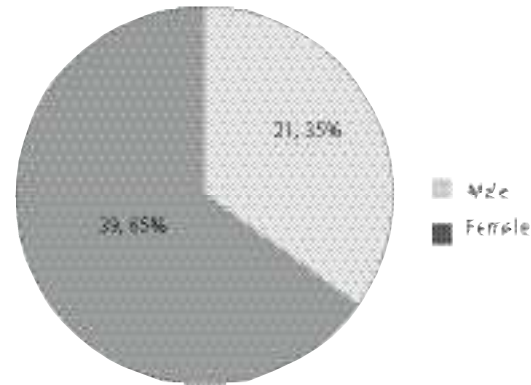


Fig-1: Distribution by sex

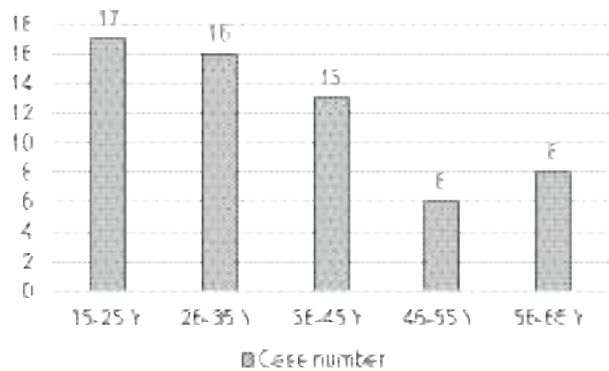


Fig-2: Distribution by age

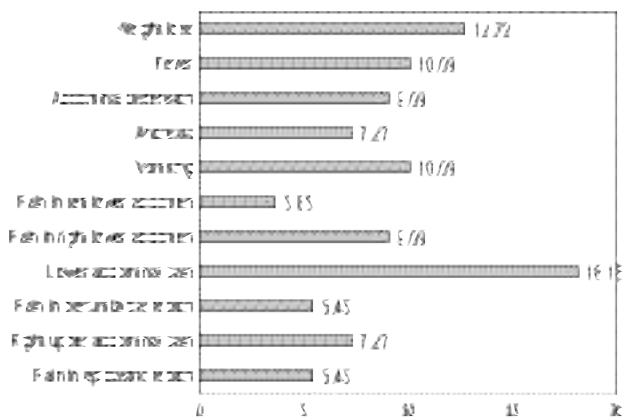


Fig-3: Presenting complain of the patients (n %)

Result:

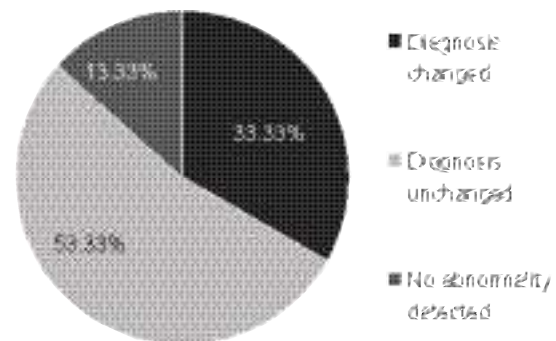
Table-I
Laparoscopic findings:

Finding	Number of patients	Percentage (%)
Lymphadenopathy in lesser omentum with small nodules in multiple sites	4	6.66
Bilateral ovarian tumor with antral mass	1	1.66
Lump in RIF with ascites	2	3.33
Pelvic abscess with adhesion	2	3.33
Mesenteric tear with hemoperitoneum	1	1.66
Pelvic collection	3	5
Tuberculous lesion in multiple sites with ascites and adhesion	8	13.33
Inflamed appendices with adhesion	4	6.66
Appendicular lump	2	3.33
Mild adhesion between bowel loops	6	10
Bands in upper abdomen pressing gut	3	5
Ovarian and adnexal cyst	2	3.33
Lymphadenopathy in multiple sites	5	8.33
Ascites only	4	6.66
Few small nodules in liver surface with ascites	2	3.33
Sub hepatic collection of blood	3	5
Normal finding	8	13.33

Table-II

Final diagnosis

Diagnosis	Number of patients	Percentage (%)
Acute appendicitis	4	6.66
Appendicular lump	1	1.66
Intestinal tuberculosis	15	25
Bands and adhesion	8	13.33
Chronic liver disease	8	13.33
Pelvic abscess	3	5
Acute cholecystitis	2	3.33
Lymphoma	5	8.33
Liver injury	1	1.66
Mesenteric injury	2	3.33
Ovarian cyst	2	3.33
Krukenberg's tumor with gastric primary	1	1.66
Normal finding	8	13.33

**Fig.-4:** Change of diagnosis by laparoscopy**Table-III**

Diagnostic difference between other investigations and laparoscopy:

Diagnosis by other means	Diagnosis by laparoscopy	Number of cases
Distended bowel loops in USG	Bands and adhesion	8
Normal finding in USG	Abdominal lymphadenopathy	6
Bilateral adnexal cyst in CT scan	Bilateral ovarian mass with antral growth	1
Mild pelvic collection in USG	Mesenteric tear with hemoperitoneum	1
Normal finding in USG	Subhepatic collection of blood	2
USG shows Acute calculus cholecystitis	Also left adnexal cyst	1
USG shows lower abdominal mass	Appendicular lump	1

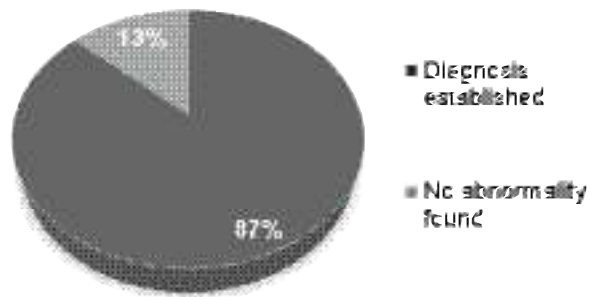


Fig.-5: Diagnosis established by laparoscopy:

Discussion:

Total 60 patients were selected for the study. Due to gynecological entity, the role of diagnostic laparoscopy is more in females, as it shows in this study; 65% patients (39 out of 60) were female, compared to 35% (21 out of 60) male.^{8,9} The diagnostic dilemma is more in younger age, so the role of diagnostic laparoscopy is more in young age (55% of the patients were less than 35 years old).¹⁰ Pain is the most common symptom with which these patients present.¹⁰⁻¹⁵ In this study more than 49% of the patients presented with pain in the different quadrants of the abdomen, with or without other complaints. Lymphadenopathy in different sites (17 patients, 28%) was the most common laparoscopic finding among these patients, due to different causes. Peritoneal collection of blood was found in 4 cases, out of which 1 had mesenteric tear, where other investigations were inconclusive. Thus there is a very important role of diagnostic laparoscopy in blunt and penetrating abdominal trauma.¹⁶⁻¹⁸ This study shows that intestinal tuberculosis is the most difficult disease to diagnose with ordinary investigational tools. Out of 60 patients with diagnostic dilemma, 15 (25%) were diagnosed as intestinal tuberculosis. Another problematic scenario is bands and adhesion (8 patients, 13.33%), which can't be identified with other measures of diagnosis. In this study, initial diagnosis of 33.33% cases (20 patients) were changed by diagnostic laparoscopy which shows the significance of this procedure. And conclusive diagnosis was reached in 87% patients during this study by performing this procedure. Thus the accuracy and efficacy of the procedure is also very high. Laparoscopic biopsy was taken 11 patients (18.33% cases). Mean operation time was 20 minutes.

In our country, many patients present with abdominal conditions which remains undiagnosed till laparotomy. Although diagnostic tools like Ultrasonogram and CT scan have evolved to a great extent, yet many patients are to be treated blindly due to failure to reach a confirm diagnosis.² The treatment therefore doesn't respond in many cases.

Again, some patients with intestinal and peritoneal tuberculosis, and abdominal growth remain undiagnosed till the advanced stage of the disease.¹¹ Some patients with subacute and chronic intestinal obstruction even gets symptom free with blind conservative treatment, and discharged undiagnosed only for coming back with more severe condition later on. In these cases and in many others, diagnostic laparoscopy is a blessing, and this very study shows that.

Conclusion:

This study establishes the fact that Diagnostic laparoscopy is a simple, rapid, effective and accurate tool for evaluating patients with various abdominal conditions in whom conventional methods of diagnosis have failed to elicit a certain cause or where there is a contradiction between clinical picture and investigational findings and certainly helps in re-planning of management. With the continuously developing hazard free anesthetic procedure, laparoscopy can become a very accurate and effective diagnostic tool.

References:

1. A Rubbia, GA Faryal, I Javeria, M Roohul: Role of diagnostic laparoscopy in patients with acute or chronic nonspecific abdominal pain. *World J of Laparoscopic Surg* April 2015, 8:7-12.
2. Kelly Jr WE: The evolution of laparoscopy and the revolution in surgery in the decade of 1990s. *JLS* 2008 oct-dec;12(4):351-357.
3. Litsky GS, Paoulucci V: Origin of laparoscopy: coincidence or surgical interdisciplinary thought. *World J Surg*.1998;22:899-902.
4. Schwaitzberg SD: Diagnostic laparoscopy. *Semin Laparosc Surg* 2002;9(1):10-23.
5. Arya PK, Gaur KJ: Laparoscopy: a tool in diagnosis of lower abdominal pain. *Ind J Surg* 2004;66(4):216-220.
6. Richardson WS, Stefanidis D, Chang L, Earle DB, Fanelli RD: The role of laparoscopy for chronic abdominal conditions: an evidence based review. *Surg Endosc* 2009. Apr 9
7. Easter DW, Cuschieri A, Nathanson LK, Lavelle-Jones M: The utility of diagnostic laparoscopy for abdominal disorders: audit of 120 patients. *Arch Surg* 1992;127(4):379-383.
8. Mais V, Ajossa S, Piras B, Marongiu D, Guerriero S, Melis GB: Treatment of nonendometrioid benign adnexal cysts: a randomized comparison of laparoscopy and laparotomy. *Obstet Gynecol* 1997;177(1):109-114.
9. Experience with diagnostic laparoscopy for gynecological indications
10. Decadt B, Sussman L, Lewis MO, et al: Randomized clinical trial of early laparoscopy in the management of acute non-specific abdominal pain. *BJS* 1999;86(11):1383-1386.
11. Gupta A, Kumar S, Chadha P, et al: Early laparoscopy for abdominal pain. *Correspondence. The Lancet* 2005 Jun;355(ISS 9222):2251.
12. Champault G, Rizk N, Lauray J, et al: Right iliac fossa pain in woman: conventional diagnostic approach versus primary

- laparoscopy: a controlled study(65) cases. *Ann Chir* 1993;47(4):316-319
13. Golash V, Willson PD: Early laparoscopy as a routine procedure in the management of acute abdominal pain: a review of 1320 patients. *Surg Endosc* 2005;19(7):882-885
 14. Reiertsen O, Rosseland AR, Hoivic B, Solheim K: Laparoscopy in patients admitted for acute abdominal pain. *Acta Chir Scand* 1985;12(7):911-914.
 15. Drozgyik I, Vizer M, Szabo I: Significance of laparoscopy in the management of chronic pelvic pain. *Eur J Obstet Gynaecol Reprod Biol* 2007;133(2):223-26.
 16. Paterson Brown S: Emergency laparoscopic surgery. *BJS* 1993;80(3):279-283.
 17. Zanatut LF, Ivatury RR, Smith RS, Kawahara NT, Porter JM, Fry WR, Pogetti R, Birolini D, Organ CHJ: Diagnostic and therapeutic laparoscopy for penetrating abdominal trauma: a multicenter experience. *J Trauma* 1997;42(5):825-829.
 18. 15. Johnson JJ, Garwe T, Raines AR, Thurman JB, Carter S, Bender JS, Albrecht RM: The use of laparoscopy in the diagnosis and treatment of blunt and penetrating abdominal injuries: 10-year experience at a level 1 trauma center. *Am J Surg* 2013 Mar;205(3):317-320.