

Cutaneous Rhinosporidiosis in Lower Limb Mimicking Squamous Cell Carcinoma : A Case Report

Rahman MM¹, Nahar N², Kiron SA³, Uddin MN⁴, Jahan MN⁵, Oishi SJ⁶, Bhakta T⁷, Ray M⁸

Abstract:

Conflict of Interest: None
Received: 16.06.2019
Accepted: 22.09.2019
www.banglajol.info/index.php/JSSMC

Background: Rhinosporidiosis is a chronic granulomatous disease caused by *Rhinosporidium seeberi*. Though cutaneous lesions in Rhinosporidiosis are rare, they may simulate many common dermatological conditions including malignancy thus posing a diagnostic dilemma. Surgical excision is treatment of choice but dapsone can also be used as an adjunct to surgery.

Case Presentation: Here, we are reporting a case where a 45 year old male presented with painless progressive polypoidal growth in the right lower limb for five months with central ulceration. Inguinal lymph nodes were also enlarged. Clinically the lesion appeared to be squamous cell carcinoma. FNAC from inguinal lymph node showed reactive changes and the patient underwent wide local excision of the mass. Histopathological report showed that it was a case of Rhinosporidiosis and the patient was referred to department of dermatology for better management.

Key Words:

Cutaneous, Rhinosporidiosis, squamous cell carcinoma

[J Shaheed Suhrawardy Med Coll 2019; 11(2): 164-166]

DOI: <https://doi.org/10.3329/jssmc.v11i2.48970>

Introduction:

Rhinosporidiosis is a chronic granulomatous infection caused by *Rhinosporidium seeberi*.¹ It can occur in nasopharynx, oropharynx, conjunctiva, rectum and external genitalia. Floor of the nose and inferior turbinate are the most common sites. This disease is endemic in South India, Sri Lanka and Africa with a prevalence rate of 1.4%. Male to female ratio is 1:4 and most cases belong to 15- 40 years of age.² They usually manifest as a sessile or pedunculated vascular polyp in nasal mucosa,

nasopharynx and soft palate. The cutaneous lesions without mucosal involvement are extremely rare and they present as asymptomatic warty growth. This disease also presents to dermatologists and ophthalmologists with the cutaneous, subcutaneous and ocular lesions. Traumatic inoculation from one site to others is common. Rhinosporidiosis is associated with rural and aquatic environments and is transmitted by direct contact with spores through dust, infected clothing or fingers, swimming in stagnant water, trauma and followed by autoinoculation. Hematogenous dissemination is reported to result in painless, firm-to-hard, subcutaneous nodules that remain unattached to skin. Visceral involvement, particularly of the liver, lung, and brain has been reported in disseminated disease.³

Cutaneous lesions in rhinosporidiosis have been reported as pedunculated or sessile growths, verruca vulgaris like lesions, friable nodular lesions, subcutaneous swellings, furunculoid lesions cutaneous horn, cutaneous ulceration and cystic swellings. The various differential diagnoses include warts, verrucous tuberculosis, granuloma pyogenicum and skin malignancy.⁴ Careful inspection of the surface of warty lesions and concurrent or previous history of nasopharyngeal lesions usually help in the diagnosis of cutaneous Rhinosporidiosis.

Though cutaneous lesions in Rhinosporidiosis are rare, they may simulate many common dermatological

1. Prof. Md. Mustafizur Rahman, Professor, Department of Surgery, Shaheed Suhrawardy Medical College, Dhaka
2. Dr. Nazmun Nahar, Honorary Medical Officer, Department of Surgery, Shaheed Suhrawardy Medical College & Hospital, Dhaka
3. Dr. Shah Alam Kiron, Honorary Medical Officer, Department of Surgery, Shaheed Suhrawardy Medical College & Hospital, Dhaka
4. Dr. Md. Nashir Uddin, Honorary Medical Officer, Department of Surgery, Shaheed Suhrawardy Medical College & Hospital, Dhaka
5. Dr. Mst. Nusrat Jahan, Honorary Medical Officer, Department of Surgery, Shaheed Suhrawardy Medical College & Hospital, Dhaka
6. Dr. Sawantee Joarder Oishi, Honorary Medical Officer, Department of Surgery, Shaheed Suhrawardy Medical College & Hospital, Dhaka
7. Dr. Tapan Bhakta, Honorary Medical Officer, Department of Surgery, Shaheed Suhrawardy Medical College & Hospital, Dhaka
8. Dr. Moon Ray, Honorary Medical Officer, Department of Surgery, Shaheed Suhrawardy Medical College & Hospital, Dhaka

Correspondence to: Prof. Md. Mustafizur Rahman, Professor, Department of Surgery, Shaheed Suhrawardy Medical College, Dhaka. Phone: 01711619767, E-Mail: drmustafiz@hotmail.com

conditions thus posing a diagnostic dilemma. Histopathological diagnosis depends on the recognition of sporangia and spores in different stages of maturation with presence of lymphocytes and multinucleated giant cell. The sporangia of *R. seeberi* should be differentiated from the spherules of *Coccidioides immitis*.⁵ The sporangia of *R. seeberi* are larger and thick walled as well as the size and number of endospores on sporangia of *R. seeberi* are also more than those of *C. immitis*. Osteolytic lesions involving the tibia, lateral condyle femur, hand and feet, and calcaneus have been reported. Giemsa imprinted smears and a fine needle aspirate with 10% KOH examination are also helpful for diagnosis Rhinosporidiosis.⁵

Though spontaneous regression can rarely occur, lesions may persist for a long time if untreated. Surgical removal and diathermy excision is the treatment of choice, but still recurrence is common.⁶ Several drugs such as dapsone, ketoconazole, ciprofloxacin and amphotericin B have been tried but dapsone is quite effective. Dapsone is believed to arrest the maturation of the sporangia and induce fibrosis in the stroma. However, it remains an adjunct to surgical removal and electrodesiccation which remain the treatment of choice.⁷

Here, we present a case of A 45 year old male presented with cutaneous Rhinosporidiosis in lower limb mimicking squamous cell carcinoma.

Case summary:

A 45 year old male presented to the department of surgery of Shaheed Suhrawardy Medical College Hospital with the complaints of a painless progressive lump on the medial aspect right leg for 6 months. He had no history of fever, anorexia and weight loss. On examination his vital signs including pulse, blood pressure, respiratory rate and temperature were within normal limits with no systemic abnormality. On local examination there was polypoidal growth in the medial aspect of right leg measuring about 5×3 cm which was non tender firm and mobile. (Fig-1) There was also a centrally placed ulcer over the growth having everted edges. The base was not indurated and floor was covered with unhealthy friable granulation tissue. Right sided inguinal lymph node were also enlarged, non-tender and mobile. The nose and oral cavity did not reveal any lesions. Other systemic examination reveals no abnormality. Clinical diagnosis was squamous cell carcinoma.

His laboratory investigations including complete blood count, random blood sugar, renal function tests, liver function tests, chest X-ray and ECG were within normal limits. FNAC of inguinal lymph nodes showed reactive changes.

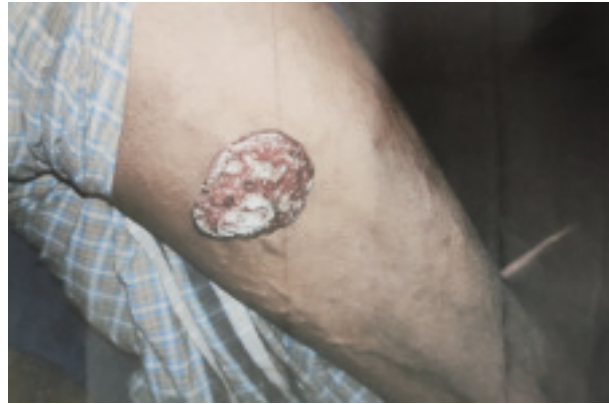

Fig-1: Showing a mass in the right leg with central ulceration

With this clinical scenario the patient was planned for wide local excision and the specimen was sent for histopathology. Histopathological report showed Rhinosporidiosis as evidenced by presence of sporangium of *R. seeberi* and respiratory epithelium. (Fig-2) Consultation from department of dermatology was taken for further management and advised for histopathology slide review. Post-operatively the patient developed wound dehiscence which was closed by secondary closure on 14th post-operative day. The patient was discharged with advice for regular follow up.

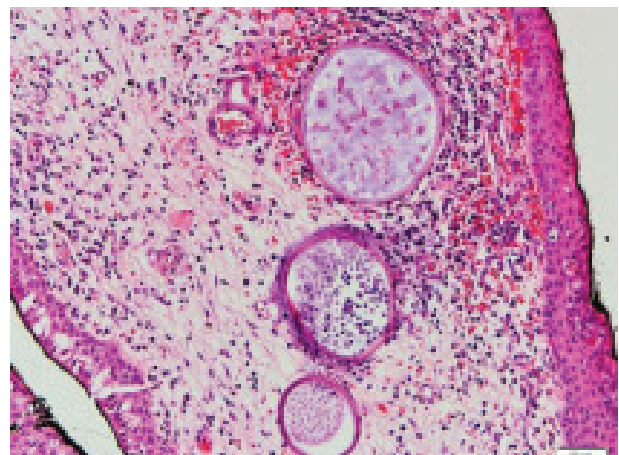


Fig-2: Showing histopathological view of Rhinosporidiosis containing sporangium and multiple giant cells

Discussion:

Rhinosporidiosis is a chronic granulomatous disease which was first reported by Malbran but later described by GuellermoSeeber and hence its name, *Rhinosporidium seeberi*.⁸ Few authors have suggested cyanobacterium *Microcystis aeruginosa* as the causative agent for Rhinosporidiosis.⁸ It is more commonly seen in men than in women.⁹ Bathing in water bodies like lakes filled with stagnant water in areas endemic for Rhinosporidiosis has been considered as a major risk factor. Rhinosporidiosis can manifest in various forms as nasal, ocular, mucosal or cutaneous. Dissemination to anatomically unrelated sites is mainly attributed to haematogenous spread. Disseminated cutaneous lesions are very rare and are generally associated with mucosal lesions. About 20 cases of disseminated cutaneous Rhinosporidiosis have been reported in the literature till date.¹⁰ Careful inspection of the surface of warty lesions and concurrent or previous history of nasopharyngeal lesions usually help in the diagnosis of cutaneous Rhinosporidiosis.

Our patient presented to us with cutaneous manifestation of Rhinosporidiosis with no involvement to nasal mucosa which is very rare. Prasad K and Veena S had reported similar kind of cases where the patient presented with cutaneous Rhinosporidiosis without involving nasal mucosa.¹¹

Cutaneous Rhinosporidiosis may present as warty papules or nodules with whitish spots, crusting, bleeding and ulceration mimicking cutaneous malignancy which have been reported in previous studies.^{11,12} Our patient also presented in a similar way which mimicked as squamous cell carcinoma.

The treatment for Rhinosporidiosis consists of surgical excision followed by cauterization of the base. Medical therapy with dapsone has proved beneficial. Our case was treated with excision by diathermy which was previously mentioned in the study of Saha et al.¹³

In spite of its recognition, Rhinosporidiosis remains a therapeutic challenge with a high risk of recurrence and occasional widespread and fatal complications. That's why regular follow-up is mandatory for better outcome.

Conclusion:

The case is presented to highlight the importance of early recognition of a common lesion with an uncommon presentation and a proper plan to manage such lesions. A proper evaluation, prompt surgical intervention and regular follow up can provide a better outcome to the patients suffering from Rhinosporidiosis.

References:

1. Dash A, Satpathy S, Devi K, Das BP, Dash K. Cytological diagnosis of rhinosporidiosis with skeletal involvement—a case report. *Indian J Pathol Microbiol.* 2005;48:215–217.
2. Morelli L, Polce M, Pisciole F, Del Nonno F, Covello R, Brenna A, et al. Human nasal rhinosporidiosis: an Italian case report. *Diagn Pathol.* 2006;1:25–27.
3. Aravindan KP, Viswanathan MK, Jose L. Rhinosporidiosis of bone: a case report. *Indian J Pathol Microbiol* 1989;32:312–313
4. Chatterjee PK, Khatua CR, Chatterjee SN, Dastidar N. Recurrent multiple rhinosporidiosis with osteolytic lesions in hand and foot. A case report. *J Laryngol Otol.* 1977;91:729–734.
5. Ho MS, Tay BK. Disseminated rhinosporidiosis. *Ann Acad Med Singapore.* 1986;15:80–83.
6. Agrawal S, Sharma KD, Shrivastava JB. Generalized rhinosporidiosis with visceral involvement: report of a case. *AMA Arch Derm.* 1959;80:22–26.
7. Chatterjee PK, Khatua CR, Chatterjee SN, Dastidar N. Recurrent multiple rhinosporidiosis with osteolytic lesions in hand and foot. A case report. *J Laryngol Otol.* 1977;91:729–734
8. Kumari R, Nath AK, Rajalakshmi R, Adityan B, Thappa DM. Disseminated cutaneous rhinosporidiosis: varied morphological appearances on the skin. *Indian J Dermatol Venerol Leprol.* 2009;75:68–71.
9. Shenoy MM, Girisha BS, Bhandari SK, Peter R. Cutaneous rhinosporidiosis. *Indian J Dermatol Venerol Leprol.* 2007;73:179–188.
10. Thappa DM, Venkatesan S, Sirka CS, Jaisankar TJ, Gopalkrishnan, Ratnakar C. Disseminated cutaneous rhinosporidiosis. *J Dermatol.* 1998;25:527–532.
11. Prasad K, Veena S. Disseminated cutaneous rhinosporidiosis in an immunocompetent male. *Indian J Dermatol Venerol Leprol.* 2007;73:343–345.
12. Padmavathy L, Rao IL, Selvam SS, Sahoo CG. Disseminated cutaneous rhinosporidiosis in a HIV sero-positive patient. *Indian J Dermatol Venerol Leprol.* 2001;67:332–333.
13. Saha W, Acharjya B, Devi B, Sahoo A, Singh N. Disseminated cutaneous rhinosporidiosis. *Indian J Dermatol Venerol Leprol.* 2007;73:185–187.