

## Case Report

# Perforated Meckel's Diverticulum with Pancreatic and Gastric Heterotopia and Acute Peritonitis - A Case Report

Mehjabin M<sup>1</sup>, Kamal M<sup>2</sup>, Talukder MAS<sup>3</sup>, Rahman M<sup>4</sup>, Hoque MM<sup>5</sup>, Ahmed FU<sup>6</sup>, Khan MS<sup>7</sup>, Akhanda MTA<sup>8</sup>

### Abstract

**Conflict of Interest:** None

**Received:** 19.04.2020

**Accepted:** 25.08.2020

[www.banglajol.info/index.php/JSSMC](http://www.banglajol.info/index.php/JSSMC)

### Key Words:

Meckel's diverticulum, Pancreatic heterotopia, Gastric heterotopia, Perforation, Peritonitis

*Meckel's diverticulum, the most common congenital anomaly of small bowel although usually silent, can cause complications like intestinal obstruction, bleeding, diverticulitis, perforation etc. We report a case, which presented with acute onset of severe pain in right iliac fossa which was clinically and sonographically diagnosed as acute appendicitis. Histopathological report of appendix was non specific findings. Four days after appendectomy patient again came with features of acute abdomen. X-ray abdomen showed free gas under diaphragm. Abdomen was explored with a midline incision, a perforated Meckel's diverticulum was found which was managed by wedge resection and repair of the ileum. Histopathological examination of specimen revealed diverticular wall with normal appearing intestinal mucosa and muscle coat which showed two heterotrophic tissues (pancreatic and gastric ) in the wall. These also showed features of perforation and acute peritonitis. This is probably the first case of Meckel's diverticulitis with heterotrophic pancreatic and gastric tissue in Bangladesh.*

[J Shaheed Suhrawardy Med Coll 2020; 12(2): 115-118]

DOI: <https://doi.org/10.3329/jssmc.v12i2.56893>

### Introduction

Meckel's diverticulum is the most common congenital anomaly of the gastrointestinal tract (1–3% of the population in autopsy studies, twice as more frequently found in males). It derives from incomplete obliteration of the yolk stalk (omphalo-mesenteric duct).<sup>1</sup> Meckel's diverticulum is a true diverticulum with all layers of the intestinal wall present. It arises from the antimesenteric

border located usually 100 cm proximal to the ileo-cecal valve, has its own mesentery and blood supply from a terminal branch of the superior mesenteric artery.<sup>2</sup> Diverticula that contain normal ileal mucosa, it may harbor ectopic gastric tissue (~50%), duodenal Brunner's glands, pancreatic acinar tissue, colonic mucosa, endometrium, hepatobiliary tissue, or their combination. Meckel's diverticulum is usually asymptomatic, only about 2% develop a complication over the course of their life. Sixty percent of patients having complications are younger than 2 years, painless bleeding (from peptic ulceration in ectopic gastric mucosa) is the most common.<sup>1,2</sup> Complications of Meckel's diverticulum comprise diverticulitis, iron deficiency anemia, intestinal obstruction and perforation (from foreign bodies, diverticulitis, peptic ulceration or blunt abdominal trauma). A longer diverticulum (length >2 cm) is associated with a higher risk of complications.

Pancreatic and gastric heterotopias are defined as pancreatic and gastric tissues outside their typical location without vascular or anatomical continuity with the pancreas proper or the stomach. The reported incidence of heterotopic pancreas or gastric tissue in the general population is low, ranging from <1% to around 13%.<sup>3</sup> These are rare clinical entities which have been identified in

1. Dr. Monika Mehjabin, Lecturer (Department of pathology) Shaheed Suhrawardy Medical Collage, Dhaka.
2. Dr. Mohammed Kamal, Ex Professor of Pathology, Bangabandhu Sheikh Mujib Medical University, Shahbag, Dhaka.
3. Dr. Md. Abdus Sabur Talukder, Assistant Professor of Medicine, Colonel Malek Medical College, Manikganj,
4. Dr. Mizanur Rahman, Lecturer (Department of pathology) Dhaka Medical Collage, Dhaka.
5. Dr. Md. Mozzamel Hoque, Associate Professor (Department of Surgery) Shaheed Suhrawardy Medical Collage Hospital, Dhaka.
6. Dr. Farhad Uddin Ahmed, Assistant Professor (Department of Surgery) Shaheed Suhrawardy Medical Collage Hospital, Dhaka.
7. Dr. Md. Shamsuddoha Khan, Assistant Registrar (Department of Surgery) Shaheed Suhrawardy Medical Collage Hospital, Dhaka.
8. Dr. Muhammad Tanvir Alam Akhanda, IMO (Department of Surgery) Shaheed Suhrawardy Medical Collage Hospital, Dhaka.

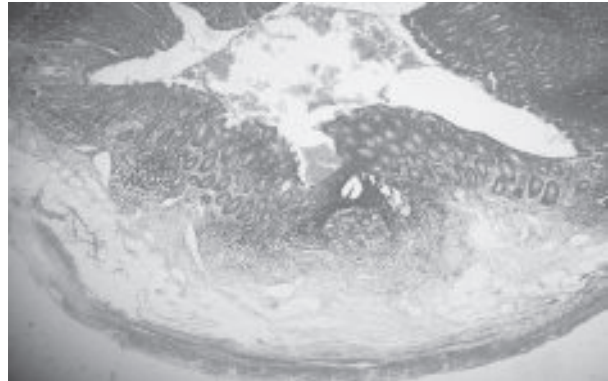
**Correspondence to:** Dr. Monika Mehjabin, Lecturer (Department of Pathology) Shaheed Suhrawardy Medical Collage, Dhaka. Mobile No: 01712278154, E-mail: mehjabin11@gmail.com

virtually the entire length of the gastrointestinal system. However, pancreatic heterotopia is mostly discovered in the stomach, while combined gastric and pancreatic heterotopia is most common in the duodenum and jejunum. Involvement of other organs such as esophagus, terminal ileum, Meckel's diverticulum, colon, ampulla of Vater, gallbladder, spleen, mesentery, liver, bile duct, omentum and urinary bladder are rare but have been previously reported.<sup>4</sup> The clinical significance of pancreatic heterotopia depends on size, location and associated complications. Pancreatic heterotopia often becomes clinically symptomatic when its size reaches 1 cm in the stomach or duodenum, and it may present with pain, anemia, melena or weight loss. Gastric heterotopias, however, can become clinically significant due to sequelae of acid secretion and/or polyp formation. So it was the rare cases where pancreatic and gastric heterotopia were reported together in the Meckel's diverticulum.<sup>2,4</sup>

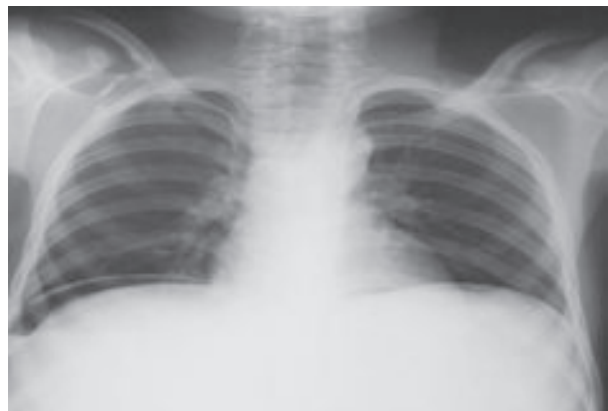
### Case Report

A 17 year old male admitted in Shaheed Suhrawardy Medical College Hospital, Dhaka presented with acute onset of severe pain in right iliac fossa for one day. The pain was so severe that he was admitted to the hospital. On examination he was febrile (102 degree F) with pulse rate of 120 per minute and BP 128/90 mm of Hg. He had nausea and pass vomitus for few times. All hematological parameters (except leucocytosis) were within normal limits. Abdominal examination showed rebound tenderness in right iliac fossa and around the umbilicus. Ultrasonography of the abdomen revealed presence of an inflamed appendix in the right iliac fossa. According to indication, appendectomy was done. Patient was released from hospital after two days. Histopathological report of appendix was non specific change (Figure-1). After four days of surgery patient was again admitted in same hospital presented with abdominal distension. Abdominal examination showed distension of abdomen with rebound tenderness and rigidity all over. X-ray of abdomen in erect posture showed free gas under right dome of diaphragm (Figure-2). A provisional diagnosis was perforation in the site of appendectomy. After resuscitation of the patient, abdomen was explored by midline incision. Peritoneal cavity contained huge collection of pus and peritoneal fluid. Gut adherent was present. After proper suctioning, base of appendix and caecum was checked and these appeared normal. After searching a perforated Meckel's diverticulum was found (Figure-3) which was 5 cm in length in the right lower abdomen. Wedge resection and ileal repair were done. The specimen was sent for histopathological study. Grossly the specimen was (5x2) cm tubular piece of intestinal wall. Serosal surface was

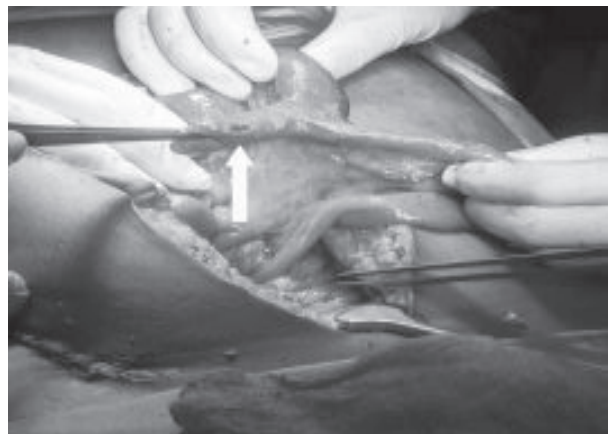
unremarkable. On opening it showed normal appearing mucosa and a small site of perforation (Figure-4). Microscopically it was a diverticular wall revealed normal appearing intestinal mucosa and muscle coat (Figure-5). The mucosa in some areas and muscle coat showed heterotropic pancreatic and gastric tissue (figure 6-7). The serosa also revealed perforation and features of peritonitis (Figure-8).



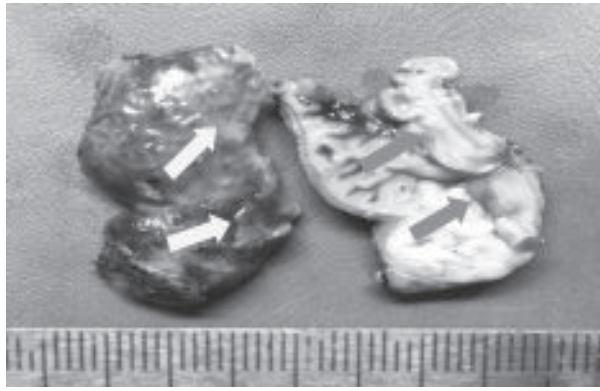
**Fig.-1:** No significant change in Appendix.



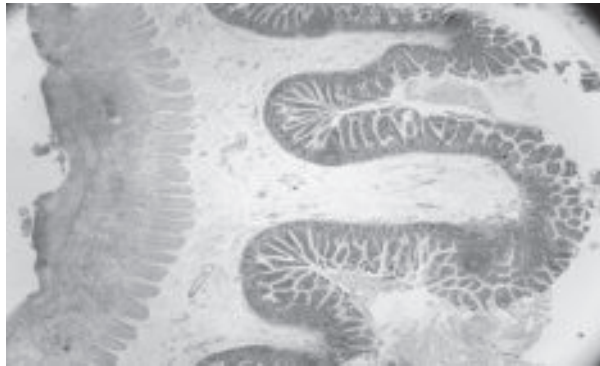
**Fig.-2:** X-ray of abdomen in erect posture (Free Gas Under diaphragm).



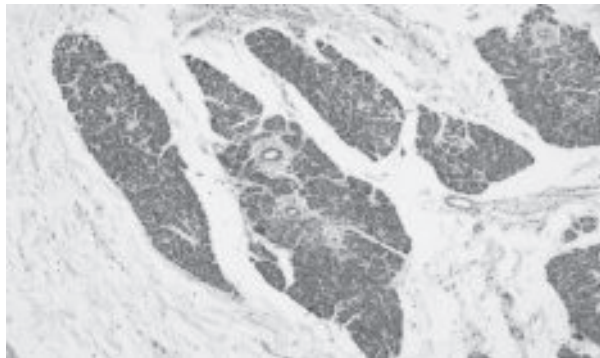
**Fig.-3:** Peroperative photomicrograph of perforated Meckel's Diverticulum.



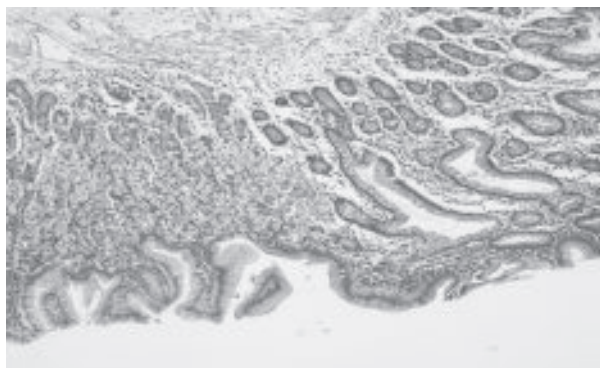
**Fig.-4:** Gross sample of perforated Meckel's diverticulum.



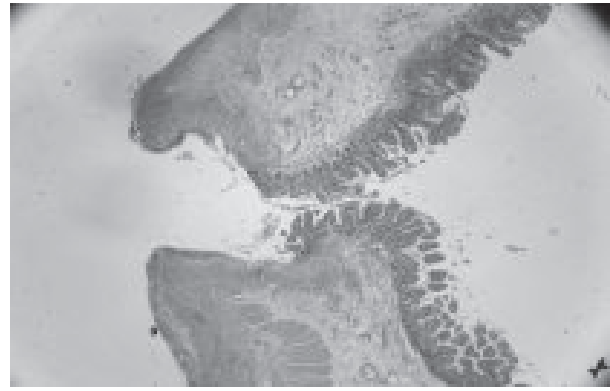**Fig.-5:** Normal appearing intestinal wall of Meckel's Diverticulum.



**Fig.-6:** Heterotopic pancreatic tissue in the wall of Meckel's Diverticulum.



**Fig.-7:** Heterotopic gastric tissue in The wall of Meckel's Diverticulum.



**Fig.-8:** Microscopically perforation with acute peritonitis in Meckel's Diverticulum.

### Discussion

Meckel's diverticulum is the most common congenital anomaly of the gastrointestinal tract.<sup>1,2</sup> The incidence ranges between 1 and 2%, with a lifetime complication risk of 4–6%. Meckel's diverticulum is a true diverticulum, usually found on the anti-mesenteric edge in the ileum.<sup>3,4</sup> The majority of Meckel's Diverticulum are asymptomatic and are incidentally discovered intraoperatively.<sup>5</sup> Perforation is reported to be a consequence of acute inflammation of Meckel's Diverticulum, but the exact percentage of this pathology has not been reported. Ferguson et al published a search of Medline and Embase around 40 case-reports of perforated Meckel's diverticulum over the past 30 years.<sup>6</sup> Perforated Meckel's Diverticulum may present as acute abdomen and resemble acute appendicitis.<sup>7</sup> It is either caused by irritation of foreign body like fish bone, bay leaf, chicken bone, needles and button battery.<sup>8</sup> or following blunt abdominal trauma, which was first described by Park and Lucas in 1970.<sup>9</sup> Neoplastic causes, like GIST or leiomyoma have been also reported.<sup>10</sup> Perforation due to progressive inflammation of Meckel's Diverticulum or ectopic tissue was reported and was present in our case. Diagnosis of Meckel's Diverticulum is notably difficult, as the symptoms and imaging features are non-specific.<sup>11</sup> CT scan and Ultrasound are not diagnostic because they can't differentiate between a diverticulum and a loop of bowel.<sup>12</sup> Meckel-scan with <sup>99m</sup>Tc-pertechnetate may diagnose Meckel's Diverticulum. It can detect the presence ectopic gastric mucosa in cases of complicated Meckel's Diverticulum and can also identify the site of gastrointestinal bleeding. Its accuracy was reported to be around 90% in pediatric series, and only 46% in the adult group.<sup>13</sup> Less than 10% of symptomatic cases of Meckel's Diverticulum are diagnosed preoperatively.<sup>14</sup> In the reported case, at first patient was diagnosed as acute appendicitis. Later patient came with acute abdomen.

Preoperative diagnosis was perforation in appendectomy site. But after opening the abdomen perforated Meckel's diverticulum was found and both heterotropic pancreatic and gastric tissue are present in microscopically, which makes our case exceptional. Surgical resection is considered the treatment of choice for the symptomatic Meckel's Diverticulum. This can be achieved by diverticulectomy, segmental bowel resection and anastomosis, and wedge resection. This is especially applicable when there is palpable ectopic tissue at the diverticular-intestinal junction, intestinal ischemia or perforation. In the reported case, the patient had perforation of a sessile Meckel's Diverticulum. Resection of the involved bowel segment and anastomosis was indicated. Sometimes surgeon may be forced to perform small bowel resection due to the type and extensiveness of complications caused by Meckel's Diverticulum.

### Conclusion

Meckel's Diverticulum is the most common anomaly of the gastrointestinal tract. However, most of them are asymptomatic life long. Clinical symptoms arise from complications of the diverticulum which are very rare in elderly people. Preoperative diagnosis of a complicated Meckel's diverticulum may be challenging because clinical and imaging features overlap with those of other causes of acute abdomen. In case of severe painless acute obscure overt bleeding, Meckel's diverticulum should be considered even in elderly patients. A combination of Meckel's diverticulum with ectopic pancreatic and gastric tissue is extremely rare ;however, it should be kept in mind as a differential diagnosis for every patient presenting with acute abdomen. In cases where the nature of the complication is likely to require surgical management, an early laparoscopic or open exploration should be performed in order to prevent the morbidity and mortality associated with late complications. The treatment should be based on the surgeon's judgment and on the inherent characteristics of each patient.

### Competing Interest

The authors and coauthors declare that they have no competing interest.

### Acknowledgement

I would like to acknowledge greatly Dr. Mohamme Kamal, Ex professor of pathology, BSMMU, for histopathological diagnosis and giving me permission of a case report. I am grateful to him for his guidance, valuable suggestion,

constant supervision, affectionate advice and whole-hearted co-operation.

### References

1. Lu, S.J. and Sinha, A., 2012. Ectopic gastric mucosa in "ectopic" Meckel's diverticulum. *Internal and emergency medicine*, 7 (1), pp.67-69.
2. Wong, C.S., Dupley, L., Varia, H.N., Golka, D. and Linn, T., 2017. Meckel's diverticulitis: a rare entity of Meckel's diverticulum. *Journal of Surgical Case Reports*, 2017 (1).
3. Jiang, K., Stephen, F.O., Jeong, D. and Pimiento, J.M., 2015. Pancreatic and gastric heterotopia with associated submucosal lipoma presenting as a 7-cm obstructive tumor of the ileum: resection with double balloon enteroscopy. *Case Reports in Gastroenterology*, 9(2), pp. 233-240.
4. Shehata, B., Chang, T., Greene, C., Steelman, C., McHugh, M., Zarroug, A. and Ricketts, R., 2011. Gastric heterotopia with extensive involvement of the small intestine associated with congenital short bowel syndrome and intestinal malrotation. *Fetal and pediatric pathology*, 30(1), pp.60-63
5. Carpenter, S.G., McCULLOUGH, A.E., Pasha, S. and Harold, K.L., 2013. Mesenteric Meckel's diverticulum: a real variant. *IJAV*, 6, pp. 145-8.
6. Ferguson, H., Soumian, S. and Dmitreuski, J., 2010. Perforation of Meckel's diverticulum secondary to a large faecolith. *Case Reports*, 2010, p.bcr0920092308.
7. Bani-Hani, K.E. and Shatnawi, N.J., 2004. Meckel's diverticulum: comparison of incidental and symptomatic cases. *World journal of surgery*, 28(9), pp. 917-920.
8. SHINOHARA, T., HIROSE, K., SAJI, Y. and TAKAHASHI, S., 2004. A case of perforation of meckel's diverticulum by a fish bone. *Nihon Rinsho Geka Gakkai Zasshi (Journal of Japan Surgical Association)*, 65(9), pp. 2405-2408.
9. PARK, H. and LUCAS, C.E., 1970. PERFORATED MECKEL'S DIVERTICULUM FOLLOWING BLUNT ABDOMINAL TRAUMA. *Journal of Trauma and Acute Care Surgery* 10(8), pp.706-707.
10. Camelo, R., Santos, P. and Marques, R.M., 2019. Perforated Meckel's Diverticulum in an Adult. *GE-Portuguese Journal of Gastroenterology*, 26(4), pp.285-289.
11. Dimitriou, I., Evaggelou, N., Tavaki, E. and Chatzitheoklytos, E., 2013. Perforation of Meckel's diverticulum by a fish bone presenting as acute appendicitis: a case report. *Journal of medical case reports*, 7(1), pp.1-4.
12. Chabowski, M., Szymanska-Chabowska, A., Dorobisz, T., Janczak, D., Jelen, M. and Janczak, D., 2016. A massive bleeding from a gastrointestinal stromal tumor of a Meckel's diverticulum. *Srpski arhiv za celokupno lekarstvo*, 144(3-4), pp.219-221.
13. Ding, Y., Zhou, Y., Ji, Z., Zhang, J. and Wang, Q., 2012. Laparoscopic management of perforated Meckel's diverticulum in adults. *International Journal of Medical Sciences*, 9(3), p.243.
14. Sharma, R.K. and Jain, V.K., 2008. Emergency surgery for Meckel's diverticulum. *World Journal of Emergency Surgery*, 3(1), p.27.