

Effects of perfluorooctane sulfonate on the hematology and histopathology of juvenile tilapia, *Oreochromis niloticus*

Md. Baki Billah*, Sudip Paul¹, Sabira Sultana, Md. Jahid Hasan and Md. Abdus Salam

Department of Zoology, Jahangirnagar University, Savar, Dhaka-1342, Bangladesh

Abstract

Perfluorooctane sulfonate (PFOS), a persistent organic pollutant, biologically stable in the environment and bio-accumulate in the tissues of aquatic animals as well as wildlife and humans. The toxicity of perfluorooctane sulfonate were tested at 1, 3 and 5mg/L concentrations on the juvenile tilapia, *Oreochromis niloticus* after 7, 15, 30, 45 and 60 days of exposure. The hematological parameters revealed that with the increase in concentrations and exposure time the total count of the RBC, WBC and hemoglobin content were significantly ($p < 0.05$) decreased compared to the control. The histopathological examinations showed that PFOS may induce some changes in kidney and liver. The present results demonstrate that additional research may be conducted to identify the mechanism of perfluorooctane sulfonate toxicity.

Key words: Perfluorooctane sulfonate toxicity, *Oreochromis niloticus*.

INTRODUCTION

Perfluorooctane sulfonate (PFOS) is a fluorinated compound consists of eight carbons. Because of the strong carbon-fluoride bonds they have been extensively used in various industrial and consumer products such as repellent coatings for carpets, leather, and food packaging materials, and as surfactants in diverse cosmetics and fire-fighting foams (Paul *et al.*, 2008). PFOS has attracted wide attention because of its potential toxic effects (Wan *et al.*, 2012). PFOS are globally present in the environment and currently listed under Annex B of the Stockholm Convention in 2009 as one of the nine new persistent organic pollutants (POPs).

As emerging pollutants, PFOS can enter into water, atmosphere, soil, sludge and cause widespread pollution. They can be transferred, bio-accumulated, and biomagnified along food chains and their presence have been found in various tissues of many wildlife species and even in the human body. Marine as well as freshwater species from various geographic locations have been shown to have liver tissue with PFOS concentrations ranging from <5 up to 9031 ng/g wet weight (Giesy & Kannan 2001). PFOS may enter into human body via sea food (fish, crab, mollusk, shrimp and shell fish). It was also

¹ Department of Biochemistry and Molecular Biology, Jahangirnagar University, Savar, Dhaka-1342, Bangladesh

* Corresponding Author E-mail: bakibillah29@gmail.com

showed that PFOS in sea food samples can be found at the range of 0.33 (shell fish) to 13.9 (shrimp) ng/g (Gulkowska *et al.*, 2006).

Toxicological studies suggest that PFOS is correlated with multiple toxicities such as hepatotoxicity, carcinogenicity, immunotoxicity as well as reproductive and developmental effects (Wan *et al.*, 2012). It was reported that prenatal exposure of PFOS causes neonatal rat lung morphological changes and early death, which may be involved in inhibiting lung maturation (Grasty *et al.*, 2005). Previously published research postulated that PFOS could induce hepatocellular hypertrophy and lipid vacuolation and loss of body weight in the rat (Seacat *et al.*, 2002).

Although histological and hematological changes induced by different organophosphate pesticides have been investigated in several fish species (Khattak & Hafeez, 1996; Singh & Srivastava, 1994), but limited information is available regarding the effects of PFOS on tissues and hematological parameters of fish. Therefore, juvenile tilapia, *Oreochromis niloticus* were exposed to different concentrations of PFOS to investigate their toxicity on tissues of some selected organs and haematological parameters.

MATERIALS AND METHODS

Collection of fish: Juvenile tilapia, *Oreochromis niloticus* (2-3 months old) were collected and immediately taken to the fish hatchery and research Centre laboratory of Jahangirnagar University, Savar, Dhaka. Fishes were kept in the aquarium up to 5 days with normal tap water for acclimatization.

Experimental design: Twelve aquariums (25x45cm) were taken and divided into four groups each having three of them. Each aquarium was cleaned with tap water and sodium chloride to make them disinfected. Each aquarium was then filled with 40L of tap water. Then PFOS (98% purity, Sigma Aldrich) were added to the aquariums of group 1, 2, and 3 at a concentration of 1, 3 and 5mg/L respectively. Aquariums of group 4 were used as untreated control i.e. no PFOS were added. In each aquarium, a total of 100 fishes (length 5-6 cm each) were released and reared for 60 days. The mortalities of the fish of each aquarium were recorded after 7, 15, 30, 45, and 60 days of exposure. At 45 and 60 days of exposure period blood samples were collected from the caudal vein of 30 fishes randomly selected from each group. The blood samples were taken in falcon tube with EDTA for subsequent analysis. The hematological parameters (RBC, WBC and hemoglobin content) and morphological observations of RBC were examined (Verma, 1994). Upon sacrifice, the liver and kidney samples were collected from fishes of each group after 60 days of exposure and subsequent histological examinations were carried out following standard procedure (Rahman *et al.*, 2002).

Statistical analysis: Statistical evaluations were conducted by SPSS 16.0. Student's t-test was performed to test the level of significances ($p < 0.05$) of the tested groups.

RESULTS AND DISCUSSION

The percentage mortalities at different concentrations of PFOS (1, 3 and 5mg/L) during 45 and 60 days are presented in Table 1. Death of 2 and 5 percent fishes were recorded after 30 days of exposure at 3mg/L and 5mg/L concentration level. The respective percentage mortalities after 60 days of exposure were 12, 31 and 38 at 1, 3 and 5 mg/L concentration.

Table 1. Percentage mortalities of juvenile tilapia, *Oreochromis niloticus* exposed to different concentrations of PFOS for different days

Concentrations (mg/L)	Percentage mortalities after days of exposure				
	7days	15days	30days	45days	60days
0	0	0	0	0	0
1	0	0	0	9	12
3	0	0	2	16	31
5	0	0	5	29	38

Total count and the morphological changes in RBC: The amounts of total RBC in control group fishes were higher compared to the treated groups. The number of erythrocytes at 1, 3 and 5mg/L of PFOS concentrations decreased significantly ($p < 0.05$) compared to control (Fig.1).

There were no marked differences in the morphology of the erythrocytes of the fishes exposed to 1mg/L of PFOS for both 45 and 60 days and those of control group (data not shown). The fish treated with 3mg/L of PFOS for 45 days exhibited dilated erythrocytes with irregular shape while the fish treated with 3mg/L of PFOS for 60 days showed macrocytic condition. Interestingly, the erythrocytes of the fish treated with 5mg/L of PFOS for 60 days assumed small and rounded in shape (Plate 1).

Total WBC count: The number of total WBC in treated groups (1, 3 and 5mg/L) were significantly lower compared to control ($p < 0.05$) (Fig.1).

Hemoglobin content (Hb): The hemoglobin content in control groups were greater and exhibited the decreasing pattern in treated group fishes ($p < 0.05$) compared with control (Fig.1).

The principal hematological response of tilapia (*Oreochromis niloticus*) to the exposure of PFOS concentrations were a significant decrease in RBC, WBC count and Hb content as compared to the control. These findings are consistent with the findings of some other authors studying the responses of other fishes exposed to organophosphorus pesticides (Singh & Srivastava, 1994; Ramesh & Saravanan, 2008). Similar observations were also reported by Mostafa & Billah (2010) in a study on the formalin effects on some haematological parameters of *Channa punctatus*.

Shamoushaki *et al.*, (2012) reported decreased RBC and Hb in male brood stock (*Rutilus frisii kutum*) after long-term exposure to diazinon. The principal hematological response of Indian carp (*Cirrhinus mrigala*) to the acute exposure of diazinon in 8.15 mg/L concentrations was a significant decrease in RBC, Hb, Hct, and WBC count (Rauf & Arain 2013). The reduction in RBC count and Hb are often accompanied by a decrease in haematocrit and demonstrates the physiological dysfunction of the hemopoietic system.

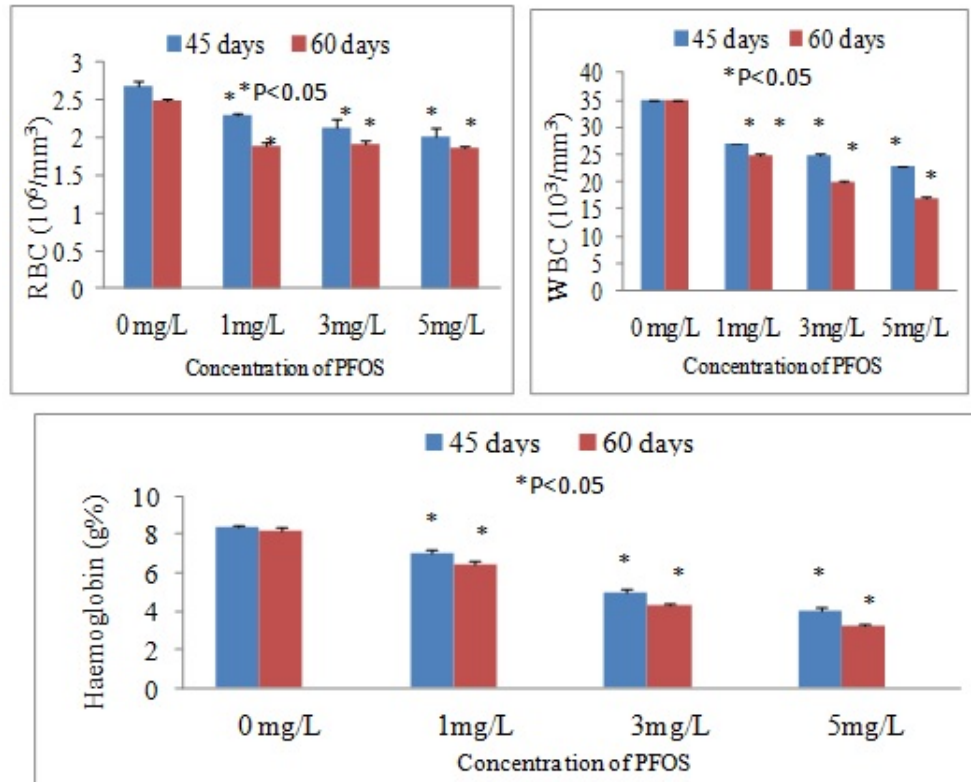


Fig. 1. Total counts of RBC, WBC and hemoglobin contents of juvenile tilapia, *Oreochromis niloticus* exposed to different concentrations of PFOS after 45 and 60 days of exposure

The normal erythrocytes were elliptical with oblique nucleus but the erythrocytes in treated fish assumed small, rounded and dilated in shape. The reduction of RBC may be due to destruction of erythrocytes (Morgan *et al.*, 1980).

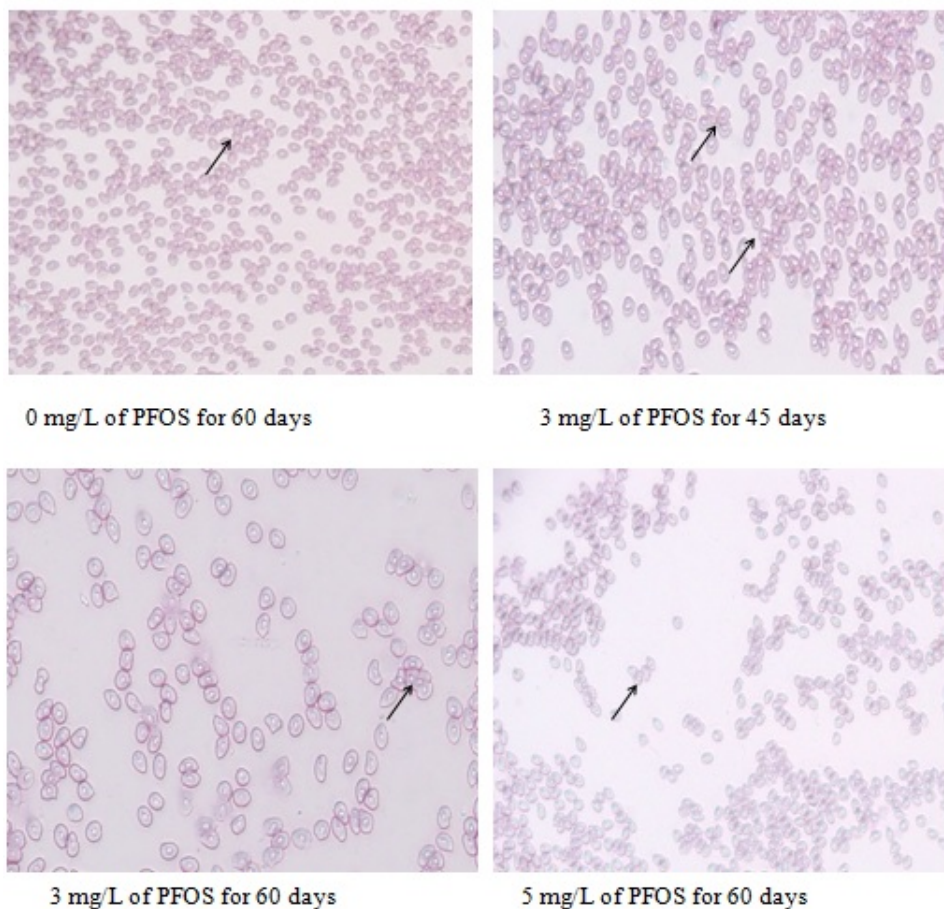


Plate 1. Photomicrographs (20x) of the erythrocytes of juvenile tilapia, *Oreochromis niloticus* exposed to different concentrations of PFOS after 45 and 60 days of exposure

It was also reported that erythrocytes are fundamentally capable of exerting stereotypic responses to a variety of environmental insults (Sawhney & Johal, 2000). Comparing the results of the present study on *Oreochromis Niloticus*, it was assumed that 1, 3 and 5mg/L of PFOS were lethal to fish at 45 and 60 days and induced the alteration of hematological parameters.

Kidney: In control group fish, the glomerulus, renal cells and kidney tubules were normal.

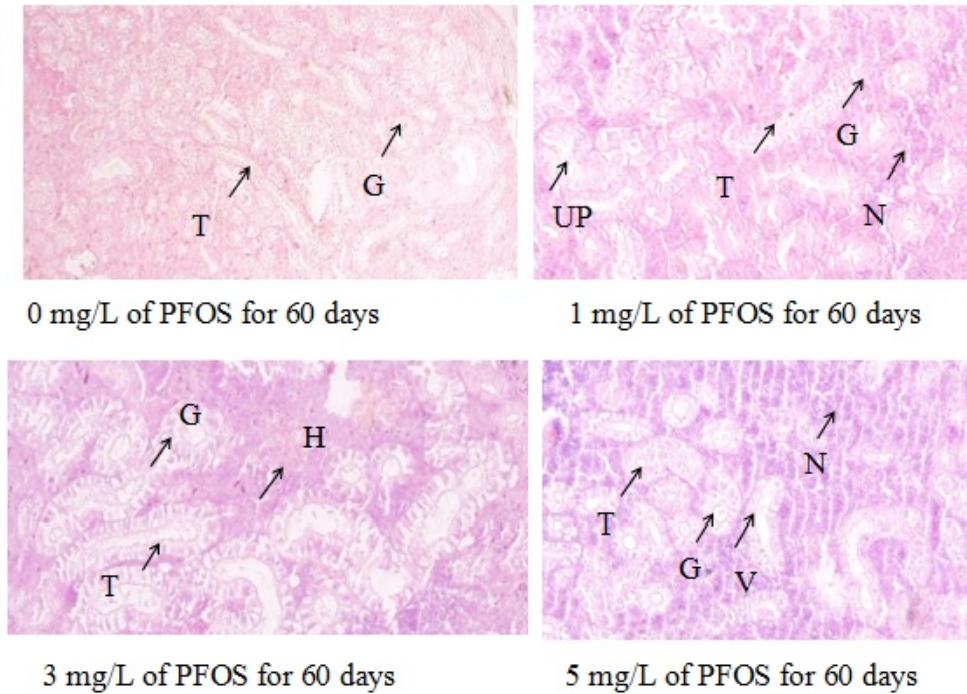


Plate 2. Photomicrographs (40x) of the kidney tissues of juvenile tilapia, *Oreochromis niloticus* exposed to different concentrations of PFOS after 60 days of exposure

* G=Glomerulus, T=kidney tubules, N=necrosis, UP= urinary space, H=hemorrhage and V=vacuoles

The presence of necrosis in the lumen of urinary tract and increase of urinary space were observed in fish exposed to 1mg/L of PFOS while kidney exposed to 3mg/L of PFOS exhibited hemorrhage and the increase of vacuoles in urinary tract. In response to 5mg/L of PFOS, vacuoles, necrosis and haemorrhage were observed in renal cells (Plate 2).

Rahman *et al.*, (2002) studied the effect of Diazinon 60EC on *Anabas testudineus*, *Channa punctatus* and *Barbodes gonionotus* and found degeneration of kidney tubules, necrosis and haemorrhage. Rand & Petrocelli (1985) reported necrosis of tubular and surrounding haematopoietic cells, nuclear changes of pyknosis and karyorrhexis of kidney tissue when coho salmon was exposed to 100 ppm Amitrole for 144 hours. Similar

findings were reported in hematology of Indian catfish by Mishra & Srivastava (1983) who had used non-lethal concentration of Trichlorophon in different time.

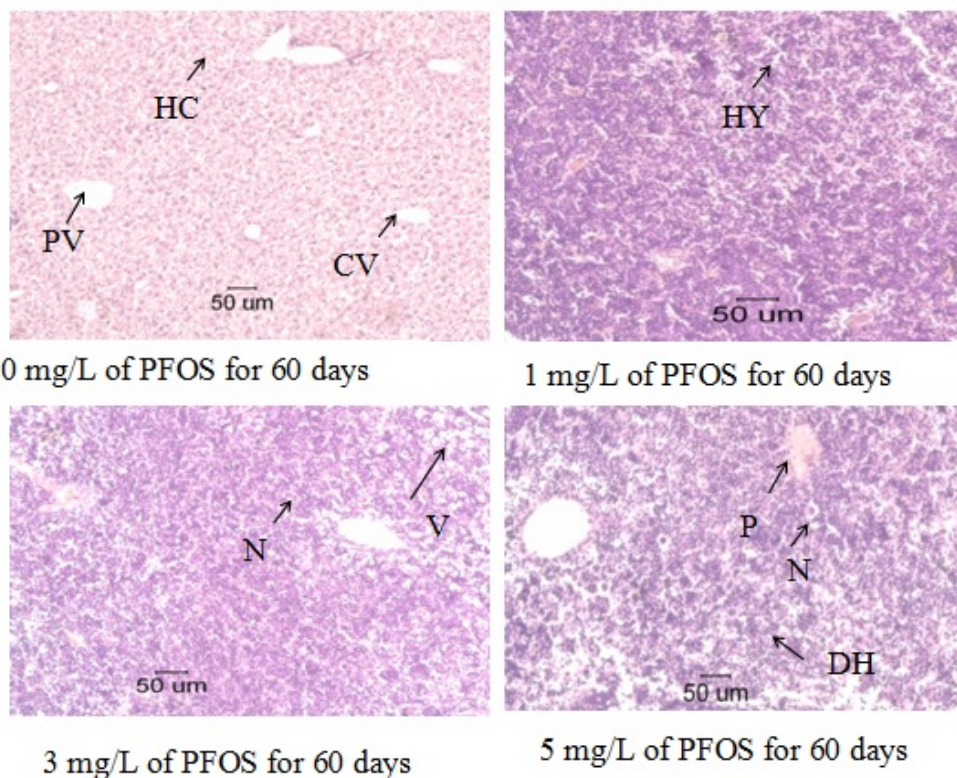


Plate 3. Photomicrographs (40x) of the liver tissues of juvenile tilapia, *Oreochromis niloticus* exposed to different concentrations of PFOS after 60 days of exposure

*HC= Hepatocytes, CV=Central vein, PV= Portal vein, HY= Hypertrophy of hepatocytes, N= Necrosis, V=Vacuoles and DH= Disassociation of hepatocytes

Liver: Fish exposed to 1mg/L of PFOS showed hypertrophy of hepatocytes but necrosis and vacuoles were found in fish liver exposed to 3mg/L of PFOS. In high doses (5mg/L) of PFOS the liver exhibited pycnosis, necrosis, vacuoles and disassociation of hepatocytes (Plate 3). In contrast, control liver showed normal hepatocytes, central and portal vein.

Rahman *et al.*, (2002) studied the effect of Diazinon 60EC on *Anabas testudineus*, *Channa punctatus* and *Barbodes gonionotus* and found severe necrotic hepatocytes, pycnosis, hypertrophy, haemorrhage and vacuolation in liver. Kabir & Begum (1978)

reported cytoplasmic degeneration, pyknotic nuclei in liver tissues, vacuolation in hepatic cells and rupture of blood vessels, degenerative hepatic cells and necrotic nuclei when *Heteroneutes fossilis* was exposed for 25 days to 5, 10 and 20 ppm Diazinon, respectively.

A study on the hepatotoxicity of PFOS and PFOA in tilapia revealed that the doses (10 mg/L) of PFOS exposure led to a marked inhibition in the hepatocyte viability (Han *et al.*, 2012). Comparing the responses on liver of *Oreochromis niloticus* it was assumed that the doses of 1, 3 and 5mg/L of PFOS could incur damage to the fish tissue. Cellular dysfunction is the result of compensatory response in responses to external stressors (Nuwaysir *et al.*, 1999). Therefore, additional new policy measures on PFOS emission should be adopted to protect the deteriorating water quality and public health.

REFERENCES

- Giesy, J.P. and Kannan, K. 2001. Global distribution of perfluorooctane sulfonate in wildlife. *Environ. Sci. Technol.* **35** (7), 1339–1342
- Grasty, R. C., Bjork, J. A., Wallace, K. B., Lau, C. S. and Rogers, J. M. 2005. Effects of prenatal perfluorooctane sulfonate (PFOS) exposure on lung maturation in the perinatal rat. Birth Defects Research Part B: *Developmental and Reproductive Toxicology*, **74**(5), 405–416.
- Gulkowska, A., Jiang, Q., So, M. K., Taniyasu, S., Lam, P. K. and Yamashita, N. 2006. Persistent perfluorinated acids in seafood collected from two cities of China. *Environmental science & technology*, **40**(12), 3736–3741.
- Han, Z., Liu, Y., Wu, D., Zhu, Z. and Lü, C. 2012. Immunotoxicity and hepatotoxicity of PFOS and PFOA in tilapia, (*Oreochromis niloticus*). *Chinese Journal of Geochemistry*, **31**(4), 424–430.
- Kabir, S.M.H. and Begum, R. 1978. Toxicity of three organophosphorus insecticides to Singhi fish, *Heteropneustes fossilis* (Bloch). *Dhaka Univ. Stud. B* **26**: 115–122.
- Khattak, I.U. and Hafeez, M.A. 1996. Effect of malathion on blood parameters of the fish, *Cyprinion watsoni*. *Pak J Zool*, **28**: 45–49.
- Mishra, j. and Srivastava, A. 1983. Trichlorophon induced hematological and biochemical changes in the Indian catfish, *Heteropneustes fossilis*. *Environ Res*; **30** (2):393–8.
- Morgan, D. P., Stockdale, E. M., Roberts, R. J. and Walter, H. W. 1980. Anemia associated with exposure to lindane. *Arch Environ Health*, **35**: 307–310.
- Mostafa, M.G. and Billah, M.B. 2010. Effects of formalin on some haematological parameters of *Channa punctatus*. *Bangladesh J. Life Sci.* **22**(2): 99–103.
- Nuwaysir, E.F., Bittner, M., Trent, J., Barrett, J.C. and Afshari, C.A., 1999. Microarrays and toxicology: the advent of toxicogenomics. *Mol. Carcinogen.* **24**:153–159.
- Paul, A. G., Jones, K. C. and Sweetman, A. J. 2008. A first global production, emission, and environmental inventory for perfluorooctane sulfonate. *Environmental Science & Technology*, **43**(2):386–392.
- Rahman, M. Z., Hossain, Z., Mollah, M. F. A. and Ahmed, G. U. 2002. Effect of Diazinon 60 EC on *Anabas testudineus*, *Channa punctatus* and *Barbodes gonionotus*. Naga, The ICLARM Quarterly, **25**(2), 8–12.
- Ramesh, M. and Saravanan, M. 2008. Hematological and biochemical responses in freshwater fish, *Cyprinus carpio* exposed to chlorpyrifos. *Int J Integ Bio* **3**: 80–84.

- Rand, G.M. and Petrocelli, S.R. 1985. **Fundamentals of aquatic toxicology**. Hemisphere Publishing Corporation, Washington. 666 p.
- Rauf, A. and Arain, N. 2013. Acute toxicity of diazinon and its effects on hematological parameters in the Indian carp, *Cirrhinus mrigala* (Hamilton). *Turkish Journal of Veterinary and Animal Sciences*, **37**(5), 535-40.
- Sawhney, A.K. and Johal, M.S. 2000. Erythrocyte alterations induced by malathion in *Channa punctatus* (Bloch). *Bulletin of environmental contamination and toxicology*, **64**(3), 398-405.
- Seacat, A.M., Thomford, P.J., Hansen, K.J., Olsen, G.W., Case, M.T. and Butenhoff, J.L., 2002. Subchronic toxicity studies on perfluoro octanesulfonate potassium salt in cynomolgus monkeys. *Toxicol. Sci.* **68**, 249-264.
- Shamoushaki, M. N., Soltani, M., Kamali, A., Imanpoor, M. R., Sharifpour, I. and Khara, H. 2012. Effects of organophosphate, diazinon on some haematological and biochemical changes in *Rutilus frisii kutum* male brood stocks. *Iran J Fish Sci*, **1**: 105-117.
- Singh, N. N. and Srivastava, A. K. 1994. Formothion induced hematological changes in the freshwater Indian cat fish, *Heteropneustes fossilis*. *J Ecotox Environ Monit*, **4**: 137-140.
- Verma, P.S. 1994. **A Manual of Practical Zoology Chordates**. 10th ed. S. Chand & Co.Ltd. New Delhi. Pp 395-401.
- Wan, H. T., Zhao, Y. G., Wei, X., Hui, K. Y., Giesy, J. P. and Wong, C. K. 2012. PFOS-induced hepatic steatosis, the mechanistic actions on β -oxidation and lipid transport. *Biochimica et Biophysica Acta (BBA)-General Subjects*, **1820** (7), 1092-1101.