

## Original Article



# Efficacy of Ultrasono-Guided Caudal Epidural Steroid in Lumbar Disc Prolapse

Mohammad Moniruzzaman<sup>1</sup>, Muhammad Alamgir Mandal<sup>2</sup>, M. Matiur Rahman<sup>3</sup>,  
Syed Mozaffar Ahmed<sup>4</sup>, Md. Mustafizur Rahman<sup>5</sup>, Md. Ali Emran<sup>6</sup>, Md. Nuruzzaman Khandaker<sup>7</sup>.

### Abstract

**Background:** Ultrasono-guided caudal epidural steroid injections are used for the treatment of radicular lumbosacral pain syndromes with the safest, easiest, and minimal risk. **Objective:** The study is to show efficacy of ultrasono-guided caudal epidural steroid in acute and chronic low back pain due to prolapsed lumbar intervertebral disc (PLID). **Materials and Methods:** Thirty consecutive patients with acute and chronic low back pain with radiculopathy and without red flag sign where clinical diagnosis were prospectively included in this study in Popular Medical College Hospital, Dhanmondi, Dhaka. **Results:** The mean age was  $40.83 \pm 13.34$  (mean  $\pm$  SD). Male and female ratio was 3:2. Regarding diagnosis, 56.66% were acute and 43.33% were chronic low back pain in which 40% had lumbar canal stenosis, 70% had right sided radiation, 20% had left sided radiation and 10% had bilateral radiation. After 4 weeks, most of the study population was significantly improved regarding Visual Analogue Scale (VAS) score in lumbar pain and radiation pain, tenderness over lumbar spine, Straight Leg Raising (SLR) test and improvement of mean difference  $\pm$  Standard Deviation (SD) after 4 weeks were  $4.25 \pm 3.12$ ,  $4.58 \pm 1.58$ ,  $1.7 \pm 0.92$  and  $29.5 \pm 16.15$  accordingly. Functional improvement of Oswestry Disability Index (ODI) from baseline  $39.60 \pm 7.11$  to  $15.67 \pm 0.96$ . Mean difference of all variables were statistically significant. **Conclusion:** Ultrasound is an effective tool, not only to guide the insertion of the needle into the caudal epidural space, but also to predict the procedural success rate.

**Keywords:** Ultrasound, Caudal, Epidural steroid, PLID

**Date of received:** 13.02.2020.

**KYAMC Journal. 2020;11(2): 67-72.**

**Date of acceptance:** 15.05.2020.

**DOI:** <https://doi.org/10.3329/kyamcj.v11i2.48417>.

### Introduction

Chronic low back pain arising from various structures of the spine constitutes the majority of the pain problems in the United States and across the world.<sup>1-8</sup> With the increasing prevalence of chronic persistent low back pain, numerous modalities of treatments applied to manage chronic low back pain are also exploding.<sup>9,10,11</sup> In the United States, epidural injections are one of the most commonly utilized modalities of treatment in managing chronic low back pain and lower extremity pain, in addition to numerous other modalities

including surgical interventions.<sup>12,13</sup> Epidural injections are administered by accessing the lumbar epidural space by multiple routes including caudal, transforaminal and interlaminar. While significant differences have been described between these 3 approaches, with the caudal approach, multiple advantages include being target specific for a lower levels, thus reaching the primary site of pathology, its ability to reach the ventrolateral epidural space in a significant proportion of patients, and that it can be safely performed in cases of post surgery syndrome with hardware, etc.

1. Assistant Professor, Physical Medicine and Rehabilitation Department, Dhaka Medical College, Dhaka, Bangladesh.
2. Associate Professor and HOD Physical Medicine & Rehabilitation. TMSS Medical College & Hospital, Bogura, Bangladesh.
3. Professor, Rheumatology Department, Anower Khan Modern Medical College, Dhaka, Bangladesh.
4. Professor, Physical Medicine and Rehabilitation Department, Bangabandhu Sheikh Mujib Medical University, Dhaka, Bangladesh.
5. Managing Director, Popular Diagnostic Center, Dhanmondi-2, Dhaka, Bangladesh.
6. Associate Professor, Physical Medicine and Rehabilitation Department, Bangabandhu Sheikh Mujib Medical University, Dhaka, Bangladesh.
7. Assistant Professor, Physical Medicine and Rehabilitation Department, Bangabandhu Sheikh Mujib Medical University, Dhaka, Bangladesh.

**Correspondent:** Dr. Mohammad Moniruzzaman, Assistant Professor, Department of Physical Medicine and Rehabilitation, Medical College, Dhaka, Bangladesh. Email-dr\_mzaman38@yahoo.com, Mobile: 01715-298988

Caudal epidurals are considered as the safest and easiest, with minimal risk of inadvertent dural puncture, even though requiring relatively high volumes.<sup>1,14</sup> In the past, caudal epidural injections have been shown to be effective when compared to interlaminar epidural injections.<sup>1,14</sup> However, the recent literature has shown that while caudal epidural injections may not be superior to either interlaminar or transforaminal, they may provide equal effectiveness.<sup>1,14-18</sup> For the therapeutic caudal epidural steroid injections evaluated multiple studies utilizing Cochrane Musculoskeletal Review group criteria with criteria of short-term relief as less than 6 months and long-term relief for greater than 6 months, showing Level I evidence of short- and long-term relief in managing chronic and lower extremity pain secondary to lumbar disc herniation and/or radiculopathy. Multiple systematic reviews concluded that a caudal approach was the most effective for epidural injection of corticosteroids into the lumbar region. The efficacy of lumbar epidural steroid injections which also included all 3 approaches, showed good evidence for caudal epidural, however, inferior to transforaminal epidural injections.<sup>19-22</sup> The objective of this study was to determine the effects of ultrasono-guided caudal epidural steroid injections in acute and chronic low back pain due to prolapsed lumbar intervertebral disc (PLID), spinal stenosis and discogenic pain. The objectives also included the evaluation of short-term pain relief with improvement in functional status. The ABO system occurs as a result of polymorphism of complex carbohydrate structure of glycoprotein and glycolipid expressed at the surface of erythrocytes or other cells or present in secretions, as glycan units of mucin

## Materials and Methods

Thirty consecutive patients with acute and chronic low back pain with radiculopathy and without red flag sign where clinical diagnosis established by physical examination supported by Magnetic Resonance Imaging (MRI) were prospectively included in the study from 1<sup>st</sup> August, 2015 to 30<sup>th</sup> November, 2015 in Popular Medical College Hospital, Dhanmondi, Dhaka. All patients were referred or self-directed after failure to respond to conservative therapy or refusal or non-feasibility of surgical intervention. We included all the patients available during the recruitment period of three months. In Inclusion criteria were age of patients between 20 to 70 years with acute (<12 week) or chronic (>12 week) low back pain radiating to any side or both sides, previous history of taking any conservative treatment, patient having MRI images with contained lumbar disc prolapse, agree to enroll in this study. In exclusion criteria were age less than 20 and more than 70, progressive neurological deficit, uncontrolled diabetes, uncontrolled hypertension, pregnancy, past medical history of carcinoma, tuberculosis, osteoporosis, major trauma, uncontained lumbar disc prolapse, presence of bleeding disorder, local infection, previous treatment of surgery or Minimally Invasive Intervention Procedures like caudal or interlaminar or transforaminal epidural steroid injection. Data was collected by trained personal from a preformed questionnaire. Data was processed, edited and paired student-t test was done, analyzed by SPSS windows version 20, p value

<0.05 was considered statistically significant at 95% confidence Interval. Before conduction of the procedure, patient's medical and imaging records were carefully reviewed. Obtaining an informed consent, the procedure was performed with strict aseptic precautions and intra-procedural vital parameters were monitored. A high resolution ultrasound GE Healthcare Volusion E8 (USA) with 12mhz probe was used to detect tip of 22 gauge spinal needle real time placement (Fig-1). 10 cc was injected (80 mg methyl prednisolone: normal saline-1:4) was given through sacral hiatus after piercing sacrococcygeal ligament. When the Physiatrist was satisfied that the needle was penetrated through the sacral hiatus into sacral epidural space, another 7 MHz probe was placed between 2<sup>nd</sup> and 3<sup>rd</sup> lumbar vertebrae to observe the turbulence of the injected material was observed in the lumbar epidural space. (Fig-3) Patients were monitored for one hour in the Popular Medical College Hospital. Patients were followed up at 2<sup>nd</sup> day, 7<sup>th</sup> day, 14<sup>th</sup> day and 28<sup>th</sup> day. After Caudal epidural steroid, patient was advised to do absolute bed rest for one day then, gradual return to active life with maintaining Activities of Daily Living (ADL), Back muscle strengthening exercise.

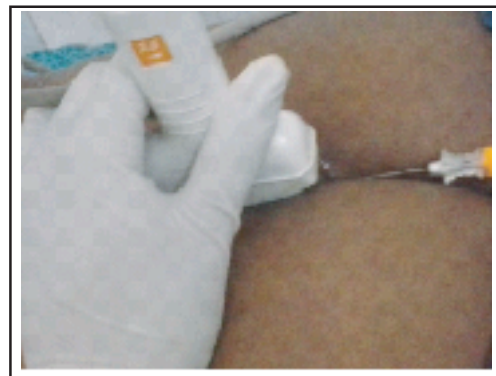

Figure 1: Caudal epidural needle Placement

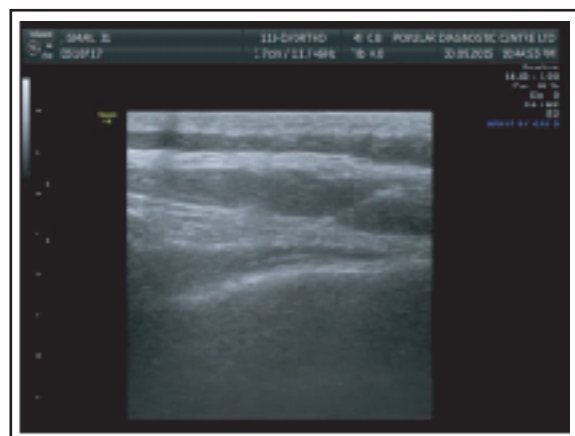

Figure 2: Caudal epidural needle advancement

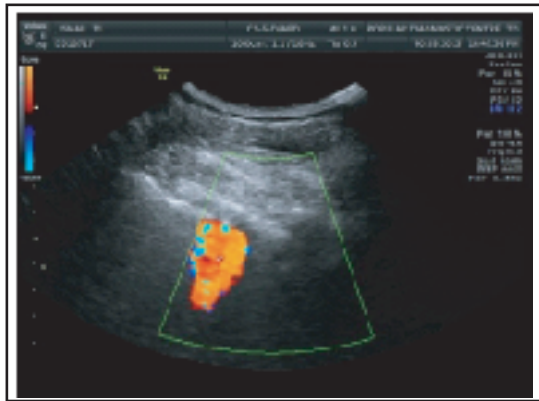

Figure 3: Turbulence of Injectate in color Doppler mode.

**Results**

The mean age was 40.83±13.34 (mean± SD). Male and female ratio was 3:2. Among male and female, businessman (20%) and housewife (30%) were highest accordingly. Regarding diagnosis, 56.66% were acute and 43.33% were chronic low back pain in which 40% had lumbar canal stenosis, 70% had right sided radiation, 20% had left sided radiation and 10% had bilateral radiation. 43.3% had muscle power 4/5 of Extensor Hallucis Longus (EHL) in radiation site. After 4 weeks, most of the study populations were significantly improved regarding Visual Analogue Scale (VAS) score in lumbar pain and radiation pain (Fig-4), tenderness over lumbar spine, Straight Leg Raising (SLR) test and improvement of mean difference± Standard Deviation (SD) after 4 weeks were 4.25±3.12, 4.58±1.58, 1.7±0.92 and 29.5±16.15 accordingly (Table-1). 90% of study population returned their muscle power of Extensor Hallucis Longus (EHL) 5/5 after 4 weeks. Functional improvement of Oswestry Disability index (ODI) from baseline 39.60±7.11 to 15.67±0.96 (Table-1). Mean difference of all variables were statistically significant. (P value <0.001)

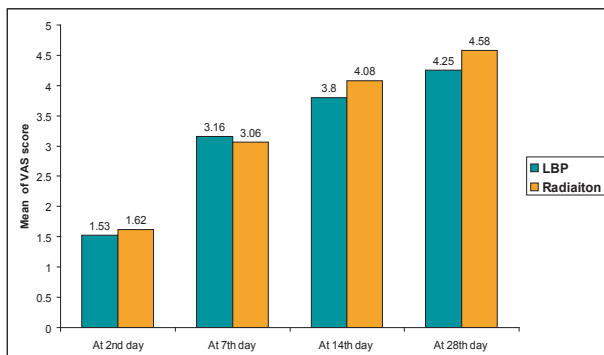


Figure-4: Improvement of low back pain and radiation at 2, 7, 14, 28 day (n=30)

Table-I: Improvement of tenderness, SLR and ODI at 2<sup>nd</sup>, 7<sup>th</sup>, 14<sup>th</sup>, 28<sup>th</sup> days (n=30)

Variable	Follow up visit	Mean difference	SD	P±value
Tenderness	At 2 <sup>nd</sup> day	0.73±0.74		<0.001*
	At 7 <sup>th</sup> day	0.7±3.79		.321
	At 14 <sup>th</sup> day	1.6±0.81		<0.001*
	At 28 <sup>th</sup> day	1.7±0.92		<0.001*
SLR test	At 2 <sup>nd</sup> day	10.83±10.43		<0.001*
	At 7 <sup>th</sup> day	22.33±13.11		<0.001*
	At 14 <sup>th</sup> day	26.33±16.23		<0.001*
	At 28 <sup>th</sup> day	29.5±16.15		<0.001*
ODI (baseline-39.60±7.11)	At 2 <sup>nd</sup> day	11.8± 4.26		<0.001*
	At 7 <sup>th</sup> day	17.17± 4.87		<0.001*
	At 14 <sup>th</sup> day	20.8± 5.71		<0.001*
	At 28 <sup>th</sup> day	23.93± 6.15		<0.001*

SD= Standard deviation, SLR= Straight leg raising test, ODI= Oswestry Disability Index, \* Statistically significant (p <0.05)

**Discussion**

The mean age was 40.83±13.34 (mean± SD). Male and female ratio was 3:2. A study in Iran showed that mean age of 65.4 ± 14.6 years (range, 36-90) which is higher than our study group probably due to higher life expectancy and different occupational status responsible for low back pain.<sup>23</sup> In another study, the mean age was 42.00±14.01 years.<sup>24</sup> Among male and female, businessman (20%) and housewife (30%) were highest accordingly. Most of the female were housewife and they had to do work in kitchen room with repeated squatting and also history of using low commode specially after low back pain. Regarding diagnosis, 56.66% were acute and 43.33% were chronic low back pain in which 40% had lumbar canal stenosis, 70% had right sided radiation, 20% had left sided radiation and 10% had bilateral radiation. In Mahshid Nikooseresht et al in Iran showed that 58.8% had spinal canal stenosis and Moniruzzaman M et al showed that 30% had lumbar canal stenosis due to disc prolapsed which very similar to this study. 43.3% had muscle power 4/5 of Extensor Hallucis Longus (EHL) in radiation site. 90% of study population returned their muscle power of EHL 5/5 after 4 weeks. After 4 weeks, study population were significantly improved regarding Visual Analogue Scale (VAS) score in lumbar pain and radiation pain (figure-1), tenderness over lumbar spine and Straight Leg Raising (SLR) test in terms of mean difference ± Standard Deviation (SD) were 4.25±3.12, 4.58±1.58, 1.7±0.92 and 29.5±16.15 respectively (Table-1). Functional improvement of Oswestry Disability Index (ODI) from baseline was 39.60±7.11 to 15.67±0.96 (Table-1) indicate that patients need endurance and fitness training for further improvement of ODI scores. Besides, ODI score-15.8±1.0 explained as minimum disability. ODI was used on a 0-5 point score to assess limitations of daily activities due to pain. The index includes: (1) pain intensity, (2) personal care

(washing, dressing), (3) lifting of weight, (4) walking, (5) sitting, (6) standing, (7) sleeping, (8) sex life (if applicable), (9) social life, (10) traveling. Mean difference of all variables were statistically significant (p value <0.001). A high resolution ultrasound GE Healthcare Volusion E8 (USA) with 12 MHz probe was used to detect tip of 22 gauge spinal needle real time placement. (Fig-1) An author used a high-frequency transducer (5-12 MHz) to identify the sacral hiatus.<sup>25</sup> With the patient in the prone position, the sacral hiatus is palpated, and a linear high-frequency transducer (curved low frequency transducer in obese patients) is placed transversely at the midline to obtain a sonographic transverse view of the sacral hiatus.<sup>26,27</sup> The 2 bony prominences of sacral cornua appear as 2 hyper echoic reversed U-shaped structures. Between the 2 cornua, one can identify 2 hyper echoic band-like structures: the sacrococcygeal ligament on top and the dorsal bony surface of the sacrum at the bottom and the sacral hiatus as the hypoechoic area in between. A 22-gauge needle is then inserted between the 2 cornua into the sacral hiatus. A 'pop' is usually felt as the sacrococcygeal ligament is penetrated. The transducer was then rotated 90 degrees to obtain a longitudinal view of the sacrum and sacral hiatus, and the needle is advanced into the sacral canal under real-time sonographic in the longitudinal view (Fig-2). In adults, it is usually difficult to follow the needle once in the sacral canal secondary to the bony artifacts from the sacrum wall. After negative aspiration for cerebrospinal fluid and blood, injection is carried out under real-time sonography, where one can notice turbulence in the sacral canal and monitor the spread of the injectate cephalad, which is not an easy task in adults. However, it is very subjective and unreliable because turbulence from the injectate (Fig-3) can be interpreted as flow in many directions with different colors and can be misinterpreted as intravascular injection. The best way to rule out unintentional intravascular or intrathecal injection is still by contrast fluoroscopy.<sup>28</sup> Complications related to caudal epidural injections are rare. In this study, no complication was seen. However, occasional complications may become worrisome. The common complications are related to either the needle placement or related to the drug activity. These include infection, either local or epidural, abscess, discitis; intravascular injection either intervenous or intraarterial with hematoma formation, spinal cord infarction; extra epidural placement with subcutaneous injection; subdural injection, dural puncture with post lumbar puncture headache, nerve damage, intracranial air injection or increased intracranial pressure; pulmonary embolism; and adverse effects of steroids.<sup>29</sup> Other much less common complications include transient blindness, retinal hemorrhage and necrosis, serous chorioretinopathy, persistent recurrent intractable hiccups, flushing, chemical meningitis, arachnoiditis, discitis, epidural hematoma, epidural abscess, and other complications. Other complications of corticosteroid administration include suppression of pituitary-adrenal axis, hypercorticism, Cushing's syndrome, osteoporosis, avascular necrosis of bone, steroid myopathy, epidural lipomatosis, weight gain, fluid retention, and hyperglycemia.<sup>30-46</sup> Limitations of US in

neuroaxial applications are discussed earlier, and the authors feel that neuroaxial (intrathecal and spinal) applications of US should be limited to regional anesthesia and obstetric anesthesia practice where fluoroscopy is not readily available. Until we have better technology, US should have no role in neuroaxial (intrathecal, epidural) blocks in chronic pain practice as fluoroscopy (which is superior) is readily available.<sup>28</sup>

## Conclusion

Ultrasound provides direct visualization of various soft tissues and bony surfaces, guiding real-time needle advancement, confirming the spread of injectate around the target and avoids exposing both the health care provider and the patient to the risks of radiation. This method may be a good alternative to the current standard of fluoroscopic guidance and bring a new hope for Interventional Physiatrist. Patients with lumbosacral radiculopathy due to disc prolapsed, caudal epidural steroid injection would be treatment of choice not only after failure of conservative treatment but also boost up of management of acute and chronic Low Back Pain with radiation. Further large scale study is needed for assessment of efficacy of sono guided caudal epidural injections in PLID.

## Acknowledgement

We are deeply grateful to the Popular Medical College and Hospital where doctors, Physiotherapist and staff continuously providing services to patients. We are also grateful to our study patients for their confidence in us.

## References

1. Manchikanti L, Boswell MV, Singh V, Benyamin RM, Fellows B, Abdi Set al. Comprehensive evidence-based guidelines for interventional techniques in the management of chronic spinal pain. *Pain Physician* 2009; 12: 699-802.
2. Cassidy JD, Carroll LJ, Coté P. The Saskatchewan Health and Back Pain Survey. The prevalence of low back pain and related disability in Saskatchewan Adults. *Spine (Phila Pa 1976)* 1998; 23: 1860-1867.
3. Verhaak PF, Kerssens JJ, Dekker J, SorbiMJ, Bensing JM. Prevalence of chronic benign pain disorder among adults: A review of the literature. *Pain* 1998; 77: 231-239.
4. GurejeO, Von Korff M, Simon GE, GaterR. Persistent pain and well-being: A World Health Organization study in primary care. *JAMA* 1998; 280: 147-151.
5. Elliott AM, Smith BH, Hannaford PC, Smith WC, Chambers WA. The course of chronic pain in the community: Results of a 4-year follow-up study. *Pain* 2002; 99:299-307.

6. Freburger JK, Holmes GM, Agans RP, Jackman AM, Darter JD, Wallace AS et al. The rising prevalence of chronic low back pain. *Arch Intern Med* 2009; 169:251-258.
7. Bressler HB, Keyes WJ, Rochon PA, Badley E. The prevalence of low back pain in the elderly. A systematic review of the literature. *Spine (Phila Pa 1976)* 1999; 24: 1813-1819.
8. Cecchi F, Debolini P, Lova RM, Macchi C, Bandinelli S, Bartali B et al. Epidemiology of back pain in a representative cohort of Italian persons 65 years of age and older: The In CHIANTI study. *Spine (Phila Pa 1976)* 2006; 31:1149-1155.
9. Luo X, Pietrobon R, Sun SX, Liu GG, Hey L. Estimates and patterns of direct health care expenditures among individuals with back pain in the United States. *Spine (Phila Pa 1976)* 2004; 29:79-86.
10. Walker BF, Muller R, Grant WD. Low back pain in Australian adults: The economic burden. *Asia Pac J Public Health* 2003; 15:79-87.
11. Deyo RA, Mirza SK, Turner JA, Martin BI. Over treating chronic back pain: Time to back off? *J Am Board Fam Med* 2009; 22:62-68.
12. Staal JB, de Bie RA, de Vet HC, Hildebrandt J, Nelemans P. Injection therapy for subacute and chronic low back pain: An updated Cochrane review. *Spine (Phila Pa 1976)* 2009; 34:49-59.
13. Rubinstein SM, van Middelkoop M, AssendelftWJ, de Boer MR, van Tulder MW. Spinal manipulative therapy for chronic low-back pain: An update of a Cochrane review. *Spine (Phila Pa 1976)* 2011; 36: E825-E846.
14. Conn A, Buenaventura R, Datta S, Abdi S, Diwan S. Systematic review of caudal epidural injections in the management of chronic low back pain. *Pain Physician* 2009; 12:109-135.
15. Bogduk N, Christophidis N, Cherry D. Epidural use of steroids in the management of back pain. Report of working party on epidural use of steroids in the management of back pain. National Health and Medical Research Council, Canberra, Commonwealth of Australia, 1994; 1-76.
16. Manchikanti L, Datta S, Derby R, Wolfer LR, Benyamin RM, Hirsch JA. A critical review of the American Pain Society clinical practice guidelines for interventional techniques: Part 1. Diagnostic interventions. *Pain Physician* 2010; 13: E141- E174.
17. Manchikanti L, Datta S, Gupta S, Munglani R, Bryce DA, Ward SP et al. A critical review of the American Pain Society clinical practice guidelines for interventional techniques: Part 2. Therapeutic interventions. *Pain Physician* 2010; 13:E215-E264.
18. Manchikanti L, Pakanati RR, Pampati V. Comparison of three routes of epidural steroid injections in low back pain. *Pain Digest* 1999; 9:277-285.
19. Peterson C, Hodler J. Evidence-based radiology (part 1): Is there sufficient research to support the use of therapeutic injections for the spine and sacroiliac joints? *Skeletal Radiol* 2010; 39:5-9.
20. Parr AT, Diwan S, Abdi S. Lumbar interlaminar epidural injections in managing chronic low back and lower extremity pain: A systematic review. *Pain Physician* 2009; 12:163-188.
21. Buenaventura RM, Datta S, Abdi S, Smith HS. Systematic review of therapeutic lumbar transforaminal epidural steroid injections. *Pain Physician* 2009; 12: 233-251.
22. Rho ME, Tang CT. The efficacy of lumbar epidural steroid injections: Transforaminal, interlaminar, and caudal approaches. *Phys Med Rehabil Clin N Am* 2011; 22:139-148.
23. Nikooseresht M, Hashemi M, Mohajerani SA, Shahandeh F, Agah M. Ultrasound as a Screening Tool for Performing Caudal Epidural Injections. *Iran J Radiol.* 2014; 11(2): 3262.
24. Moniruzzaman M, Hossain MS, Amin MR, Khasru MR, Rahman MA, Khandaker MN, Uddin MT, Akhtaruzzaman AKM. Efficacy Of Intradiscal Ozon Gas Therapy Combined With Physical Therapy In Contained Lumbar Disc Prolapse. *Bangladesh Med J.* 2015; 44(3):146-151.
25. Chen CP, Tang SF, Hsu TC, et al. Ultrasound guidance in caudal epidural needle placement. *Anesthesiology.* 2004; 101:181-184.
26. Klocke R, Jenkinson T, Glew D. Sonographically guided caudal epidural steroid injections. *J Ultrasound Med.* 2003; 22:1229-1232.
27. Chen CP, Tang SF, Hsu TC, et al. Ultrasound guidance in caudal epidural needle placement. *Anesthesiology.* 2004; 101:181-184.
28. Narouze S, Peng P. Ultrasound-Guided Interventional Procedures in Pain Medicine: A Review of Anatomy, Sonoanatomy, and Procedures. Part II: Axial Structures. *Regional Anesthesia and Pain Medicine.* 2010; 35(4):386-396.

29. Parr AT, Manchikanti L, Hameed H, Conn A, Manchikanti KN, Benyamin RM et al. Caudal Epidural Injections in the Management of Chronic Low Back Pain: A Systematic Appraisal of the Literature. *Pain Physician* 2012; 15:E159-E198.
30. Young WF. Transient blindness after lumbar epidural steroid injection: A case report and literature review. *Spine (PhilaPa 1976)* 2002; 27 (21) 476-477.
31. Browning DJ. Acute retinal necrosis following epidural steroid injections. *Am JO phthalmol* 2003; 136:192-194.
32. Kusher FH, Olson JC. Retinal hemorrhage as a consequence of epidural steroid injection. *Arch Ophthalmol* 1995; 113:309-313.
33. Iida T, Spaide RF, Negrao SG, Carvalho CA, Yannuzzi LA. Central serous chorioretinopathy after epidural corticosteroid injection. *Am J Ophthalmol* 2001; 132:423-425.
34. Pizzimenti JJ, Daniel KP. Central serous chorioretinopathy after epidural steroids. *Pharmacotherapy* 2005; 25:1141-1146.
35. McAllister RK, McDavid AJ, Meyer TA, Bittenbinder TM. Recurrent persistent hiccups after epidural steroid injection and analgesia with bupivacaine. *AnesthAnalg* 2005; 100:1834-1836.
36. Everett CR, Baskin MN, Novoseletsky D, Speach D, Patel R. Flushing as a side effect following lumbar transforaminal epidural steroid injection. *Pain Physician* 2004; 7:427-429.
37. Kim CH, Issa MA, Vaglianti RM. Flushing following interlaminar lumbar epidural steroid injection with dexamethasone. *Pain Physician* 2010; 13:481-484.
38. Gutknecht DR. Chemical meningitis following epidural injections of corticosteroids (Letter). *Am J Med* 1987; 82:570.
39. Nelson DA, Landau WM. Intraspinal steroids: History, efficacy, accidentality, and controversy with review of United States Food and Drug Administration reports. *J Neurol Neurosurg Psychiatry* 2001; 70:433-443.
40. Yue WM, Tan SB. Distant skip level discitis and vertebral osteomyelitis after caudal epidural injection: A case report of a rare complication of epidural injections. *Spine (Phila Pa 1976)* 2003; 28:E209-E211.
41. Kabbara A, Rosenberg SK, Untal C. Methicillin-resistant staphylococcus aureus epidural abscess after transforaminal epidural steroid injection. *Pain Physician* 2004; 7:269-272.
42. Hooten WM, Kinney MO, Huntoon MA. Epidural abscess and meningitis after epidural corticosteroid injection. *MayoClinProc* 2004; 79:682-686.
43. Hughes JM, Hichens M, Booze GW, Thorner MO. Cushing's syndromes from therapeutic use of intramuscular dexamethasone acetate. *Arch Intern Med* 1986; 146:1848-1849.
44. Boonen S, Van Distel G, Westhovens R, Dequeker J. Steroid myopathy induced by epidural triamcinolone injection. *Brit J Rheumatol* 1995; 34:385.
45. Sandberg DI, Lavyne MH. Symptomatic spinal epidural lipomatosis after local epidural corticosteroid injections: Case report. *Neurosurgery* 1999; 45:162-165.
46. Manchikanti L, Singh V. Corticosteroids. In: Manchikanti L, Christo PJ, TrescotAM, Falco FJE (eds). *Foundations of PainMedicine and Interventional Pain Management:A Comprehensive Review*. ASIPP Publishing, Paducah, KY, 2011, 589- 606.