

## Case Report



# Chemotherapy Induced Radiation Recall Injury

Aditi Paul Chowdhury<sup>1</sup>, Md. Ershadul Haque<sup>2</sup>, Md. Nazmul Alam<sup>3</sup>,  
Tanvir Ahmed<sup>4</sup>, Barun Kumar Das<sup>5</sup>, M.A. Bari<sup>6</sup>, Md. Shahidul Islam<sup>7</sup>.

### Abstract

Radiation recall is characterized by an acute inflammatory reaction confined to previously irradiated areas that is triggered by the administration of precipitating systemic agents after radiation treatment. The most common responsible drugs are anticancer agents, but other drugs can also cause radiation recall including some antibiotics, antitubercular drugs, simvastatin can also cause radiation recall phenomenon. We report a case of paclitaxel induced radiation recall injury in a 57 year old male with carcinoma left lung with brain metastases.

**Key words:** Brain Metastasis, Carcinoma Lung, Paclitaxel, Radiation Recall Injury.

**Date of received:** 01.30.2020.

**Date of acceptance:** 20.08.2020.

**DOI:** <https://doi.org/10.3329/kyamcj.v11i3.49876>

**KYAMC Journal.2020;11(3):158-160.**

### Introduction

Treatment of cancer includes both chemotherapy and radiotherapy. But giving radiotherapy after chemotherapy can induce radiation recall injury. Several cases of radiation recall injury is reported in a duration of days to several months. It is characterized by an acute inflammatory reaction, confined to areas previously irradiated, and usually triggered by the administration of certain drugs or sun exposure.<sup>1</sup> It is important to understand the difference between Radiation Recall Dermatitis (RRD) and radiosensitization. Radiosensitization is the effect of the radiation is enhanced during or few days after treatment with radiation therapy. In RRD the phenomenon can occur many days after the treatment has been completed without any direct effects of radiation corresponding more to an idiosyncratic reaction.<sup>1</sup> There is a period of enhanced sensitivity in the days after irradiation, when reaction to systematically administer drugs is common. When the time interval between end of radiation and chemotherapy is <7 days, such reactions can be considered radiation enhancement or sensitization.<sup>1</sup> A short interval between the end of radiation therapy and the beginning of chemotherapy is a known risk

factor to develop the condition. It is unlikely that the cytotoxic properties of chemotherapeutic agents by themselves are responsible for the phenomenon since it has an unpredictable response and in many cases the re-exposure to the drug does not produce symptom recurrence.<sup>2</sup> Clinically, the majority of cases manifest as an acute cutaneous inflammatory reaction (dermatitis) with erythema, maculopapular or vesicular lesions, and pain followed by dry desquamation in the affected area. However, in the most severe cases might be persistent painful vesicles and necrosis. In one third of cases, there is involvement of other structures besides the skin with reports describing cases of pneumonitis, myositis or enteritis.<sup>10-13</sup>

### Case Report

The patient is a 57 years old, male diagnosed case of Carcinoma Left Lung with Brain metastases. Patient was presented to emergency department with multiple ulcerated lesion over scalp, neck and back for 3 days (figure 1, 3 and 4), generalized weakness for same duration and altered orientation for 1 day. According to patient's attendant, skin lesions

1. Resident, Department of Oncology, Khwaja Yunus Ali Medical College, Enayetpur, Sirajganj, Bangladesh.
2. Resident, Department of Oncology, Khwaja Yunus Ali Medical College, Enayetpur, Sirajganj, Bangladesh.
3. Assistant Professor, Department of Oncology, Khwaja Yunus Ali Medical College, Enayetpur, Sirajganj, Bangladesh.
4. Assistant Professor, Department of Oncology, Khwaja Yunus Ali Medical College, Enayetpur, Sirajganj, Bangladesh.
5. Assistant Professor, Department of Oncology, Khwaja Yunus Ali Medical College, Enayetpur, Sirajganj, Bangladesh.
6. Associate Professor, Department of Oncology, Bangabandhu Sheikh Mujib Medical University, Dhaka, Bangladesh.
7. Professor, Department of Oncology, Khwaja Yunus Ali Medical College, Enayetpur, Sirajganj, Bangladesh.

**Correspondence:** Dr. Aditi Paul Chowdhury, Resident, Department of Oncology, Khwaja Yunus Ali Medical College, Enayetpur, Sirajganj, Bangladesh. E mail: draditi1243@gmail.com, Phone: 01746295483.

appeared 1 day after chemotherapy and was gradually increasing in size day by day. He was diagnosed as a case of Adenocarcinoma of Left Lung with brain metastases on 21 August, 2019. He was staged as stage IVB, EGFR mutation study was negative. He received WBRT to Brain and Chest 30 Gray 10 fractions from 26 August 2019 to 6 September 2019. Patient was treated with 6 MV photon. For whole Brain two lateral opposed beams were used each containing 15 Gray. For Chest filed A/P and P/A beams were used (figure 2). A/P beam contained 16 Gray, P/A contained 14 Gy. After completion of radiotherapy he was planned for palliative chemotherapy with Paclitaxel and Cisplatin regimen. Patient received first cycle of chemotherapy with Paclitaxel 250 mg and Cisplatin 100 mg on 17 September 2019. He has no history of DM, HTN or any other comorbidity. On general physical examination HR 98 beats/min, BP 100/70 mm of Hg, SpO2 96% without oxygen, RR- 18 breaths/min. Height: 159 cm, Weight- 42 kg, BSA- 1.36 m<sup>2</sup>, ECOG-3. Not anemic, non-icteric, temperature- 101<sup>0</sup> F, no lymphadenopathy. There were multiple erythematous moist desquamation over scalp, neck and back, oral cavity- grade II oral mucositis, Tongue was normal, breath sound diminished over left upper lung field, no added sound. Other systemic examination revealed no abnormality. On baseline investigations, he had hyponatremia and mass lesion at left upper lung field on chest radiograph. He was treated accordingly with injectable antibiotics and steroid. Electrolyte imbalance was corrected. Patient was gradually improving and finally he was discharged after 7 days (figure 5 and 6)

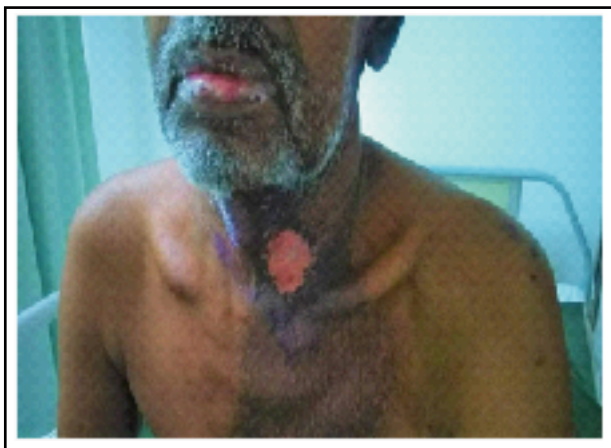

Figure 1: skin lesion over anterior neck

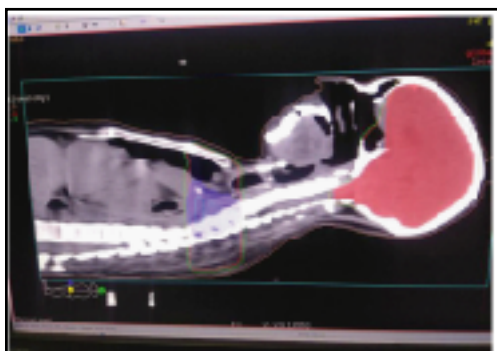


Figure 2: Radiotherapy planning same patient

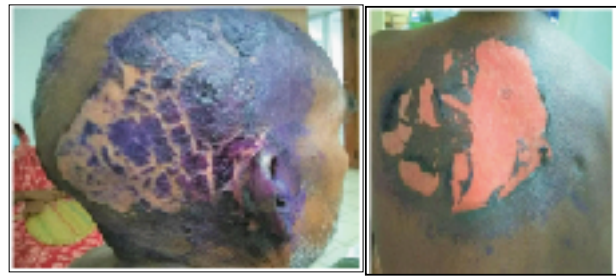

Figure 3 & 4: skin lesion over Scalp and back.



Figure 5 & 6: skin lesion over Scalp & back after treatment

### Discussion

The first case of radiation recall dermatitis was reported in 1959 by D'Angio et al. who noticed the reaction following treatment with Dactinomycin.<sup>3</sup> The time interval between the completion of radiation therapy and the administration of cytotoxic chemotherapy was between 6 days to several months in patients in whom radiation recall developed. It has been suggested that this mechanism could be mediated by continued low-level secretion of the inflammation-mediating cytokines induced by radiation.<sup>4</sup> This is the interaction of basal layers of the irradiated skin with cytotoxic agents secreted from dead cells due to chemotherapy. The presence of a precipitating chemotherapy agent may then unregulated these cytokines, resulting in a radiation recall reaction. The drugs for which radiation recall reactions have been most commonly reported include the anthracycline Doxorubicin, the taxanes-Docetaxel and Paclitaxel, and the antimetabolites Gemcitabine and Capecitabine. Radiation recall has also been reported with newer agents used in the treatment of various cancers including Pemetrexed, Gefitinib, Trastuzumab in combination with Vinorelbine, and Bevacizumab in combination with Gemcitabine.

Although often occurring shortly after the first dose of chemotherapy, radiation recall can also manifest after multiple courses of chemotherapy have been administered. There is no evidence to suggest that combination chemotherapy either increases or decreases the risk of radiation recall compared with monotherapy. Radiation reactions tend to be more severe when there is a shorter time interval between radiation and exposure to the precipitating agents. It is not clear whether radiation recall reactions occur more commonly when high-dose radiotherapy with lower energy photon beams is applied. Radiation recall is usually diagnosed through evaluation of treatment history, symptoms, and physical examination. The precipitating agent should be delayed or withdrawn to allow the skin to heal. It is very rare for radiation recall reactions to resolve whereas treatment with the implicated drug is

continued.<sup>5</sup> Topical or systemic Corticosteroids or Nonsteroidal anti-inflammatory drugs are sometimes used to reduce inflammation. Antihistamines can also be used for symptomatic relief. Reactions often resolve within days or 1 to 2 weeks although sometimes reactions to intravenous drugs may improve within hours, resolution may take over a month for some oral drug.

### Conclusion

There is still much that needs to be understood about radiation recall, and it is not currently possible to predict which patients will be affected and which drugs they will react to. Furthermore, there are no identifiable characteristics of drugs that cause radiation recall, and thus, it is a possibility that must be kept in mind with use of any drug after radiotherapy, including those from new drug classes. Although it is not yet possible to design treatment regimens to eliminate the risk of radiation recall, it seems likely that risks can be minimized by using the lowest possible dose of radiation and prolonging the interval between completion of radiotherapy and initiation of chemotherapy.

### Acknowledgement

We would like to give thanks the doctors and medical staff of the department of Oncology, Khwaja Yunus Ali Medical College & Hospital for their valuable support. Special thanks to authority who allowed us to permission for publication.

### References

1. Azria D, Magne N, Zouhair A, et al. Radiation recall: a well-recognized but neglected phenomenon. *Cancer Treat Rev.* 2005; 31:555-570.
2. Schweitzer VG, Juillard GJ, Bajada CL et al (1995) Radiation recall dermatitis and pneumonitis in a patient treated with paclitaxel. *Cancer* 76:1069-1072.
3. D'Angio GJ, Farber S, Maddock CL. Potentiation of x-ray effects by actinomycin D. *Radiology.* 1959; 73:175-177.
4. Caloglu M, Yurut-Caloglu V, Cosar-Alas R, et al. An ambiguous phenomenon of radiation and drugs: recall reactions. *Onkologie.* 2007; 30:209-214.
5. Yeo W, Johnson PJ. Radiation-recall skin disorders associated with the use of antineoplastic drugs. Pathogenesis, prevalence, and management. *Am J ClinDermatol.* 2000; 1:113-116.