

Original Article



Impact of Corticosteroid Injection on The de Quervain's Tenosynovitis

Taufiq Morshed¹, Mohammed Emran², Md. Israt Hasan³,
Md. Zahid Ferdous⁴, Dibakar Sarkar⁵, ATM Zulfiqur Rahman⁶

Abstract

Background: de Quervain's tenosynovitis may be caused by thickened extensor retinaculum which holds the tendon in position in wrist. There are both operative and non-operative treatments for the condition. Corticosteroid injection is a very good conservative treatment option. **Objective:** To see the outcome of corticosteroid Injection in the de Quervain's Tenosynovitis. **Materials and Methods:** This was prospective interventional study conducted at the outpatient department of Kurmitola General Hospital during the period from January 2018 to December 2019. Total 71 patients with de Quervain's tenosynovitis were analyzed. Secondary outcomes were measured by Visual Analogue Scale (VAS) and Quick Disabilities of Arm, Shoulder and Hand (DASH) score. **Results:** Among the 71 affected hands, 11 (16.22%) patients had recurred. Sixty (83.78%) patients had no positive sign or symptom after 6 months of follow-up. Average VAS before injection was 8.27 ± 1.23 . Post injection VAS was 0.82 ± 1.49 at 1 month follow-up and 1.46 ± 2.34 at 6 month follow-up which was improved significantly. Pre-injection average Quick DASH score was 77.33 ± 13.59 which was reduced to 18.34 ± 12.37 after 1 month and 22.97 ± 17.28 after 6 months of follow-up. **Conclusion:** Single injection of triamcinolone with local anesthetic for the treatment of de Quervain's disease was proved significant conservative treatment option though there were few complications and failed cases. We should pay more attention to long-term follow-up and proper injection technique.

Key words: de Quervain's tenosynovitis, Finkelstein's test, Triamcinolone acetonide, Visual Analogue Scale, Quick DASH score

Date of received: 15.11.2020

Date of acceptance: 20.05.2021

DOI: <https://doi.org/10.3329/kyamcj.v12i2.55441>

KYAMC Journal.2021;12(02): 88-91.

Introduction

De Quervain's tenosynovitis (DTS) is a tenosynovitis affecting the first dorsal component of the hand due to improper gliding of two tendons namely abductor pollicis longus and extensor pollicis brevis.¹ Fritz de Quervain first noticed this condition in 1895 with 5 case reports. He also reported another 8 cases in 1912.^{2,3}

De Quervain's tenosynovitis may be caused by thickened extensor retinaculum which holds the tendon in position in wrist. It is a fibrous band which is inserted to radius and limits

bowstring of the dorsal tendons at the hand. Though stenosing tenosynovitis is used for de Quervain's disease it is consistent with degeneration in microscopic appearance. It is myxoid and fibrocartilaginous type of degeneration where mucopolysaccharides accumulate.⁴ The prevalence of this disease in UK is around 0.5% in male and 1.3% in female.⁵

De Quervain's tenosynovitis is a work related musculoskeletal disorder.⁶ Risk factors are repetitive and forceful labor with wrist in ulnar deviation and thumb is abducted and extended.⁷ The differential diagnosis of this disease are osteoarthritis affecting 1st CMC joint, ganglion, infection Wartenberg's dis

1. Junior Consultant, Department of Orthopaedic Surgery, Kurmitola General Hospital, Dhaka, Bangladesh.
2. Assistant Professor, Department of Physical Medicine and Rehabilitation, Khwaja Yunus Ali Medical College and Hospital, Enayrtpur, Sirajganj, Bangladesh.
3. Medical Officer, Department of Physical Medicine and Rehabilitation, Kurmitola General Hospital, Dhaka, Bangladesh.
4. Assistant Professor, Department of Orthopaedic Surgery, Kurmitola General Hospital, Dhaka, Bangladesh.
5. Consultant, Department of Orthopaedic Surgery, National Institute of Traumatology and Orthopaedic Rehabilitation (NITOR), Dhaka, Bangladesh.
6. Assistant Professor, Department of Orthopaedic Surgery, Bangladesh Medical College, Dhaka, Bangladesh.

Correspondence: Dr. Taufiq Morshed, Junior Consultant, Department of Orthopaedic Surgery, Kurmitola General Hospital, Dhaka, Bangladesh. Email: taufiqmorshed@gmail.com, Mobile: 01911020858.

esese, intersection disease etc.⁸ The disease can be diagnosed by taking proper history and clinical examination. Symptoms are pain and tenderness over radial styloid process that may radiate to thumb, forearm or shoulder. On examination, there may be swelling, tenderness and crepitation on palpation. Finkelstein's test may be positive.⁹ The Finkelstein's test is done by clenching the fist with the thumb inside and try to deviate the wrist ulnarward. Pain felt by patient at wrist in case of de Quervain's disease.¹⁰

There are both operative and non-operative treatments for the condition. Non-operative treatment options are rest, application of ice, NSAIDs, exercise and splinting.¹¹ Corticosteroid injection is the next modality. Other options are acupuncture, ozone therapy, hyaluronic acid injection, USG guided percutaneous needle tenotomy, PRP injection, prolotherapy, etc.¹²⁻¹⁵ Surgery is done if above treatment modalities failed and is done by releasing of the first dorsal compartment.

The exact mechanism of corticosteroid injection remain unclear, but the anti-inflammatory property may help to subside the symptoms. A Cochrane review showed that methylprednisolone injection improved the condition faster than other non-operative treatment options.¹⁶ There may be some complications of corticosteroid injection such as post-injection flare, injection depigmentation, loss of subcutaneous fat and tendon rupture.¹⁷ The another systemic review showed cure rate with corticosteroid injection alone was about 83%.¹⁸

Materials and Methods

This was prospective interventional study conducted at the outpatient department of Kurmitola General Hospital during the period from January 2018 to December 2019. Registration of 77 patients of de Quervain's tenosynovitis were done for this study. Three patients lost on follow-up. Among the rest 74 patients 3 had bilateral de Quervain's disease. So, out of 74 patients we included total 71 hands of de Quervain's tenosynovitis and analyzed.

For the study patients were recruited according to following criteria.

Inclusion criteria:

- Pain around the radial styloid process
- Tenderness on first dorsal compartment of wrist
- Finkelstein's sign positive
- Oral medication failed to improve the condition

Exclusion criteria:

- Age below 18 years
- Presence of other diseases like rheumatoid arthritis, gout, diabetes mellitus
- Pregnancy
- History of trauma
- Previous history of local steroid injection
- Symptoms related to radiculopathy and carpal tunnel syndrome
- Sensitive to lidocaine or corticosteroid injection
- Presence of infection or local skin lesion

All the patients were observed for primary and secondary outcomes before injection, at 1 month and at 6 month. The primary outcomes were measured by presence or absence of pain around radial side of wrist, tenderness and Finkelstein test. Successful treatment was considered when all three criteria were negative. Pain was assessed by Visual Analogue Scale (VAS) score and counted negative when score is below 4. Secondary outcomes were measured by VAS and Quick DASH. They were compared with pre injection, at 1 month and 6 month follow-up. Demographic data such as age, sex, occupation, dominant & affected hand were recorded. Occupations were classified as housewife, forceful hard worker, occupation requiring less demanding hand work and unemployed.

Injection technique:

A mixture of one ml triamcinolone acetonide and one ml 2% lignocaine was taken in a 3 cc disposable syringe with 24 or 26 gauge needle. Lidocaine is added to prevent immediate pain following triamcinolone injection. Under aseptic precaution the site of maximum tenderness was noted and needle was passed in the 1st extensor compartment of hand directing towards the radial styloid parallel to the two tendons. Stretching of the synovial sheath by volume effect was observed.

After taking ethical committee approval, the study was done in accordance with the ethical standards of Helsinki. All the registered patients were briefed about the possible outcomes and side effects. Then written informed consent was taken prior to enrollment.

Results

Out of 71 patients of de Quervain's tenosynovitis 58 (81.7%) were female and 13 (18.3%) were male (Figure 1). Mean age was 46.59±11.99 years. Majority (42.3%) of the patients were housewives. Forceful workers were 17 (23.9%), peoples in less demanding profession were 14 (19.7%) and the rest 14.1% were unemployed. Among 71 patients, right hand was dominant in 66 (93%) patients and left hand in 5 (7%) patients. Out of 71 diseased hands, 74.32% patient had de Quervain's tenosynovitis in dominant hand whereas 25.68% had in non-dominant hand.

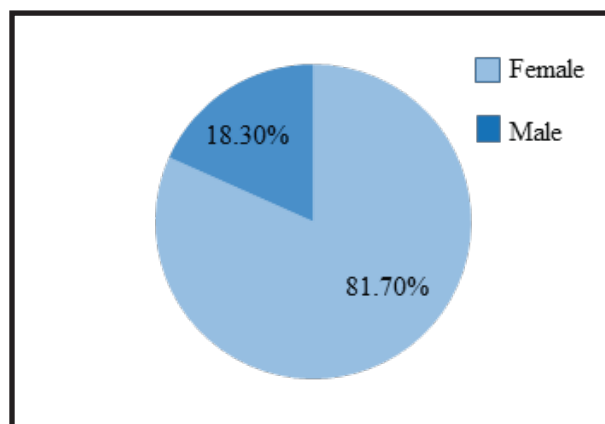


Figure: 1

Among 71 affected hands, 11 (16.22%) patients had recurred diagnosed with positive Finkelstein’s test or VAS more than 3. Sixty (83.78%) patients had no positive sign or symptom after 6 months of follow-up. Immediate pain after the injection were noticed in 7 patients which were relieved with simple analgesics. Superficial infections were occurred in 2 patients that resolved within 2 weeks with antibiotic. De-pigmentation occurred in 9 patients. No other complications were noticed.

Average Visual Analogue Scale before injection was 8.27±1.23. Post injection VAS was 0.82±1.49 at 1 month follow-up and 1.46±2.34 at 6 month follow-up which was improved significantly. Pre-injection average Quick DASH score was 77.33±13.59 which was reduced to 18.34±12.37 after 1 month and 22.97±17.28 after 6 months of follow-up (Table I).

Table I: Secondary Outcomes

	Pre injection		At 1 month		At 6 month	
	Mean	SD	Mean	SD	Mean	SD
VAS	8.27	1.23	0.82	1.49	1.46	2.34
DASH	77.33	13.59	18.34	12.37	22.97	17.28

Discussion

In our study, single injection of triamcinolone and lignocaine mixture has made an improvement of 83.78% patients with significant improvement of pain and negative Finkelstein’s test. However 16.22% patients did not improve after 6 months of follow-up. The functional outcomes measured by VAS score and Quick DASH score had improved significantly.

Peters-Veluthamaningal , et al. showed 87.5% success rate in the treatment of DTS with steroid injection. VAS score was also reduced from 8.65±1.07 to 1.03±1.26 after 1 year of follow-up.¹⁸ Many other studies were very much similar to this one.¹⁹⁻²² Richie & Eriner reported 83% success with corticosteroid injection for DTS in systematic review of seven papers.²³ Kittu , et al. reported 67% success rate with single injection of triamcinolone acetonide in the treatment of DTS.²⁴ Anderson , et al. showed 90% success treated with 1-2 methyl prednisolone injection after 4 years of follow-up.²⁵

In our study Single injection of triamcinolone with local anesthetic for de Quervain’s tenosynovitis in 71 hands was proved significant conservative treatment option. However, follow-up time was only 6 months and there were failed cases and few complications such as pain, infection and depigmentation.

There is demand of many comparative studies among the different modalities of treatment for de Quervain’s tenosynovitis. Moreover, as it is a work related musculoskeletal disorder and, repetitive and forceful labor with the wrist are the proven risk factors so the working technique with the wrist should be modified along with all the treatment modalities.

Conclusion

The triamcinolone injection is a good non-operative treatment for the de Quervain’s tenosynovitis. We should pay more attention to long-term follow-up and proper injection technique.

Acknowledgement

We are very much grateful to our authority to give permission conducting the study and thankful to the participants.

References

1. Moore J. De Quervain's tenosynovitis. Stenosing tenosynovitis of the first dorsal Compartment. J Occup Environ Me.1997; 39: 990-1002.
2. de Quervain F.On the nature and treatment of stenosing tendovaginitis on the styloid process of the radius. (Translated article: Muenchener Medizinische Wochenschrift 1912,59, 5-6). J Hand Surg Br.2005;30(4):392-394.
3. de Quervain F.On a form of chronic tendovaginitis. (Translated article: Cor Bl.f.schweiz. Aerzrte 1895:25:389-94).J Hand Surg Br.2005;30(4):388-391.
4. Clarke M, Lyall H, Grant J, Mathewson M.The histopathology of de Quervain's Disease.Hand Surg [Br].1998;23:732-773.
5. Walker-Bone K, Palmer K, Reading I, Coggon D, Cooper C. Prevalence and impact of musculoskeletal disorders of the upperlimb in the general population. Arthritis Rheum. 2004;51:64251.
6. Sluiter J, Rest K, Frings-Dresen M. Criteria document for evaluating the work relatedness of upper-extremity musculoskeletal disorders. Scand J Work Environ Health.2001;27(1):100-102.
7. Schned E. DeQuervain tenosynovitis in pregnant and postpartum women.Obstetrics Gynecol. 1986;68(3): 411-414.
8. Shiraj S, Winalski C, Delzell P, Sundaram M. Radiologic case study. Intersection syndrome of the wrist. Orthopedic.2013;36(3):225-227.
9. Palmer K, Walker-Bone K, Linaker C, Reading I, Kellingray S, Coggon D, Cooper C. The Southampton examination schedule for thediagnosis of musculoskeletal disorders of the upper limb. AnnRheum Dis.2000;59:5-11.
10. Rettig A. Wrist and hand overuse syndromes. Clin Sports Med.2001.20:591-611.
11. Ilyas A.Nonsurgical treatment for de Quervain's tenosynovitis. J Hand Surg. 2009; 34(5):928-929.
12. da Silva J and Batigália F. Acupuncture in De Quervain's disease: a treatment proposal. Acupunct Med.2014; 32(1):70-72.

13. Moretti M. Effectiveness of oxygen-ozone and hyaluronic acid injections in De Quervain's syndrome. *Int J Ozone Ther.*2012;11(1):31-33.
14. Peck E and Ely E. Successful treatment of de quervain tenosynovitis with ultrasound-guided percutaneous needle tenotomy and platelet-rich plasma injection: a case presentation. *PMR.*2013;5(5):438-441.
15. Tseng V, Ibrahim V and Yokel N. Prolotherapy for dequervain's tenosynovitis/tendonosis: a case report. *PM R.*2012; 4(10):275.
16. Peters-Veluthamaningal C, Winters JC, Groenier KH, Meyboom-deJong B. Randomised controlled trial of local corticosteroid injections for de Quervain's tenosynovitis in general practice. *BMC Musculoskeletal Disorders.*2009;10(131):1-8.
17. Cardone D and Tallia A. Joint and soft tissue injection. *Am Fam Physician.*2002; 66(2):283-288.
18. Peters-Veluthamaningal C, van der Windt D, Winters J, Meyboom-de JB. Corticosteroid injection for de Quervain's tenosynovitis. *Cochrane Database of Systematic Reviews.*2009;3:005616.
19. Pooswamy SS and Muralidharaogpalan NR. Intra sheath corticosteroid injection for De Quervain's tenosynovitis. *International Journal of Research in Orthopaedics.*2019;5(3): 403-407.
20. Ahmed GS, Tago IA and Makhdoom A. Outcome of Corticosteroid Injection in De Quervain's Tenosynovitis. *Journal of the Liaquat University of Medical and Health Sciences.*2013; 12(1):30-33.
21. Mardani-Kivi M, Mobarakeh MK, Bahrami F, Hashemi-Motlagh K, Saheb-Ekhtiari K , Akhoondzadeh N. Corticosteroid Injection With or Without Thumb Spica Cast for de Quervain Tenosynovitis. *J Hand Surg Am.*2014;39:37-41.
22. Rowland P, Phelan N, Gardiner S, Linton KN, Galvin R. The Effectiveness of Corticosteroid Injection for De Quervain's Stenosing Tenosynovitis (DQST): A Systematic Review and Meta-Analysis. *The Open Orthopaedics Journal.*2015;9:437-444.
23. Richie C and Eriner WJ. Corticosteroid injection for treatment of de Quervain's tenosynovitis: a pooled quantitative literature evaluation. *J Am Board Fam Pract.*2003; 16:102-106.
24. Kitti J, Sukit S, Kitiwan V, Surut JI. Treatment of De Quervain disease with triamcinolone injection with or without nimesulide. *J Bone Joint Surg Am.* 2004;86: 2700-2706.
25. Anderson B, Manthey R, Brouns M. Treatment of De Quervain's tenosynovitis with corticosteroids. A prospective study of the response to local injection. *Arthritis Rheum.*1991; 34:793-798.