

## Review Article



# Atypical Presentations of Appendicitis

ABM Moniruddin<sup>1</sup>, Salma Chowdhury<sup>2</sup>, Tanvirul Hasan<sup>3</sup>,

Baikaly Ferdous<sup>4</sup>, Md Rashed Khan<sup>5</sup>

### Abstract

*Appendicitis has its acute, subacute, recurrent and chronic forms. Appendicitis is commonly predisposed to and precipitated by a single or a combination of multiple discrete factors like obstruction of lumen, ischemia from thromboembolic episodes, infection or idiopathic etc. Typically, it starts as umbilical or peri-umbilical or midline abdominal dull aching pain that soon gets localized in the right iliac region. Movements worsen the pain. Other typical features include nausea, vomiting, anorexia, pyrexia, preference to lie down with or without curling up, chills, constipation, diarrhea, fever, shaking etc. The atypical symptoms of appendicitis include a dull or sharp pain anywhere in the abdomen, back, rectum, painful urination, bloating, flatulence, generalized abdominal tenderness, distension simulating acute intestinal obstruction, enlarging abdominal mass with or without overlying skin erythema, normal bowel movements, normal vital signs and even with no pain, no nausea, no vomiting no pyrexia or no weight loss. These atypical symptoms very often misguide the primary care physicians and the surgeons resulting in failure of diagnosis putting the patients to the risks of life-endangering complications. Diagnosis of appendicitis in absence of typical features are to be made from pre-occupied knowledge and clinical suspicion with or without the help of biochemical and/or imaging studies. Early and timely diagnosis and appropriate treatment are essential to save the life and to reduce the morbidity as well. Appendicitis should be thought in all cases of abdominal pain irrespective of its type and location, as must meningitis be thought in all cases of headaches.*

**Key words:** Abdominal pain, Anatomic variation, Abdominal distension, Diarrhea.

**Date of received:** 07.12.2020

**Date of acceptance:** 20.05.2021

**DOI:** <https://doi.org/10.3329/kyamej.v12i2.55444>

**KYAMC Journal.2021;12(02): 101-106.**

### Background

There are many unusual presentations of appendicitis that can lead to early misdiagnosis resulting in inevitable life-threatening complications.<sup>1</sup> The attending physicians (like family physicians, other primary care physicians and surgeons) need to be aware of its unusual presentations for early and timely diagnosis and treatment in order to prevent all the life-endangering complications. The atypical presentation of this common emergency condition demonstrates how appendicitis can be a very challenging problem for the primary care physicians and the surgeons. Once appendectomy is done for acute appendicitis, one will recover well very quickly.<sup>2</sup> Most patients can then

leave the hospital by one to two days following surgery. They will be able to resume their normal activities by two to four weeks. If it is complicated by bursting or perforation or gangrene or abscess formation, the patient may have to stay in the hospital from 5 to 7 days or more. The average operative mortality from appendicitis of about 0.2-0.8% is linked to its complications

### Introduction

The typical and classical presentation of acute appendicitis is that a dull aching abdominal pain of fluctuating intensity starts in the umbilical or periumbilical region or any other part of the

1. Professor & HOD, Dept. of Surgery. KhwajaYunus Ali Medical College, Enayetpur, Sirajganj.
2. Ex-Prof. of Obs & Gynae, Dhaka Medical College, Dhaka.
3. Medical Officer, Institute of Nuclear Medicine & Allied Sciences, Bangladesh Atomic Energy Commission, Dinajpur.
4. Honorary Medical Officer, Shaheed M Monsur Ali Medical College, Sirajganj.
5. Senior Registrar, Dept of Surgery. KhwajaYunus Ali Medical College, Enayetpur, Sirajganj.

**Correspondence:** ABM Moniruddin. Prof of Surgery, Khwaja Yunus Ali Medical College, Enayetpur, Sirajganj.

Mobile: +8801795078217. E-mail: abmmu@yahoo.com

middle regions of abdomen specially the epigastric regain one.<sup>3</sup> Within several hours, the pain gets shifted to the right lower side (the RIF -Right Iliac Fossa) of the abdomen, the site of its most common location. Without treatment the pain may become constant and severe. Pressing on this area (tenderness at the McBurney point), coughing, sneezing, walking, jogging, jumping, running or any other form of movement may worsen the pain. Other typical features include nausea, vomiting, recent loss of appetite (recent anorexia), pyrexia, disliking to move around with preference to lie down with or without curling up etc. Late symptoms include chills, constipation, diarrhea, fever, anorexia, shaking, nausea, vomiting etc.<sup>6</sup> Simple appendicitis has less than 48 hours of symptoms when imaging shows appendicitis without abscess or phlegmon. The subacute appendicitis is the milder form of acute appendicitis.<sup>7</sup> The Recurrent appendicitis (nonobstructive) usually has milder disappearing and reappearing symptoms over a long time, that may lead to fibrosis and adhesions and that may remain undiagnosed for several weeks, months or even years.<sup>8</sup> Few attacks of recurrent appendicitis will lead to chronic appendicitis that may present with episodic attacks of vague colicky pain and discomfort.<sup>9</sup> Stump appendicitis occurs in the long stump of appendix retained more commonly after laparoscopic appendicectomy.<sup>8</sup> Generally acute appendicitis commonly has much more severe symptoms that may perforate or burst suddenly within 24 to 48 hours. Presentations of a typical burst (rupture) appendix or gangrenous appendicitis include fever, nausea and vomiting, spreading pain all over the abdomen, board-like rigid abdomen, decreasing respiratory movements of the abdomen with or without abdominal distension etc.<sup>10</sup> Acute perforation or nonperforated acute appendicitis may be localized by the greater omentum, ileal loop/loops and caecum to form an appendix mass,<sup>11</sup> while suppuration may lead to appendicular abscess. Perforated appendicitis and acute suppurative appendicitis when localized present as a painful lump with overlying muscle guard and rigidity, fever, tachycardia, tachypnea and other features of sepsis.<sup>12</sup> Appendicitis with luminal blockage may rarely have the subsided inflammation with progressive collection of sterile mucus in its distal lumen causing its distension to form the mucocele of the appendix.<sup>13</sup> Offending microbes of appendicitis are usually mixed and include *E. coli* (85%), enterococci (30%), streptococci, anaerobic streptococci, *Cl. welchii*, bacteroides etc. Pseudoappendicitis usually associated with acute ileitis of *Yersinia* infection or more often due to Crohn's disease.<sup>14</sup> The atypical symptoms of appendicitis in many cases may appear as a dull or sharp pain anywhere in the upper or lower abdomen, back or rectum. These patients may have painful urination, vomiting, bloating, flatulence, generalized abdominal tenderness that may be more prominent in the lower abdomen, including the right and left quadrants, abdominal tenderness with or without abdominal distension simulating acute intestinal obstruction (that may be idiopathic or resulting from ileus, sepsis, septicemia etc.). The patients of acute appendicitis may present with an enlarging abdominal mass close to or away from the right lower quadrant with or without overlying skin erythema, normal bowel movements, normal vital signs and with or without pain, no nausea, no vomiting no pyrexia or no weight loss. These atypical symptoms very often misguide the primary care physicians, the surgeons and other attending physicians resulting in failure of

immediate diagnosis of acute appendicitis.<sup>1,6,14,15</sup>

## Epidemiology

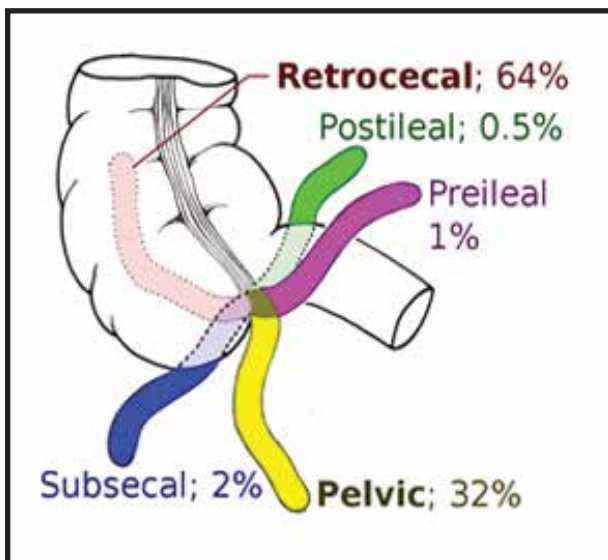
No age, no race and no sex are immune to appendicitis. It has got no geographical boundary. Appendicitis is claimed to be more common in males than in females, and this male preponderance is more in infants and pre-school going children than it is in children of school going age.<sup>15,16</sup>

## Incidence and Prevalence

Acute appendicitis is a very common emergency of general surgery with a lifetime risk of 7% to 8%.<sup>1</sup> Appendicitis can affect one in every one thousand people living in the western countries and affluent societies. Most cases of appendicitis attack people between the ages of ten and thirty years. Having a family history of appendicitis may increase the risk, especially if one is a male. Children of cystic fibrosis also seem to have higher risk of getting appendicitis. Atypical presentations of symptoms of acute appendicitis may be as high as in 30% to 45% of cases. Otherwise only a minority of patients with acute appendicitis may have the classical presentations.<sup>17</sup>

## Anatomical Considerations

Average length of the vermiform appendix in adult humans varies between 6 to 10 cm. There is a correlation between its length and age or body weight of humans, where its length of about 2 to 20 cm has been documented.<sup>4,18</sup> The appendix is most commonly located in the RIF. Rarely it may be located ectopically in the right hypochondrium, midline, left hypochondrium and left lower quadrant which are due to developmental errors like malrotation of gut. While its base is at the RIF attached to the caecum, its tip may lie floating deep in the pelvic cavity behind the urinary bladder or touching the top of the urinary bladder because of its larger mesoappendix and longer length.<sup>17</sup> It may lie among the pelvic organs in females. The appendix most commonly lie behind the colon (called the retro-caecal appendix). It may lie just below the caecum (sub-caecal) or abutting onto the caecum (para-caecal), behind the terminal ileum (retro-ileal) or just in front of the ileum (pre-ileal). The appendix has also been found embedded within the caecal wall in a very few cases of retro-caecal position. The abnormally greater length and abnormal location, abnormal position and distorted disposition of the appendix may lead to more incidence of appendicitis because of impediment with free drainage of its contents. A side-stitch (stitch like pain on right side), also known as ETAP (Exercise-related Transient Abdominal Pain), is a pain that may be felt on both sides of the abdomen. This pain may range from cramping or a dull aching to a pulling sensation or a sharp, stabbing pain.<sup>18</sup>



**Fig. 1:** Some approximate positions of the appendix as it is related to the caecum and the terminal ileum.

### Aetiology and Pathology

The exact aetiology in many cases remain uncertain and unknown. In some cases, many causative factors have been identified. Appendicitis may result from obstruction of its lumen, most commonly by lymphoid hyperplasia and sometimes by a faecolith, foreign body (Swollen seeds of vegetables and fruits such as those of oranges, figs, melons, grapes, cocoas, dates, nuts, oats barley, cumins etc.), or even worms (mostly threadworms also known as pinworms) or neoplasms (specially Ca caecum, carcinoid tumour).<sup>19</sup> The obstruction leads to its distension. Retention of its secretions and other contents invite microbial invasion and infection (mostly bacterial). Invaded bacteria multiply rapidly, causing the appendix inflamed, swollen, edematous that may lead to pyogenic appendicitis.<sup>18</sup> Often there occurs appendiceal mural ischemia due to distension with or without inflammatory thromboembolic episodes. All these events will lead to gangrene of the appendix. if untreated, necrosis, gangrene, perforation and even rupture (burst) may occur by 48 to 72 hours. This description represents the most likely the aetiology and the pathology of acute appendicitis. The various types and such stages of appendicitis as early, phlegmonous (catarrhal), suppurative, gangrenous, perforated, spontaneous resolving, recurrent, and chronic have been described by different researchers. Histopathologically presence of polymorphs in its muscle coats is the diagnostic hallmark of acute appendicitis.<sup>3,17,19</sup>

### Diagnosis

The length, location and position of the appendix is very much important for diagnosis of appendiceal pathologies and to differentiate these pathologies from other abdominal diseases. The diagnosis of acute appendicitis is almost obvious and clear-cut when the patient presents with typical classical symptoms. Polymorph leukocytosis and other indicators of sepsis like raised CRP (C-Reactive Protein) in presence of

typical features are often diagnostic.<sup>2,6</sup> However, presentations may often be variable and atypical due to multiple causes including its varied locations, positions, lengths and dispositions (called the anatomical variations) in different people of different families and races indicating genetic links and developmental errors like malrotation of gut etc. Definite diagnosis of atypical presentation is usually also missed or delayed in children, elderly, patients with immunodeficiency (Congenital or acquired like AIDS), immunosuppression (as in prednisolone or anti-cancer chemotherapy), immunocompromising (as in diabetes mellitus) and during pregnancy.<sup>3,9</sup> Investigations, tests and procedures to diagnose acute appendicitis include: Proper history taking (for time, duration, location and shifting of pain, nausea, vomiting, pyrexia etc.), tenderness at right iliac fossa, Dumphy's cough tenderness, Blumberg's Release sign of rebound tenderness, Rovsing's sign, Cope Psoas test, Cope's obturator test, Baldwin's test for retrocaecal appendicitis, Bapat bed shaking test, Heel drop test, the Obsolete Bastedo sign/test, polymorph leukocytosis, positive (high) C reactive protein suggestive of acute inflammation (appendicitis), usually normal urine test, normal abdominal x-ray showing no free gas under the domes of diaphragm, no abnormal fluid levels, normal intestinal gas shadows and normal KUB region, distended edematous vermiform appendix specially on 4-D ultrasonogram etc. To diagnose & exclude a urinary tract pathology, it needs to do routine urine examination, Ultrasonogram (USG), X-ray KUB region. To exclude other causes of abdominal pain it often needs to perform abdominal and Chest X-rays, 4-D USG (Ultrasonogram), CT scan Imaging tests, ECG, Echocardiography etc. Intravenous and oral water soluble contrast x-ray were previously done to detect retrocecal appendicitis.<sup>5,15</sup> Common differential diagnoses of appendicitis include Gastroenteritis (stomach flu), constipation, perforated duodenal ulcer, ovarian cyst, ovarian torsion, oophoritis and other PID (Pelvic Inflammatory Diseases) ovulation pain (Mittelschmerz), inguinal hernia, pneumonia, ischemic heart diseases specially acute myocardial infarction, cholecystitis, pancreatitis, Meckel's diverticulitis, typhlitis, ureteric colic, Intussusception, worm infestation, mesenteric or iliac lymphadenitis, inflammatory bowel diseases like Crohn's disease and ulcerative colitis, amebic colitis, ileocecal tuberculosis, ileocecal lymphoma, pseudolymphoma, carcinoma caecum, kidney diseases like pyelonephritis, urinary tract infection specially ureteritis, cystitis, ureterolithiasis, intestinal obstruction, gravid uterus, implantation pain (recent implantation of embryo inside the uterus), ectopic pregnancy specially tubal pregnancy, tubal abortion, diabetic ketoacidosis, meningitis, Pott's disease, lobar pneumonia, Basal pneumonia, testicular torsion, epididymo-orchitis, diverticulitis (sigmoid or caecal), dissecting/ruptured aortic aneurysm, pre-herpetic pain of right tenth and eleventh dorsal nerves, secondaries of the spine, multiple myeloma, osteoporosis, acute crisis of porphyria etc.<sup>12,13,16</sup> Other differential diagnoses include pseudomyxoma peritonei, complicated enterocutaneous fistula (ECF) as a result of an underlying appendiceal mucocele, cystadenocarcinoma or carcinoid tumours of the appendix, which may rarely present as a cutaneous fistula, and other infective causes of an abscess such as actinomycosis etc.<sup>1,3,4,5</sup>

## Treatment

Treatment of acute appendicitis is commonly surgical in the form of emergency appendectomy through gridiron or Lanz incision.<sup>1,7,9</sup> Non-pyogenic, nonperforated and nongangrenous appendicular lump is preferably treated following Ochsner Sherren regimen (NPO, IV fluid, nutrition, antibiotics, electrolyte balance and regular monitoring of patient's general condition including pulse, blood pressure, respiration, temperature, size of the lump, etc.) followed by (if the patient's condition improves) delayed appendectomy two to three months later when the lump gets totally resolved. If the patient's condition deteriorates (as may occur in cases of abscess formation, gangrenous or perforated appendix within the lump), emergency surgery is to be done usually through laparotomy by midline or right paramedian incision. Appendix abscess is best treated by early extraperitoneal drainage through a muscle cutting incision, intensive broad-spectrum antibiotic therapy and performing interval appendectomy two to three months later after resolution of lumpy abscess. Gangrenous or localized perforated appendix may well be dealt through gridiron incision. Burst appendix usually needs laparotomy through right paramedian or midline incision to perform adequate peritoneal cleaning and toileting, in addition to doing appendectomy. If the patient develops features of intestinal obstruction, laparotomy through right paramedian or midline incision is to be done to deal effectively with the condition.<sup>11,16</sup>

## Discussion

Acute appendicitis is one of the most common acute diseases requiring emergency surgical treatment. In most cases, proper history taking and careful physical examination alone without any other diagnostic adjunct is sufficient to arrive at a diagnosis. When the diagnosis is unclear from the history and examination, frequent physical examinations and monitoring the patient's status and undertaking the appropriate imaging studies will usually guide to the appropriate diagnosis. Two or more episodic attacks of acute appendicitis, each lasting for not more than one to two days, is considered as recurrent appendicitis. Contrariwise, chronic appendicitis usually occurs as a less severe, nearly each attack of continuous abdominal pain lasting for more than a 48-hour period, sometimes extending to weeks, months, or even years. All people with acute appendicitis don't necessarily have the similar or same symptoms, but all of them are to consult a physician as soon as feasible. The inflamed appendix can rupture within 24 to 48 hours of onset of symptoms. The following atypical symptoms necessitate consultation: severe or recurrent or progressive abdominal pain where diagnosis is uncertain, such general symptoms as fever and pain in the right lower abdomen or pain in other sites of abdomen.<sup>4,7,17</sup> The dull aching pain of acute appendicitis during pregnancy may more often be felt at right upper quadrant of abdomen (rather than at right lower quadrant). Pyrexia, anorexia, nausea, vomiting may be present. Initially mere stitch-like or indigestion-like feeling may be the only presenting feature until the pain shifts over several hours to the right side and a palpable lump is noticed. Appendicitis may make one urinate (pee) a lot because of irritation of nearby or adjoining ureter or the urinary bladder, which can imitate the symptoms of a urinary tract infection. Appendicitis can make one defecate (poop) more. Appendicitis may feel like period cramps in females.<sup>5</sup> The pain

of burst appendix may be in one area, but not necessarily the lower right abdomen, or it may be in the entire abdomen. The pain can be either a dull ache or sharp and stabbing. Fever is usually persistent, even when one takes antibiotics. One may have other symptoms, like chills and weakness. One may have appendicitis without any fever. An inflamed appendix doesn't always get perforated or ruptured more commonly. In some people, the appendix bursts more quickly. Non-perforated and non-burst appendicitis are more common than perforated and burst appendicitis. About three hours following perforation or rupture of the inflamed appendix, the patient becomes seriously ill because infective peritonitis along with substantial systemic disturbances in the form of bacteremia, sepsis, septicemia and life-endangering septic shock. Occasionally, a perforated or a ruptured appendix may heal by its own without definitive treatment when the pain and infection resolves naturally. Or a ruptured appendix or even a case of suspected appendicitis may be treated successfully with antibiotics alone. But, if the diagnosis of acute appendicitis is made, it is almost always to be treated as a surgical emergency because of incipient life-endangering complications. Burst, perforated and gangrenous appendices are potentially life-endangering complications.<sup>13</sup> Most appendicitis cases are not complicated. This means that the organ hasn't perforated or ruptured or suppurated or is not gangrenous or pyogenic. So these patients with uncomplicated appendicitis can be treated successfully with antibiotics instead of appendectomy. Now, it is suggested by many researchers that only when the appendix looks likely to be complicated, immediate emergency operation is absolutely indicated. It is also suggested that most teens will need to have their appendix removed as soon as feasible. Appendectomy ensures that the appendix has no chance to be inflamed again or to be complicated and has no chance to spread the infection.<sup>8,18</sup> The standard worldwide treatment for acute appendicitis is appendectomy. After appendectomy, one is to avoid strenuous activities, such as bicycle riding, running, jogging, weight lifting, or aerobic exercise at least for several months. One may be able to take showers (unless a drain is there near the incision) 24 to 48 hours after operation. The incision area is to be kept dry at least until healing is complete.<sup>11,13</sup>

There is no way of preventing appendicitis other than having prophylactic appendectomy. But as the appendix has definite immune functions, prophylactic appendectomy isn't recommended routinely by many researchers. Lifestyle modification can modify the incidence of appendicitis. People who drink at least ten to twelve glasses of water daily eat fiber-rich diets like fresh fruits, vegetables to encourage smooth digestive process and regular bowel movement and who keep their intestines dewormed are claimed to get appendicitis less. It is also claimed that consuming one tablespoon of green gram (not tea) thrice daily may effectively help treating appendicitis. Buttermilk (in the form of whey or Cream or butter or ghole) is claimed to be beneficial in appendicitis, as it is easier to digest. Now it is well documented that one can live a normal life without an appendix. Changes in life-style or diet or exercise are traditionally not essential. Excessive intake of alcohol or smoking may exacerbate appendicitis. Previously some researchers claimed that people without an appendix may have slightly higher rates of infection than those with a functioning organ. It may also toll

slightly more time to recover from any illness, especially those where the beneficial gut bacteria have been flushed out of the body.<sup>14,18</sup>

### Prognosis

A new study has documented that around 60 percent of patients who were treated with antibiotics did not have a recurrence of appendicitis within five years. When a patient attends at the hospital with acute appendicitis, the standard course of action is to remove the appendix as an emergency surgery with the aim of cure of this potentially life-endangering disease.<sup>9,19</sup>

### Conclusion

Atypical presentations and complications of appendicitis are quite common worldwide. Emergency physicians (Eps) should be aware of the fact that appendicitis may not always present with a typical and classical presentations. They should consider the possibility of appendicitis when evaluating an acute abdomen to prevent any delay in diagnosis of appendicitis with atypical presentations to prevent all incipient life-endangering complications. In these atypical cases, it is only clinician's suspicion and pre-occupied knowledge and appropriate imaging studies will steer up to the definite diagnosis of appendicitis. Knowledge about anatomical variations of the appendix and variable atypical presentations of appendicitis and complications thereof can aid in timely and confident diagnosis. Intra-operative location of the appendix can also be presumed. Patient's comorbidities are to be addressed adequately for success of total management.

### Recommendations

1. Appendicitis should be thought in all cases of abdominal pain irrespective of its type and location, as must meningitis be thought in all cases of headaches.
2. Ruptured/Perforated appendicitis may present in a very atypical manner.
2. Appendicular masses including appendiceal abscess are to be differentiated from other conditions of abdominal wall masses.
3. Atypical clinical presentations are to be suspected specially in elderly patients or when there is no previous history of performing appendicectomy are available.
4. It is equally important to find out and treat the underlying pathology that caused appendicitis.

### Acknowledgement

We are very much thankful to Prof Md Zulfikar Ali of the department of medicine of Khwaja Yunus Ali Medical College, Enayetpur, Sirajgonj for his continuous encouragement and inspiration in publishing this important and interesting review article entitled "Atypical Presentations of Appendicitis".

### References

1. Association of Surgeons of Great Britain and Ireland (ASGBI), Royal College of Surgeons (RCS). Commissioning guide: emergency general surgery (acute abdominal pain) 2014. Published online.
2. Muthukumarasamy G, Steele P, Sharp C. Abdominal wall abscess due to penetrating caecal cancer: an unusual presentation. *J Gastrointest Cancer* 2012;43:131–132.
3. Kim KY, Park WC. Necrotizing fasciitis arising from an enterocutaneous fistula in a case of an appendiceal mucocele. *Ann Coloproctol* 2015;31:246–250.
4. Jha NK, Sinha DK, Anand A. Mucinous cystadenoma of the appendix with enterocutaneous fistula: a therapeutic dilemma. *Gastroenterol Rep (Oxf)* 2015;3:86–89.
5. Jagdish S, Ninan S, Pai D Spontaneous appendicocutaneous fistula. *Indian J Gastroenterol* 1996;15:31.
6. Nakao A, Sato S, Nakashima A. Appendiceal mucocele of mucinous cystadenocarcinoma with a cutaneous fistula. *J Int Med Res* 2002;30:452–406.
7. Nam SH, Kim JS, Kim KH. Primary tuberculosis appendicitis with mesenteric mass. *J Korean Surg Soc* 2012;82:266–269.
8. Yi F, Prasad S, Sharkey F Actinomycotic infection of the abdominal wall mimicking a malignant neoplasm. *Surg Infect (Larchmt)* 2008;9:85–89.
9. Haas GP, Shumaker BP, Haas PA. Appendicovesical fistula. *Urology* 1984;24:604–609.
10. Singal R, Gupta S, Mittal A. Appendico-cutaneous fistula presenting as a large wound: a rare phenomenon-brief review. *Acta Med Indones* 2012;44:53–56.
11. Gockel I, Jäger F, Shah S. Appendicitis necessitatis: appendicitis perforating the abdominal wall. *Chirurg* 2007;78:840–842.
12. Chowdhury DA, Hassan MF, Rahman M. . Spontaneous appendico-cutaneous fistula, after drainage of a right loin abscess—a case report. *Int J Surg* 2008;6:e 97–99.
13. Oliver Beaumont, Robert Miller, and Richard Guy. Atypical presentation of appendicitis. *BMJ Case Report*. Published online 2016, Nov 10. doi: 10.1136/bcr-2016-217293. PMID: 27873747.
14. Yildiz M, Karakayali AS, Ozer S. Acute appendicitis presenting with abdominal wall and right groin abscess: a case report. *World J Gastroenterol* 2007;13:3631–3633.

15. Garipey LJ, Kenley PG. Acute suppurative appendicitis with abscess formation and subsequent perforation of the anterior abdominal wall. *Am J Surg* 1945;70:386–388.
16. Ishigami K, Khanna G, Samuel I et al. Gas-forming abdominal wall abscess: unusual manifestation of perforated retroperitoneal appendicitis extending through the superior lumbar triangle. *EmergRadiol*2004;10:207–209.
17. Lin YY, Tsai SH, Chu SJ. Abdominal wall abscess in a diabetic patient with ruptured appendicitis. *J Trauma* 2008;65:492
18. Gee D, Babineau TJ. The optimal management of adult patients presenting with appendiceal abscess: ‘conservative’ vs immediate operative management. *CurrSurg* 2004;61:524–528.]
19. Genier F, Plattner V, Letessier E et al. [Post-appendectomy fistulas of the cecum. Apropos of 22 cases]. *J Chir (Paris)* 1995;132:393–378.