

## Case Report

### Hydatid Cyst Of Lung

Rahman ML<sup>1</sup>, Badruzzaman M<sup>2</sup>, MoklesuzzamanAKM<sup>3</sup>, Kabir MM<sup>4</sup>,  
Gani MM<sup>5</sup>, Hossain MA<sup>6</sup>

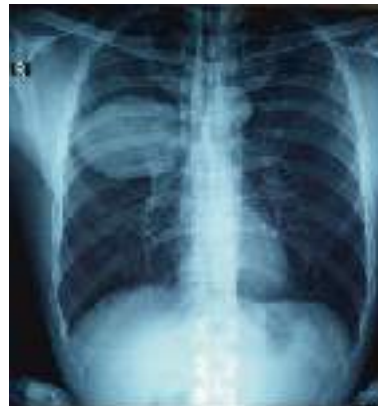#### Abstract

Lung hydatid cyst may be primary or secondary. In our case, the cyst was a single one locating in right middle lobe. Hydatidosis locating in different sites, particularly the liver may be associated. Initial growth of primary hydatidosis is asymptomatic. The evolution of the cyst may produce bronchial fistulization and intrapleural rupture. Breaking of primary visceral hydatid cyst in a vein or heart producing hydatidosis is rare. Progressive respiratory deficiency and right ventricular failure due to multiple malignant primary hydatidosis is a special form. The recognition of certain details of the lesion and discover others are not visible by conventional radiography, can be done by ultrasonography, computed tomography and magnetic resonance imaging. Surgery is the treatment of choice. Chemotherapy is used in general as a complement to surgical treatment to prevent recurrence. The goal of surgery is to remove the parasite and to treat the bronchialpericyst pathology with other associated lesions. The results are now commonly satisfactory. Prolonged air leakage and pleural infection are most frequent complication.

**Keywords-** Hydatid disease, *E. granulosus*, Barret technique.

#### Case report

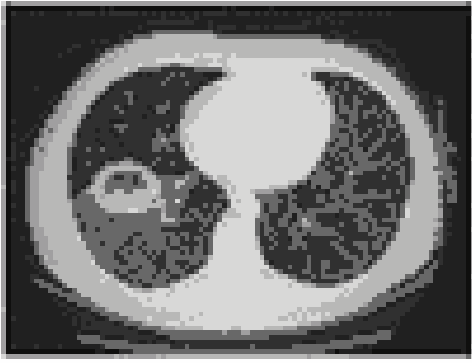A 45 years male, Omar Ali, farmer from Elenga, Tangail, attended in Medical out patient department (MOPD), Khwaja Yunus Ali Medical College & Hospital (KYAMCH) on 08.01.13 with the complaints of intermittent cough and haemoptysis, low grade fever, weight loss, anorexia for the last two month. He went to local doctor and took conservative management. But could not relief. After he attended in OPD a chest radiograph (CXR) and associated investigations were done.



CXR P/A view showing hydatid cyst in right mid zone

1. Dr. Md. Lutfar Rahman, Associate Professor, Department of Cardiothoracic Surgery, KYAMCH, Sirajgonj.
2. Dr. Md. Badruzzaman, Assistant Professor, Department of Cardiothoracic Surgery, KYAMCH, Sirajgonj.
3. Dr. AKM Moklesuzzaman, Associate Professor, Department of Medicine, KYAMCH, Sirajgonj.
4. Dr. Md. Mainul Kabir, Assistant Professor, Department of Cardiothoracic Surgery, KYAMCH, Sirajgonj.
5. Dr. Md. Masumul Gani Chowdhury, Assistant Professor, Department of Paediatric Cardiac Surgery, Shishu Hospita, Dhaka.
6. Dr. Md. Alamgir Hossain, Associate Professor, Department of Radiology and Imaging, KYAMCH, Sirajgonj.

**Correspondence :** Dr. Md. Badruzzaman. Email- badruzzaman2008@gmail.com



CT Scan of the chest

The CXR showed a central hilar vascular prominence, well defined, almost oval shaped, well margined homogeneous opacity noted in right mid zone. Then he was advised to do a CT scan of the chest. The CT scan of the chest showed right sided cystic lesion possibilities of Hydatid cyst. Then he was referred to the department of Cardiothoracic surgery. He had no significant past history of illness. He was normotensive, non-smoker and non-diabetic and bowel and bladder habit was also normal. He had no hepatosplenomegally. Other organs were normal. His other relevant investigations were within normal limit. He underwent total enucleation of the cyst through right posterolateral serratus anterior saving thoracotomy through the 5th, intercostal spaced, on 10.01.2013. His diagnosis was confirmed by histopathology report. His recovery from the operation was uneventful. After discharge he attended in OPD after 15 days. His CXR and other relevant investigations were normal.

### Operative procedure

We started operation early in the morning at 8.00 am. Right lateral thoracotomy was done accordingly. Lung deflated. The cyst was identified in the middle lobe. It was about 10 cm.×8 cm.× 7 cm. in diameter, well circumscribed. The enucleated cyst was sent for histopathology. The area was covered with 3% NaCl soaked mop. A cleavage was made through horizontal fissure between middle and lower lobe. An incision was made over the pericyst. The ectocyst including endocyst totally came out. The raw area was washed with 3% NaCl solution. The lung was inflated and any leakage was checked under water with up to 30 mm Hg. hand pump pressure through endotracheal tube. The eroded small bronchi were closed with pledgeted prolene. Chest was closed by layers keeping a 32 size chest drain tube connecting with an under water sealed two chambered drainage bottle. Patient

was transferred to ICU at 11.30 am. with stable haemodynamic status with no inotropic support.



Enucleated specimen of Hydatid Cyst

### Course in the ICU/ post-operative status

Mechanical ventilatory support was given to the patient for 2 hours. Then was extubated from the ventilation when all the criteria for extubation were fulfilled. Patient was in the ICU for only 1 day. Then he was shifted to cabin on first post-operative day. Chest tube was kept for 15 days due to some unusual air leakage which healed spontaneously. Patient was discharged with a 3 month course of post-operative albendazole with advice to attend in OPD for further follow up. We followed up the patient for 6 month with relevant investigations and detected no abnormality.

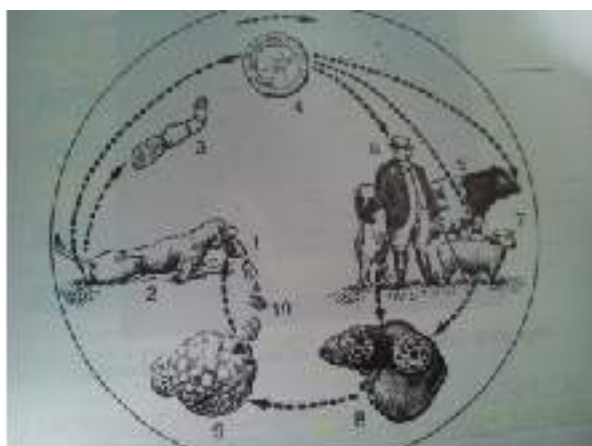
### Discussion/Pathophysiology of Hydatid diseases

Hydatid disease is a parasitic infestation caused by *Echinococcus Granulosus*. It is endemic in many region and Yemen is one of the endemic region<sup>1</sup>. After liver (most common), Lungs (30%) are the second most common sites, other organ involvement is about 10%. Either small or medium majority of lung hydatid cyst are asymptomatic. Asymptomatic Hydatid cyst are usually identified during routine CXR. The common presentations are compression symptoms such as dry cough in cases of very large cyst, a productive cough in cases associated with communication with bronchial tree, and chest pain and dyspnoea in case of ruptured of

the pleural cavity<sup>2</sup>. Anaphylactic reaction is rare presentation seen in cases of rupture to the pleural cavity, the patient may be in good general health<sup>3</sup>. The diagnosis is easy. Routine CXR will show a well circumscribed dense homogenous opacity, a water-lily radiological sign is a diagnostic feature for a cyst when it communicates with a small bronchus and detached laminated membrane<sup>4</sup>. Grape skin-like materials in productive cough is diagnostic in ruptured hydatid cyst communicating with medium sized bronchioles. In our patient the diagnosis was incidental in routine investigation for low grade fever when a dense homogenous opacity sized >10 cm in diameter in mid zone of right lung was detected. The most small cyst is treated medically where surgical intervention is not mandatory (Albendazole with a dose of 10 mg per kg body weight for three courses of 28 days each, with a rest of 2 weeks in between)<sup>5</sup>. Larger cyst usually needs surgical treatment in addition to Albendazole either pre-operative or pre- and post-operative<sup>6</sup>.

### Life cycle of the parasite

The parasite is a small tapeworm. This is *Taeniaechinococcus* and dogs are the usual source of infestation. The normal life cycle of the cyst is between the dog and the sheep. The adult tapeworm resides in the alimentary tract of the dog and the ova are excreted in the faeces. Sheep feeding in this areas ingests the ova which develops in to hydatid cysts in the viscera. The cycle is completed when the sheep are fed to dogs. Incidentally man becomes infested with the ova when comes in close contact with the dogs<sup>5</sup>.



Life cycle *E. Granulosus* in brief

1. Offal infected with hydatid cyst, 2. Dog eating offal,
3. *E. Granulosus*, 4. Ova, 5. Cattle, 6. Human, 7. Sheep ingest the eggs. 8. Liver- infected with hydatid cyst, 9. Hydatid Cyst

The ova in hands of man are ingested when eating. The ova burrows the gastric mucosa, enter the radicals of portal vein, then they develop in hydatid cyst in liver and may enter into the lung. The ova of the hydatid cyst may lie deeply in the substance of the lung. As it grows, any advance towards the hilum is resisted by the unyielding bronchovascular structures. There is therefore a tendency for the cyst to grow towards the periphery, finally abut upon a pleural surface. The cyst lies within lung substances in a cavity that grows with the enlarging parasite. There is no direct fusion between the cyst and the lung parenchyma. The contained fluid within the cyst is secreted by the germinal layer of the cyst. This fluid contains brood capsules and scolices and if any is spilled in the field of operation dangerous anaphylactic reaction may occur or new cyst may develop later on. The germinal layer also secretes outside it a white laminated membrane formed by the successive deposition of a number of hyaline layers the oldest being on the outside<sup>6</sup>.

**Prevention-** Avoidance of pet dogs and eating of salad after tape water cleaning is main way to prevent the infestation.

**Conclusion-** Non complicated hydatid cyst have a good prognosis and safely be treated by parenchyma-preserving surgery (Barrette technique).

### References

01. Ghallab NH, Alsabahi AA, "Hydatid cyst of the lung , a case report" *Eur J Pediatr Surg.* 199;121-4. di: 10.10/s-2008-1066184.[PubMed][Cross Ref]
02. Husen YA, Nadeem N, Aslam F, Bhaila I, Primary splenic hydatid cyst: a case report with characteristic imaging appearance. *J Pa Med Assoc.* 200;219-21.[Pub Med]
03. Kavukchu S, Killic D, Toat AO, Kutlay H, Cangir Ak, Enon S, Okten I Ozdemir N, Gungor A, Akal M, Akay H, Parenchyma preserving surgery in the management of pulmonary hydatid cyst. *J Invest Surg.* 2006;19:61-68. doi:10.1080/089419300044486. [PubMed] [Cross REF]

04. Karaoglanoglu N, Kurkcuoglu IC, Gorguner M, Eroglu A, Turkyilmaz A, Giant hydatid lung cysts. *Eur J Cardiothorac Surg.* 2001;19:914-917. doi: 10.1016/S1010-7940(01)00687-X.[PubMed] [Cross Ref]
5. Fontana VP, Montevideo, Baily and Loves short practice of Surgery, 22nd. edn. "The liver" 701-720.
6. Safioleas M, Misiakos EP, Dosios T, Manti C, Lambrou P, Skalkeas G: Surgical treatment for lung hydatid disease. *World J Surg* 1999, 23(11):1181-1185. PubMed abstract, Publisher Full Text.