

Case Report

"Tuberculous Dactylitis" (Spina Ventosa) in a 19 years old boy - a very rare disease

Howlader MJ¹, Siddique S², Siddique AB³

Abstract

Tuberculous Dactylitis is an unusual form of osteoarticular tuberculosis, involving the short bones of the hand & feet. Hence it is also known spina ventosa. In our case, a 19 years old boy presented with a swelling in the middle part of right ring finger which was provisionally diagnosed as a Giant cell tumor while the possibility of spina ventosa (Tubercular dactylitis) was kept in mind. He was admitted for curettage of the phalanx followed by bone grafting. Histopathological examination report confirmed it as Spina ventosa

Introduction

Tuberculosis is an infectious disease caused by *Mycobacterium tuberculosis* and manifested by formation of tubercles and caseous necrosis in tissues. Tuberculous infection of metacarpals, metatarsals, and phalanges of hand and feet is known as tubercular dactylitis (spina ventosa)¹. The hand is more frequently involved than the foot. Tuberculosis of the metacarpals, metatarsals and phalanges is uncommon after the age of 5 years. Eighty -five percent of the patient are younger than 6 years of age. Tubercular dactylitis in adult is rare.

Case report

A 19 year old boy was presented with a swelling in the middle part of right ring finger for two years. The swelling was initially small and gradually increasing in size. It was associated with dull aching pain for last 6 months. On examination, a spindle shaped swelling 3cm×2cm was noted in the middle phalanx of right ring finger. The swelling was bony hard in consistency, tenderness was present and temperature slightly raised. Movement were slightly restricted at the proximal interphalangeal joint of the right ring finger, on general examination build was average and there was no significant peripheral lymphadenopathy.

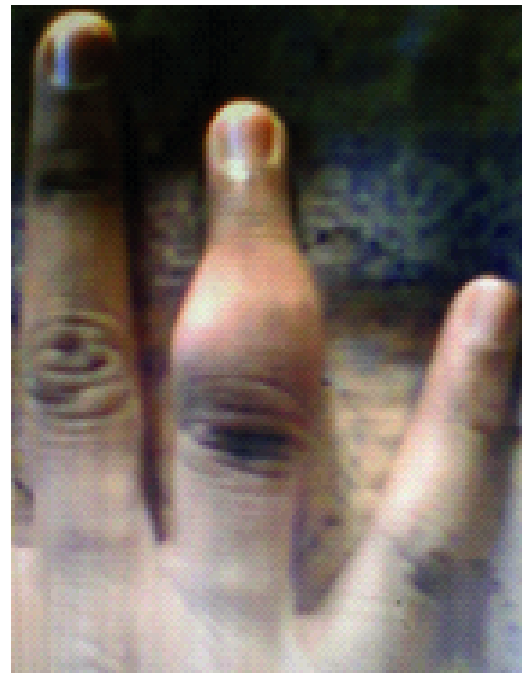


Fig-1: Pre-operative picture of lesion

Haematological report showed Haemoglobin - 16.4g/dl, ESR-10 mm in 1 hr, X-ray chest p/A showed normal in study but Mantoux test was positive.

1. Dr Muhammad Jahangir Howlader, Assistant Professor, Department of Orthopedics, Khwaja Yunus Ali Medical College & Hospital, Enayetpur, Sirajgonj.
2. Dr. Sohana Siddique, Associate Professor, Department of Obs. & Gynae, Khwaja Yunus Ali Medical College & Hospital, Enayetpur, Sirajgonj.
3. Dr. Abu Bakar Siddique, Assistant Professor, Department of Radiology & Imaging, National Institute of Ophthalmology, Dhaka.

A radiograph of right hand showed an expansile lytic lesion in the middle phalanx of ring finger. The margins were well defined with internal septations and associated cortical sclerosis. There was cortical destruction present.

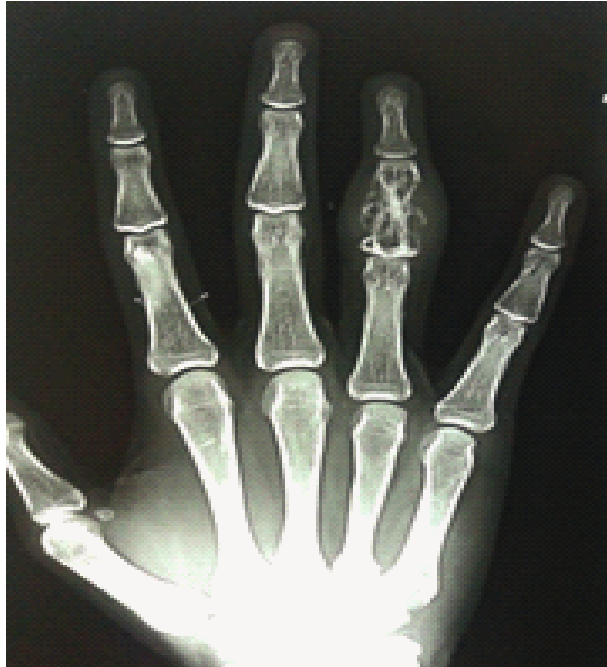

Fig-2: Pre-operative radiograph

CT Scan report showed bony expansion, thinning and irregularity seen in middle phalanx of ring finger and proximal interphalangeal joint space reduced and suggested FNAC.

FNAC report showed features of Giant Cell Tumor of bone and a provisional diagnosis of Giant Cell tumor was made, while tubercular dactylitis was kept in mind. Differential diagnosis were osteoblastoma, enchondroma. The boy was recommended for surgery and curettage of middle phalanx was done followed by bone graft. The specimen sent for histopathology examination and showed Granulomatous Inflammation, Histologically tubercular and confirmed it was a tubercular dactylitis (Spina ventosa) and patient got 9 month regimen antitubercular drugs, now he is quite normal able to do everything by his right hand and interphalangeal movement excellent.

Discussion

Bone and joint tuberculosis occur in 1-5 percent children who have untreated initial pulmonary

tuberculosis and spread to the skeletal system during the initial infection via the lymphohaematogenous route². The skeletal infection becomes symptomatic within 1-3 years after the initial infection. Eighty five percent of children with tuberculous dactylitis are younger than 6 years of age and its incidence among children with tuberculosis was reported to be 0.65-6.9 percent³. The bones of hand are more frequently affected than the bones of feet with the proximal phalanx of index and middle finger more frequently affected.

The condition usually presents as a painless swelling of a digit of a few months duration. The radiographic feature of cystic expansion of short tubular bones has led to the name of SPINA VENTOSA being given to tuberculous dactylitis of the short bones of the hand^{3,4} periosteal reaction and sequestra are not common but may occur. Sclerosis may be seen in long standing cases.

During childhood, these short bones have a lavish blood supply through a large nutrient artery entering almost in the middle of the bone. The first inoculum of infection is lodged in the centre of the marrow cavity and the interior of the short tubular bone is converted gradually a tuberculous granuloma. This leads to a spindle shaped expansion of the bone (SPINA VENTOSA) with the occlusion of the nutrient artery of the involved bone and the destruction of internal lamellae (or formation of sequestra). In natural course, the disease heals with shortening of the involved bone and deformity of the neighbouring joint.

Tuberculous dactylitis needs to be differentiated on one hand from chronic pyogenic osteomyelitis and syphilitic dactylitis and on other hand from neoplastic conditions with lytic lesions (enchondroma and fibrous defect). Other granulomatous conditions which mimic tuberculous infection are mycotic infection, sarcoidosis and brucellosis.

Management is essentially done by anti-tubercular drugs, rest to the part in functioning position and early active exercise of the involved parts or joints. In patients with unfavorable response or recurrence of infection, surgical debridement is justified. If a metacarpophalangeal, metatarsophalangeal or interphalangeal joint is ankylosed in awkward position excision arthroplasty or corrective osteotomy is indicated. In a finger has ankylosed of more than one joint, is grossly deformed scarred and interfering with normal -

functioning it may be wise to amputate the finger or the corresponding ray⁵. In our case a provisional diagnosis of Giant Cell Tumor was made, while tuberculous dactylitis was kept in mind. Differential diagnosis were osteoblastoma. Surgery conducted and curettage of middle phalanx of right ring finger and bone graft was done. The specimen sent for Histopathology examination showed, epitheloid granuloma suggestive of tuberculosis. Mantoux test was positive and anti-tubercular drugs was started post operatively.

Conclusion

In general tubercular dactylitis is treated with anti-tubercular drugs. However, in this case, pre-operative diagnosis could not be made. Therefore, we started with surgical intervention and anti-tubercular drugs were added post-operatively. After completion of anti-tubercular drugs therapy, at 2 years follow-up patient was completely disease free and healthy and joint movement of that finger was excellent.

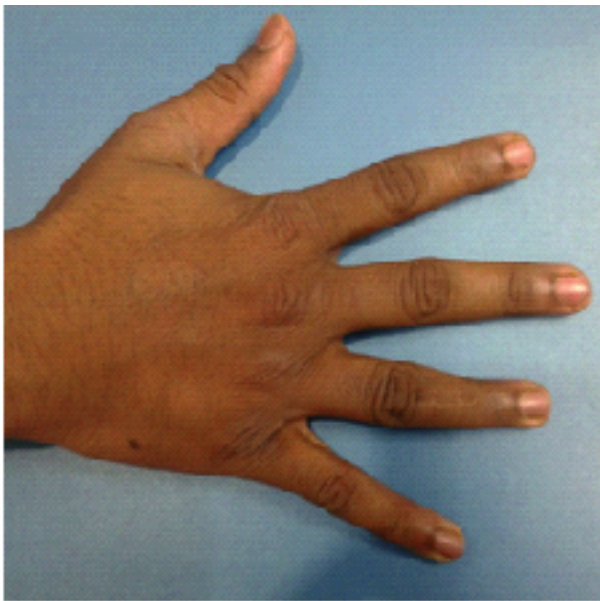


Fig-3: Post-operative Picture of rt hand after 2 years follow-up.

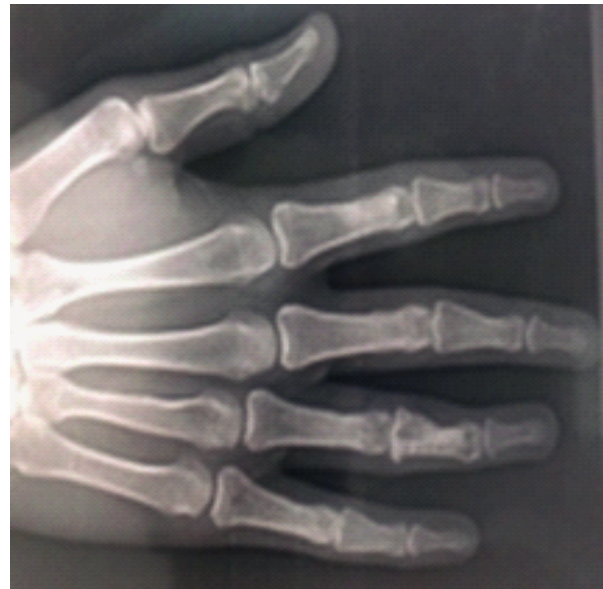

Fig-4: Post-operative radiograph after 2 years

References

1. Tuli SM. Tuberculosis of short tubular bones Tuberculosis of the skeletal system. New Delhi: Joypee Brothers Medical Publishers; 1991,pp-164-5.
2. Kushwaha RA. Kant S. Verma SK. Sanjay Mehra S. Case report: Isolatedmetacarpal bone tuberculosis A case report, Lung India;2008;25 (1):00-3
3. Gyanshankar PM, Dhangaye TM, Amol BF, Spina Ventosa discharging tubercle bacilli-a case report. Indian J Tuberc. 2009;56 (2).00-3
4. Malik S, Joshi S, Tank JS. Cystic bone tuberculosis in children- a case series. Indian J tuberc. 2009,56 (4);220-4
5. Roy, AK, Khanduri S, Girigha KM. pot the diagnosis: Fusiform swelling of fingers in a 3 years old girl, J postgraduate Med.