

Original Article

Management of Displaced Supracondylar Fracture of Late Presentation in Children by Open Reduction and Internal Fixation

Islam MA¹, Rashid MA², Milon MHR³, Solayman M⁴, Khan MAH⁵

Abstract

Background: In late presentation of cases there is dilemma whether to wait for osteotomy later or do open reduction on arrival. The purpose of this prospective multicentric study is to evaluate the functional outcome of open reduction and internal fixation (ORIF) with crossed Kirschner wires fixation and early joint motion in the late presentation of supracondylar fractures in children. **Methods:** A total of 21 children, with an average delay of 22.5 days, with displaced type III Gartland supracondylar fracture, were treated by ORIF with crossed Kirschner wires fixation and early joint motion. Average follow-up was 12 months. **Results:** Flynn's criteria were used to evaluate the outcome. All of them had more functional range of motion of the injured elbow than the published reports. **Conclusions:** Most of the surgeons in the developing world prefer ORIF for optimal results. Thus it appears to be justifiable to go for ORIF with K-wires even in the late presentation of supracondylar fractures. The overall results are encouraging. However, the small number of cases and lack of control group are the limitations of this study. The study is ongoing and so the full report with more cases will be presented later.

Keywords: Displaced supracondylar fractures open reduction and internal fixation.

Introduction

Supracondylar fractures are one of the most common elbow fractures seen in paediatric orthopaedic clinics worldwide¹. These fractures comprise 55% to 75% of elbow fractures and approximately 3% of all fractures in children^{2,3}. Between 10% and 20% of cases report late for treatment in developing countries⁴. Late presentation is defined as roughly more than 2 days after injury⁵ and objectively is defined as when a callus is visible in X-rays, but a fracture line is still visible. A delay in presentation for treatment at a proper hospital may

result from poor transportation, ignorance, and/or inability of the child's parents. Sometimes, lack of skilled personnel or suitable resources can delay or deny suitable treatment in a hospital in poor countries. In developing countries, the percentage of late presentation is much higher because of poor health care delivery systems and patients reaching the tertiary care centre late from a long distance⁶. Malunion resulting in cubitus varus is common in 10%- 30% of cases regardless of the method of treatment. This deformity does not improve with remodelling⁵.

1. Dr. Md. Ashraful Islam, Assistant Professor, Department of Orthopaedic Surgery & Traumatology, KYAMCH, Enayetpur, Sirajgonj.
2. Dr. Md. Abdur Rashid, Associate Professor, Department of Orthopaedic Surgery & Traumatology, KYAMCH, Enayetpur, Sirajgonj.
3. Dr. Md. Hafizur Rahman Milon, Registrar, Department of Orthopaedic Surgery & Traumatology, KYAMCH, Enayetpur, Sirajgonj.
4. Dr. Mohammed Solayman, Assistant Professor, Department of Paediatrics, KYAMCH, Enayetpur, Sirajgonj.
5. Dr. Md. Asmaul Hossain Khan, Medical Officer, Department of Orthopaedic Surgery & Traumatology, KYAMCH, Enayetpur, Sirajgonj.

Correspondence: Dr. Md. Ashraful Islam, Assistant Professor, Department of Orthopaedic Surgery & Traumatology, Khwaja Yunus Ali Medical College & Hospital, Enayetpur, Sirajgonj. Email-khokon_107@yahoo.com

The treatment modalities implicated in late presenting cases are as follows:

- (i). Continuous traction of the arm to gradually reduce the fracture, which avoids the risk of vascular complications and iatrogenic ulnar nerve injury but has the disadvantage of prolonged hospital stay⁷.
- (ii). Early wedge osteotomy 1-4 months after injury but before adolescence⁸.
- (iii). Open reduction and internal fixation^{9,10}. There is not much literature regarding specific treatment guidelines for late presentation of supracondylar fracture in children, so the treatment method remains controversial.

Materials and methods

This is a prospective and multicentric study in Khwaja Yunus Ali Medical College and Hospital with follow-up at^{2,4,12} and 24 weeks and finally at 1 year. Average follow-up was 1 year. Between December 2014 and August 2016, a total of 21 patients sought treatment with a delay between 15 and 30 days (average 22.5 days) after the injury. The reason for the delay was inadequate treatment in 18 patients and ignorance in 3 patients. A total of 110 cases of displaced type III Gartland supracondylar fracture were treated at Khwaja Yunus Ali Medical College and Hospital within the study period in the years from 2014 to 2016. Out of 110 cases only 21 (19.1%) cases were included in the study. Patients who had a callus but a visible fracture line on their radiograph were included in the study. Those with open fracture, intra-articular fracture, stable supracondylar fracture (Gartland type I), or fracture with a callus without a visible fracture line were excluded from the study. Detailed examination of the neurological and vascular status of the limb was performed. Antero-posterior and lateral radiograph of the elbow were obtained from the injured and normal elbows, and the Baumann angle was measured. Open reduction using a posterior approach with midline triceps split was performed. All visible calluses were removed to clean and recreate the fracture. Then, the anatomic reduction of fracture fragments was stabilized with crossed K-wires and checked under an image intensifier for reduction and stability. In one patient, more than one K-wire was inserted for laterally better stability. K-wires were buried under the skin, which reduces the chance of infection and lowers the risk of early removal of an infected K-wire and subsequent displacement of fracture fragments¹¹. Skin sutures were removed at 2 weeks, and the back slab was removed for early mobilization of the

elbow when it is pain-free. The buried K-wires were removed at 06 weeks after fracture consolidation. All patients were discharged 48 hours after the surgery. At 12 weeks, the range of motion and carrying angle were measured with a goniometer and graded according to Flynn's criteria (Table 1). The Baumann angle was measured for radiological assessment¹². The patients were also evaluated for functional range of motion of the injured elbow, which is established as 75-120 degrees of flexion with an arc of motion of 45 degrees necessary for feeding and toilet purposes¹³.

Table 1: Flynn's criteria for grading¹⁴.

Result	Rating	Cosmetic factor (carrying angle loss) (degrees)	Functional factor (motion loss) (degrees)
Satisfactory	Excellent	0-5	0-5
	Good	5-10	5-10
Unsatisfactory	Fair	10-15	10-15
	Poor	Over 15	Over 15

Results

All fractures united. All the cases were followed up for one year. Two patients were lost to follow-up after 6 weeks and so they were excluded from the study. The average age of the patients was 7.4 years (range: 5-10 years) with 12 males and 09 females with right elbow being the predominant injury side, 12 out of 21. All injuries were Gartland type III injuries and closed fractures. The average delay time of presentation to us was 15 days (range: 10-20 days). The average range of motion loss of the injured elbow compared to the normal elbow was 42.1 degrees (range: 5-70 degrees) and the average carrying angle loss was 16.4 degrees (range: 0-30 degrees). The mean Baumann angle of the injured elbow was 78.1 degrees (range: 70-85 degrees) compared to 72.8 degrees (range: 70-80 degrees) for the normal elbow. Cubitus varus was seen in 12 patients (57.1%), 3 patients had carrying angle gain (14.3%), three had carrying angle loss but the elbow was in the valgus position (14.3%), and 3 patients had no varus deformity (14.3%). Patients were graded according to Flynn's criteria, which take into account range of motion loss (functional factor) and carrying angle loss (cosmetic factor)¹⁴. The overall rating is made on the basis of greater clinical loss of functional or cosmetic factors. Three patients (14.3%) had an excellent rating and a satisfactory result, and 18 patients (85.7%) had poor ratings and unsatisfactory results (Table 2).

Table 2: Overall grading of patients according to Flynn's criteria¹⁴.

Grading	Cosmetic factor (carrying angle loss)	Functional factor (motion loss)	Overall number (%)
Satisfactory			
Excellent	0-5	0-5	3 (14.3%)
Good	5-10	10-15	
Fair	10-15	10-15	
Unsatisfactory	10-15	10-15	18 (85.7%)
Poor	Over 15	Over 15	

All patients had painless and useful range of motion at the last follow-up. The flexion of the elbow ranged from 110 to 145 degrees (average of 127.1 degrees). The extension ranged from 0 degrees to limitation of full extension by 40 degrees (average of 22.8 degrees lag). All of our patients had a more functional range of motion of the injured elbow than established by Vasen et al.¹³ (Table 3).

Table 3: Functional range of motion obtained.

Number of cases	Flexion (degrees)	Extension (degrees)	Arc of motion (degrees)	Useful arc of motion (%) (compared with Vasen et al. ¹³)
03	125	35 lag	90	200
03	140	15 lag	95	277.8
03	115	45 lag	70	155.5
03	145	05 lag	140	311.1
03	130	0	130	288.9
03	105	20 lag	85	188.9
03	130	40 lag	90	200

Three patients had iatrogenic ulnar nerve palsy due to technical error, which spontaneously recovered after the medial buried K-wire was removed, as it had impinged the ulnar nerve, which was observed when the K-wires were removed. Beyond this, no other intraoperative complications or postoperative complications were observed in the study. There was no radiographic evidence of heterotopic ossification in our study. Eighteen parents were satisfied regarding the useful range of movement and appearance of the elbow, while 3 parents were unsatisfied regarding the appearance of the elbow (Figure 1).

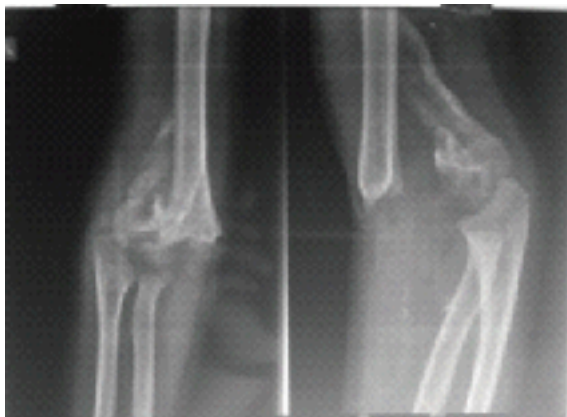


Figure-1: (Pre-Operative Radiography).

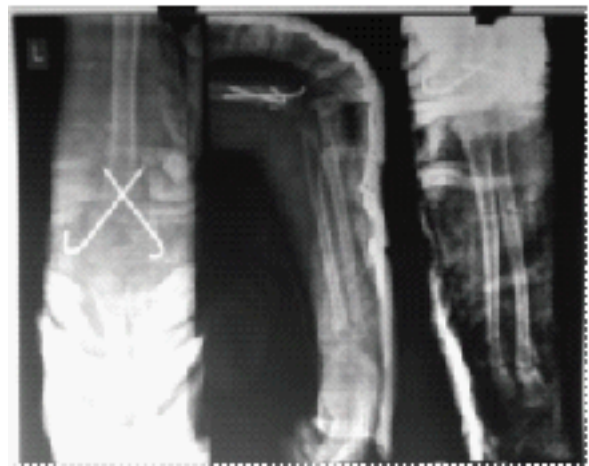

Figure-2: (Post-Operative Radiography)

Discussion

The prognosis of displaced supracondylar humeral fracture with late presentation in children is unfavourable if the child presents one day after injury¹⁵ (Table 4).

Study	Year	Journal	Number	Presentation	Mean Delay	Hospital stay	Treatment	Mean follow-up	Complications	Functional Outcome
01	Lal and Bhan [8]	1991	Int. Orthop.	20	11-17 days				35% varus	
02	Leet et al. [23]	1994-1999	J Pediatr.Ortho.	158	2.7hrs - 6.6 days	21 hrs	26 min - 6days	16.7wks	1.26% varus <1% pnttract infection	
03	Devnani [5]	1990-2001	CI Ortho.	28	2-21 days	5.6 days	14 days	24mths	18%>10 deg. varus	good 71%, fair 4%, poor 25%
04	Mahaisavariya [7]	1994-2004	Techniques in Orthopaedics	9	1-4mths	3.2mths		13.3mths	5%>15 deg. (5-48)	
05	Tiwari et al. [22]	2002-2003	J. of Ortho. Surg.	40	2-12 days	4 days	41 hrs	18mths	5%>15 deg. varus 10% nerve palsy (5% R, 2.5% M, U each) 5% Trochlear necrosis 7.5% stiffness ROM loss > 15 deg.	88%, Flynn's criteria
06	Eren et al. [6]	1992-2005	J. Child Orthop.	31	2-19 days	6 days	2 days	4 yrs (2-11 yrs)	22.5% cubitus varus 6.5% pnttract infections	
07	Dua et al. [24]	2003-2007	Chinese J. of Traumatology.	40	12 hrs - 3 days	17.55 hrs	12 hrs	15mths (12-24)	5% mild myositis	95% excellent Flynn's

According to Flynn's criteria¹⁴, 14.3% (3 cases) of patients had satisfactory results and 85.7% (18 cases) had unsatisfactory results. The incidence of cubitus varus was 57.1% (12 patients). However, all our patients obtained more than double the functional range of motion established by name, et al.¹³ for activities of daily living (Table 3).

Lal and Bhan⁸ obtained 35% incidence (20 patients) of cubitus varus among patients who had open reduction 11-17 days after the injury, but 70% of them (14 patients) had an arc of motion of less than 90 degrees. Compared with this study, our results had a higher incidence of cubitus varus (57.1%), but the arc of motion achieved was more.

Only 2 patients (28.6%) had an arc of motion of less than 90 degrees compared to 14 patients (70%) in their study. Ali, et al.¹¹ reported 12% poor results after open reduction because of limited movement. Reitman et al.¹⁰ reported cubitus varus in 13 of 52 patients (25%) after open reduction and K-wire fixation. Mahaisavariya⁷ included children presenting up to 3 weeks after injury. Lal and Bhan⁸ included children upto 4months after the injury in their series but for early wedge osteotomy rather than open reduction and internal fixation. To the best of our knowledge, there has not been any study beyond 3 weeks of delay, so we took up the task to operate on injured elbows and evaluate the functional and cosmetic outcome in those children with callus formation but a visible fracture line on a radiograph, which included children with delays up to 30 days after injury.

Some authors¹⁶ prefer to let the fracture malunite and later perform a corrective osteotomy to avoid myositis ossificans and stiffness. Theoretically, the fracture should be left alone until solid union occurs and the patient regains full range of motion of the elbow to full extension, and then corrective osteotomy is scheduled⁸. However, in our part of the world, the parents of the children want treatment upon presentation and do not accept corrective osteotomy at a later date. Moreover, the patients are not compliant and are lost to follow-up when such advice is given. Considering these circumstances, we feel that it is justified to offer them treatment by open reduction and internal fixation of displaced fractures with crossed K-wires.

The Flynn, et al.¹⁴ grading system is more severe than that of Aronson and Prager¹⁷, and loss of range of motion greater than 15 degrees compared to the normal elbow is graded as an unsatisfactory result. However, clinically, the patient has a useful range of motion for activities of daily living. In all of our patients anatomical reduction was achieved. However, the resulting deformity at the elbow made it difficult to predict the outcome. Displaced supracondylar fractures of the humerus almost always unite, but malunion

resulting in cubitus varus is common. Its reported incidence ranges from 10 to 57% regardless of the method of treatment^{18,19}. The deformity does not improve with time, as seen in our study²⁰. In our study the range of motion of the injured elbow improved with time. There was improvement in the range of motion at the 6-month follow-up relative to the 3-month follow-up. The initial decrease in range of motion could be due to the posterior approach, which provides adequate exposure but results in scarring of posterior soft tissue and increased elbow stiffness²¹. However, movement of the elbow nearly always recovers after healing of a supracondylar fracture in children¹². Open reduction and internal fixation are a better treatment option in displaced supracondylar fractures of the humerus in patients presenting even late after injury in our set-up. This approach minimizes the risk of complications and the need for continuous traction or corrective osteotomy²².

References

1. J. C. Cheng and W. Y. Shen, "Limb fracture pattern in different pediatric age groups: a study of 3350 children," *Journal of Orthopaedic Trauma*, vol. 7, no. 1, pp. 15-22, 1993.
2. J. C. Y. Cheng, T. P. Lam, and N. Maffulli, "Epidemiological features of supracondylar fractures of the humerus in Chinese children," *Journal of Pediatric Orthopaedics Part B*, vol. 10, no. 1, pp. 63-67, 2001.
3. K. E. Wilkins, "Supracondylar fractures of the distal humerus," in *Rockwood and Wilkins' Fractures in Children*, J. M. Flynn, D. L. Skaggs, and P. M. Waters, Eds., pp. 487-557, Lippincott Williams & Wilkins, Philadelphia, Pa, USA, 7th edition, 2010.
4. A. Devnani, "Late presentation of supracondylar fractures of humerus in children," in *Neglected Musculoskeletal Disorders*, A. K. Jain and S. Kumar, Eds., pp. 335-342, Jaypee Brothers Medical, 1st edition, 2011.
5. A. S. Devnani, "Late presentation of supracondylar fracture of the humerus in children," *Clinical Orthopaedics and Related*
6. A. Eren, M. G˘uven, B. Erol, and M. Cakar, "Delayed surgical treatment of supracondylar humerus fractures in children using a medial approach," *Journal of Children's Orthopaedics*, vol. 2, no. 1, pp. 21-27, 2008.

7. B. Mahaisavariya, "Late treatment of displaced supracondylar fractures of the humerus using early wedge osteotomy," *Techniques in Orthopaedics*, vol. 21, no. 2, pp. 150-157, 2006.
8. G. M. Lal and S. Bhan, "Delayed open reduction for supracondylar fractures of the humerus," *International Orthopaedics*, vol. 15, no. 3, pp. 189-191, 1991.
9. A. J. Weiland, S. Meyers, V. T. Tolo, H. L. Berg, and J. Mueller, "Surgical treatment of displaced supracondylar fracture of the humerus in children," *The Journal of Bone & Joint Surgery- American Volume*, vol. 60, pp. 657-661, 1978.
10. R. D. Reitman, P. Waters, and M. Millis, "Open reduction and internal fixation for supracondylar humerus fractures in children," *Journal of Pediatric Orthopaedics*, vol. 21, no. 2, pp. 157- 161, 2001.
11. A. Ali, A. Q. Mohammad, and A. Zain, "Pin tract infection rates between percutaneous and buried Kwire in supracondylar fracture of humerus in children," *Pakistan*, vol. 26, no. 2, pp. 146-150, 2010.
12. P. Worlock, "Supracondylar fractures of the humerus. Assessment of cubitus varus by the Baumann angle," *The Journal of Bone & Joint Surgery-British Volume*, vol. 68, no. 5, pp. 755-757, 1986.
13. A. P. Vasen, S. H. Lacey, M.W. Keith, and J. W. Shaffer, "Functional range of motion of the elbow," *The Journal of Hand Surgery*, vol. 20, no. 2, pp. 288-292, 1995.
14. J. C. Flynn, J. G. Matthews, and R. L. Benoit, "Blind pinning of displaced supracondylar fracture of the humerus in children, sixteen years experience with long term follow up," *The Journal of Bone and Joint Surgery. American Volume*, vol. 56, no. 2, pp. 263-272, 1974.
15. J. A. Wilson, "Injuries of the elbow," in *Watson-Jones Fractures and Joint Injuries*, vol. 2, pp. 583-649, Churchill Livingstone, Edinburgh, UK, 6th edition, 2000.
16. W. J. Mitchell and J. P. Adams, "Supracondylar fractures of the humerus in children," *Journal of the American Medical Association*, vol. 175, pp. 235-252, 1961.
17. D. D. Aronson and B. I. Prager, "Supracondylar fractures of the humerus in children: a modified technique for closed pinning," *Clinical Orthopaedics and Related Research*, vol. 219, pp. 174-184, 1987.
18. R. T. Davis, J. T. Gorczyca, and K. Pugh, "Supracondylar humerus fractures in children: comparison of operative treatment methods," *Clinical Orthopaedics and Related Research*, vol. 376, pp. 49-55, 2000.
19. A. S. Devnani, "Lateral closing wedge supracondylar osteotomy of humerus for post-traumatic cubitus varus in children," *Injury*, vol. 28, no. 9-10, pp. 643-647, 1997.
20. M. Carcassonne, M. Bergoin, and H. Hornung, "Results of operative treatment of severe supracondylar fractures of the elbow in children," *Journal of Pediatric Surgery*, vol. 7, no. 6, pp. 676-679, 1972.
21. T. Gosens and K. J. Bongers, "Neurovascular complications and functional outcome in displaced supracondylar fractures of the humerus in children," *Injury*, vol. 34, no. 4, pp. 267-273, 2003.
22. A. Tiwari, R. K. Kanojia, and S. K. Kapoor, "Surgical management for late presentation of supracondylar humeral fracture in children," *Journal of Orthopaedic Surgery*, vol. 15, no. 2, pp. 177-182, 2007.
23. A. I. Leet, F. Juan, and E. Edward, "Delayed treatment of type 3 supracondylar fractures of the humerus," *Journal of Pediatric Orthopaedics*, vol. 22, pp. 203-207, 2002.
24. A. Dua, K. K. Eachempati, R. Malhotra, L. Sharma, and M. Gidaganti, "Closed reduction and percutaneous pinning of displaced supracondylar fractures of humerus in children with delayed presentation," *Chinese Journal of Traumatology*,