

Original Article



Outcome of Nasolabial Flap in Buccal Mucosal Reconstruction in Oral Squamous Cell Carcinoma

Rokonuzzaman¹, Md. Zahedur Rahman², Md. Shahidul Islam³.

Abstract

Background: Surgical defects of oral cavity and orofacial region are challenging because of the aesthetic and functional demands and dynamic nature of the area. A multitude of reconstructive options are available and with the advent of musculocutaneous flaps and free microvascular tissue transfer, orofacial reconstruction has entered an era of sophistication whereby repair of defects of all types and sizes has become possible.

Objectives: This study was conducted to evaluate the functional outcome, surface texture and complications of nasolabial flap for reconstruction in the buccal mucosal defects. **Materials and Methods:** A cross-sectional observational study was conducted 20 patients with clinical histological diagnosed squamous cell carcinoma (SCC; T1-T3) involving buccal mucosa attending in the Oral and Maxillofacial Surgery department of Dhaka Dental College and Hospital during this study period were included purposively in the study. All patients were treated by excision of the lesion and subsequent reconstruction of the defect by nasolabial flap. If indicated then patients received adjuvant radiotherapy. They were examined preoperatively, immediate postoperatively, on discharge and 3 months after operation. Data were analyzed by SPSS statistics (version 20) software. To find out the significance of the result one way ANOVA was conducted and the Post Hoc Test was done by LSD.

Results: Among 20 patients 15% (3) patients developed infection, 15% (3) patients developed dehiscence. Trismus occurred in 5% (1) patient. In assessment of interincisal opening of the patients, 90% (18) presented with adequate interincisal opening but it has been reduced in 10% (2) patients after radiotherapy. In 90% (18) patients surface texture of the flap were smooth and in 10% (2) were partially smooth. **Conclusion:** The nasolabial flap has proved to be a useful and reliable option for reconstruction of defects of the buccal mucosa in order to allow wound closure without tension and maintain oral function.

Key words: Nasolabial Flap, Buccal Mucosal Reconstruction, Oral Squamous Cell Carcinoma.

Date of received: 25.12.2018.

Date of acceptance: 25.02.2019.

KYAMC Journal.2019;10(1):48-53.

DOI: <https://doi.org/10.3329/kyamej.v10i1.41484>

Introduction

Oral malignancies are one of the most prevalent malignancies in the world, leading to one of the 10 most common causes of death. Oral malignancies represent approximately 13% of all malignancies, thereby, translating into 30,000 new cases every year.¹ The majority 84-97% of oral malignancies are SCCs.² The countries of South Asian region including India, Pakistan, Bangladesh, Sri Lanka, Bhutan, Nepal, Iran and Maldives are particularly affected with oral cancer ranking either first or second with regard to different types of cancer prevalence in these countries.² According to Bangladesh Bureau of Statistics, cancer is the sixth leading cause of death in Bangladesh. There are 13 to 15 lakh cancer patients in Bangladesh, with about 2 lakh patients newly diagnosed with cancer each year.³ Oral cancer is the 2nd most common cancer in male and 3rd position

in female in Bangladesh. According to a recent WHO study, there are 49000 oral cancer cases in Bangladesh.⁴ In a study, Molla and Shaheed showed prevalence of oral cancer in Bangladesh accounts for 20% of all malignancies. Oral Squamous Cell Carcinoma (OSCC) accounts for 90% of oral cancer in Bangladesh.⁵ Oral cancer is an age related disease and 60% of the patients are over the age of 40 years. Cancer of mouth is considerably more common in man than woman. The distribution of oral cancer according to site has a different pattern in South East Asia for that in the western part of the world. The major primary lesions are located at the mandibular gingiva (40%) and buccal mucosa (33.6%).⁶

The mainstays of treatment in these cases are surgical excision of the primary lesion and cervical lymph node with the addition of radiation and chemotherapy as an adjuvant.

1. Medical Officer, Oral & Maxillofacial Surgery Department, Dhaka Dental College & Hospital, Rangpur, Bangladesh,

2. Assistant Professor, Department of Science of Dental Materials, Rangpur Dental College, Rangpur, Bangladesh

3. Associate Professor & Head, Department of Prosthodontics, & Dental Unit, Khwaja Yunus Ali Medical College & Hospital, Sirajganj, Bangladesh

Correspondence: Dr. Rokonuzzaman, Medical Officer, Oral & Maxillofacial Surgery Department, Dhaka Dental College & Hospital, Rangpur, Bangladesh, Mobile - 01912925005, E-mail : rokon.udc@gmail.com

Surgical excision of the lesion does not only result in trismus, wound dehiscence, infection but also aesthetic mutilation because of the exposed character of the head and neck region.⁷ Surgical defects of oral cavity and orofacial region are challenging because of the aesthetic and functional demands and dynamic nature of the area. A multitude of reconstructive options are available and with the advent of musculocutaneous flaps and free microvascular tissue transfer, orofacial reconstruction has entered an era of sophistication whereby repair of defects of all types and sizes has become possible. However, these techniques are not suitable for every patient, as at times, either the defect is too small or the patient's age and medical status do not permit a prolonged general anesthesia and lengthy surgical procedure. The nasolabial flap represents the available local tissue that often avoids these problems for repair of 2-5cm extra or intra-oral defects.⁸

The first reported use of nasolabial flap as fasciocutaneous flap dates back to 600BC, as described by Pers and then for many centuries it has been used for nasal and lateral lip reconstruction.⁹ There was the first to use a transbuccal transfer of this flap for closure of palatal fistula and intraoral defects while Esser did a cutaneous nasolabial flap transfer in two stages to increase its reliability.¹⁰ Wallace and Rose later introduced various modifications of the basic flap for single-stage transfer. Further flap modifications were introduced to obtain better cosmetic results and to cover relatively larger defects.¹⁰⁻¹² Superiorly based nasolabial flaps can be used for reconstruction of nasal defects, lower eyelid, and the cheek, whereas the inferiorly based flaps are considered useful in reconstruction of defects of the lip, oral commissure, and the anterior oral cavity.⁷

The nasolabial flap is a local arterialized flap with an axial blood supply provided either by the facial artery (inferiorly based flap), or by the superficial temporal artery through its transverse facial branch, and the infraorbital artery (superiorly based flap).¹¹⁻¹³ It is a reliable, versatile, and easy to raise flap for a variety of small to medium sized defects in the orofacial region. The first nasolabial flap for intraoral reconstruction was reported toward the end of the 19th century.^{11,14}

Currently the proven reliability of the nasolabial flap, with its predictable functional and acceptable aesthetic results, makes it the ideal local flap for reconstruction of oral defects that are too large for primary closure and too small for conventional musculo-cutaneous and micro vascular free flaps.¹⁵ Other major advantages of this flap are its versatility, easy to raise flap, a quick single stage procedure; and, its viability is not affected by facial artery ligation when synchronous neck dissection is performed in SCC patients.^{16,17}

There are numerous options available for reconstruction of the oral cavity defects, depending upon the site, size and other requirements of the defect. For reconstruction of smaller defects of the oral cavity options range from primary closure to secondary healing from mucosalisation, or covering the defect site with split thickness skin grafts. Most of these modalities may result in functional complications in terms of, trismus, wound dehiscence, infection. The versatility and the

usefulness of nasolabial flap is now well recognized in orofacial reconstruction and intraoral use of the nasolabial flap is a simple, fast and reliable procedure and minimizes the morbidity related to scar formation, trismus, wound dehiscence, infection to a great extent.¹⁷⁻¹⁹ This study would reveal it may be harvested in a safe, single stage procedure and does not require elaborate technique and aftercare. This study was conducted to evaluate the functional outcome, surface texture and complications of nasolabial flap for reconstruction in the buccal mucosal defects.

Materials and Methods

A cross-sectional observational study was conducted at Department of Oral and Maxillofacial Surgery, Dhaka Dental College and Hospital, Mirpur-14, Dhaka from August 2016 to July 2017. Twenty patients with clinical histological diagnosed squamous cell carcinoma (SCC; T₁-T₃) involving buccal mucosa attending in the Oral and Maxillofacial Surgery department of Dhaka Dental College and Hospital during this study period were included purposively in the study. The selected patients were informed of the surgery and method of closure of the surgical wound, its advantage and complication. Those who had fulfilled and gave consent for the study and agree to return for follow up are to be enrolled for the study finally. This study was designed to assess the functional, esthetic outcome and postoperative complications of nasolabial flap used for the reconstruction of buccal mucosal defects. Throughout the study, the patients were evaluated preoperatively, intraoperatively and postoperatively for various parameters. The protocol was approved by the "Research Review Committee" of the Department of Oral and Maxillofacial Surgery of Dhaka Dental College and Hospital. Finally, ethical clearance was taken from the "Ethical Committee" of Dhaka Dental College. Patients included in the study, were explained about the procedure and outcome of the research in details and written consent was taken. A standardized structured data collection sheet was used to collect necessary information of the subject group. Data sheet included all of the variables eg. Age, Sex, Size of the defect (Defect dimension), Size of the flap (Flap dimension), Trismus, Wound Dehiscence, Flap necrosis, Infection, Surface texture regarding to the study. All patients were treated by excision of the lesion and subsequent reconstruction of the defect by nasolabial flap. If indicated then patients received adjuvant radiotherapy. They were examined preoperatively, immediate postoperatively, on discharge and 3 months after operation.

Surgical Technique

The flaps are elevated directly under vision; the plane is deep to the subcutaneous tissue and superficial to the underlying muscles. During dissection, the facial artery, submental artery, and external jugular vein are ligated if the neck dissection is combined with the resection of a primary tumor in a clinically node-positive neck. The tip of the flap was extended to a point approximately 15 mm distal to the medial canthus, while the width depended upon the width of the defect. If the facial

artery was preserved, a width to length ratio of 1:3 was maintained. In cases where the facial artery was ligated, a ratio of 1:2 was maintained. After the flap was raised to the desired extent, it was rotated inwards and insetted using 4/0 Prolene sutures. The mucosal part of the flap was sutured using 3/0 MonosynW. When used for commissural defects, a V-Y commissuroplasty was added as a second-stage procedure. For reconstruction of the buccal mucosa where no incision was made on the lips, the flap was insetted using a buccal tunnel. After 3 weeks, the flap was divided and the tunnel was closed.

Data analysis

Data were screened and cleaned for any discrepancy. After cleaning the data were recorded on a predesigned data collection sheet and analyzed by SPSS statistics (version 20) software. To find out the significance of the result one way ANOVA was conducted and the Post Hoc Test was done by LSD.

Results

Patients who underwent surgery age ranging from 35 to 68 years with a mean of 52.85±8.54 years (figure-1). Figure-2 shows among the 20 patients 60% (12) were male and 40% (8) were female. The minimum size of defect was 2x2 cm² and maximum size of defect was 4x4.5 cm². The minimum flap size used was 3X 4 cm² and maximum size of the flap used was 5X5 cm² (Table I). Figure 3: shows 02 (10%) patients had pT2N0 disease; 06 (30%) patients had pT2N1 disease; 12 (60%) patient had pT3N1 disease. Among 20 patients 15% (3) patients developed infection, 15% (3) patients developed dehiscence. Trismus occurred in 5% (1) patient (Table II). In assessment of preoperative and postoperative (On discharge and after 3 months) interincisal opening of the patients, 90% (18) presented with adequate interincisal opening but it has been reduced in 10% (2) patients after radiotherapy (Table III). Figure- 4 demonstrates, in 90% (18) patients surface texture of the flap were smooth and in 10% (2) were partially smooth.

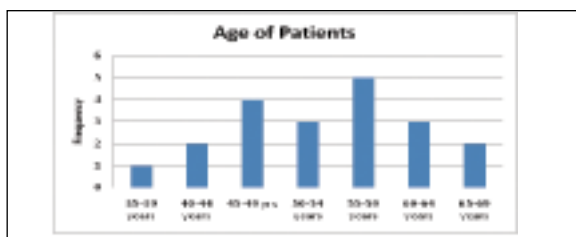


Figure 1: Age of patients

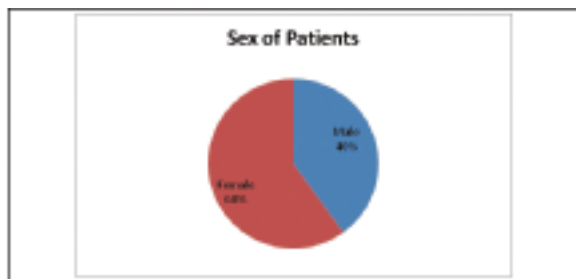


Figure 2: Age of patients

Table I: Sites of lesion, defect dimension and Size of the flap (n=20)

Case	Site of lesion	Defect Dimension (cm) ²	Size of the flap(cm) ²
1	Lower buccal mucosa of Rt. side	2x2	3x4
2	Lower buccal mucosa of Rt. side	4x4.5	5x5
3	Lower buccal mucosa of Lt. side	4x4.5	5x5
4	Lower buccal mucosa of Rt. side	3.5x4	4x5
5	Upper buccal mucosa of Lt. side	4x4.5	5x5
6	Lower buccal mucosa of Lt. side	4x4.5	4x5
7	Upper buccal mucosa of Lt. side	3.5x4	4x6
8	Upper buccal mucosa of Rt. side	2.5x4	3x5
9	Lower buccal mucosa of Rt. side	4.5x4	5x5
10	Lower buccal mucosa of Rt. side	3x3.5	4x5
11	Upper buccal mucosa of Rt. side	2x2	3x4
12	Lower buccal mucosa of Lt. side	4 x4.5	5x5
13	Lower buccal mucosa of Lt. side	4x4.5	5x5
14	Lower buccal mucosa of Rt. side	4x4.5	5 x5
15	Upper buccal mucosa of Lt. side	3x3.5	3x4.5
16	Lower buccal mucosa of Rt. Side	4.5x4	5x5
17	Upper buccal mucosa of Rt. Side	4x4.5	5x5
18	Upper buccal mucosa of Rt. Side	3x3.5	3x4.5
19	Lower buccal mucosa of Lt. side	4x4.5	5x5
20	Lower buccal mucosa of Rt. side	4x4.5	5X5

Lt.-Left, Rt.-Right

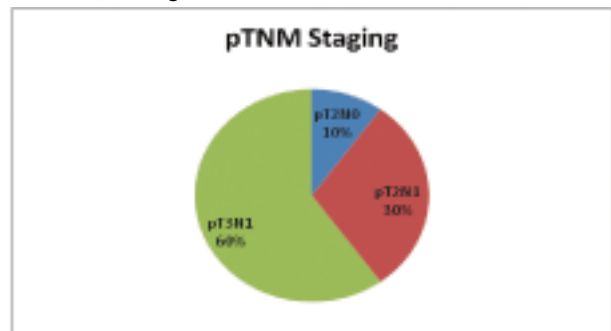


Figure 3: pTNM stages of patients

Table II: Postoperative complications

	Infection		Dehiscence		Trismus		Flap loss	
	n	%	n	%	n	%	n	%
Immediate postoperatively	3	15	3	15	1	5	0	0
After 3 months	0	0	0	0	0	0	0	0

Table III: Interincisal opening

Interincis: opening	Preoperative		Post-operative			
	n	%	On-Discharge		After 3 Months	
	n	%	n	%	n	%
10-20mm	0	0	0	0	0	0
21-30mm	0	0	0	0	2	10
31-40mm	20	100	20	100	18	90




Figure 4: Surface Texture of the flap

Discussion

After ablative surgical treatment of squamous cell carcinoma of the buccal mucosa when it is sufficiently deep and wide need to be reconstructed to prevent complication and functional impairment. Resection should include an adequate depth to prevent local recurrence. Reconstructive options for small buccal tissue defect now include the radial forearm free flap,^{9,20} buccal fat pad,²¹ temporalis muscle flap,²² alloderm and tissue-engineered mucosa grafts. The nasolabial island flap based superiorly or inferiorly on the subcutaneous blood supply, from the transverse, facial and angular vessels, can be used for buccal mucosa defects reconstruction. Some authors, believe that when using nasolabial flaps to cover lateral oral cavity defects, it is preferable to use a single stage technique.²³⁻²⁵

Hymes and Boyd²⁶ suggest that the reason this flap has proven itself so reliable is 2-fold. Firstly, there is an abundant dermosubdermal plexus supplying the whole area. Secondly, this vascular plexus is not haphazard but may exhibit a degree of axially ensuring good perfusion to the most distal parts of the flap. The vessels that contribute most to the subcutaneous arterial network include the facial and the transverse facial arteries.²⁷ Probably, anastomotic contribution from the contralateral superior and inferior labial vessels also occurs. Bilateral facial artery ligation seems not to be a contraindication to use an inferiorly and superiorly based "islanded" flap, although this is unclear from the literature.^{8,20} The previously mentioned inherent properties of the dermosubdermal plexus ensure flap reliability even in cases with bilateral facial artery ligation. Even though it depends on the site of the defects in the oral cavity, the functional outcome of the use of nasolabial flaps is satisfactory.^{17,28}

This retrospective observational study was performed at Dhaka Dental College and Hospital from August 2016 to July 2017 to bring out a solution which is simple, least technique sensitive and which gives excellent esthetic result with minimal number of complications, thereby satisfying both the patient and the surgeon. In this study total 20 patients with the age ranging from 35 to 68 years were assessed with a mean of 52.85±8.54 years. Among them 60% were male and 40% were female. This flap can be used for young and old patients, but gives the best results in elderly patients due to the laxity of the subcutaneous and skin tissue, which allows better primary closure of the

donor site.

The minimum size of the defect was 2x2 cm² and maximum size of defect was 4x4.5 cm². In this current study maximum size of flap harvested was 5X5 cm². The reported defect size ranged from (2-<5 cm).^{17,19,29} In this present series all the flaps healed well and 90 % were epithelialized with smooth surface texture. In this study 90% (n=20) patients presented with adequate mouth opening postoperatively. In two patients interincisal opening was decreased after radiotherapy. Nasolabial island flaps were successfully performed in reconstruction of intraoral defects with excellent chewing, swallowing, and speech functions and barely noticeable donor site scars.

Cosmetically donor site scar was assessed as patients' satisfaction whether excellent, good, fair or bad. Minty Five plural patients satisfied at the end of the study. Study results correspond to those described by Mebed, et al.³⁰ Among 20 patients, 15 % (3) patients developed infection, 15 % (3) patients developed dehiscence and trismus developed in 5% (1) patient but these wounds settled well with conservative management without adding significant morbidity for the patients. Varghese et al.¹⁷ reported of a flap loss rate of 5.5 % (partial loss) and 6.3% (complete loss) respectively in their series of 238 patients. In this group also one patient had partial flap loss out of ten patients that constitutes 10% partial flap loss. Garatea et al.³¹ stated the necessity for facial artery preservation in neck dissection if nasolabial flaps are to be used and Mutimer and Poole²⁷ suggested that it may be safer to avoid using nasolabial flaps if a neck dissection is required.

The nasolabial flap is a versatile, reliable local flap for reconstruction of medium size oral cavity defects with good cosmetic outcomes and negligible donor site morbidity. The study was conducted among the patients of Dhaka Dental College Hospital with study subjects 20 and short term follow-up. Probably larger prospective comparative studies with conventional reconstructive techniques in future will prove the versatility of the flap further. The nasolabial flap has proved to be a useful and reliable option for reconstruction of 2-<5cm defects of the buccal mucosa in order to allow wound closure without tension and maintain oral function.

This actually corresponds to the assumption that not only the facial artery, but probably a rich subdermal-plexus also supplies the flap.²⁶ Cosmetically donor site scar was assessed as patients' satisfaction whether excellent, good, fair or bad. Sajid et al.³² in their study All 14 patients looked fair (six patients)-to-good (eight patients) at the end of the study. Lazaridis et al.⁸ describe a study in which 9 patients undergo single-stage surgical interventions for the reconstruction of intraoral defects with nasolabial flaps, four of them involving a superior pedicle. In addition to a good aesthetic outcome, the incidence of postsurgical trismus is reduced thanks to the proximity of the donor region during the reconstruction, enabling a primary closure with little tension. Intraoral reconstruction using nasolabial flaps is a simple and fast procedure and can be recommended, particularly for the patients with medical co morbidities who are not good candidates for time-consuming operations including microsurgical reconstructions.

Conclusions

The nasolabial flap has proved to be a useful and reliable option for reconstruction of 2-5cm defects of the buccal mucosa in order to allow wound closure without tension and maintain oral function. Intraoral reconstruction using nasolabial flaps is a simple and fast procedure and can be recommended, particularly for the patients with medical comorbidities who are not good candidates for time-consuming operations including microsurgical reconstructions. The study was conducted among the patients of Dhaka Dental College Hospital with study subjects 20 and short term follow-up. Probably larger prospective comparative studies with conventional reconstructive techniques in future will prove the versatility of the flap further.

Acknowledgement

The authors are grateful to the patients who gave their consent to be included in the study, and we are so thankful to our dear friend Dr. Dhesha deulaul wlege honaital for giving permission and opportunity to work on this study.

References

1. Kushraj T. Bone invasion in oral cancer patients: a comparison between orthopantomograph conventional computed tomography, and single positron emission computed tomography. *Journal of cancer research and therapeutics* 2011; 7(4), 438-441.
2. Rao SV, Mejjia G, Roberts-Thomson K, Logan R. Epidemiology of oral cancer in Asia in the past decade-an update 2000-2012. *Asian Pacific journal of cancer prevention*. 2013; 14(10):5567-5577.
3. Khan Z, Tönnies J, Müller S. Smokeless tobacco and oral cancer in South Asia: a systematic review with meta-analysis. *Journal of cancer epidemiology*. 2014; 2014.
4. Hussain SA, Sullivan R. Cancer control in Bangladesh. *Japanese journal of clinical oncology*. 2013 Oct 25; 43(12):1159-1169.
5. Shaheed SMI, Molla MR. Oral Cancer in Bangladesh: Its Aetiology and Histological Grading. *Journal of Oral Health* 1996;2:8-11
6. Morshed AT, Rezaul H, Motiur RM. A retrospective study of oral cancer and its cervical lymphnode in Bangladesh. *Bangladesh dental Journal* 1997; 13 (1), 21-36.
7. El-Marakby HH. The reliability of pectoralis major myocutaneous flap in head and neck reconstruction. *J Egypt Natl Canc Inst*. 2006 Mar; 18(1):41-50.
8. Lazardis N, Zouloumis L, Venetis G, Karakasis D. The inferiorly and superiorly based nasolabial flap for the reconstruction of moderate-sized oronasal defects. *J Oral Maxillofac Surg* 1998; 56: 1255-1259.
9. Ducic Y, Burye M. Nasolabial flap reconstruction of oral cavity defects: A report of 18 cases. *J Maxillofac Oral Surg* 2000; 58: 1104-08.
10. Chitlangia P, Kumuran E, Sabitha KS. Use of nasolabial flap in intra and extraoral reconstruction: Our experience with 40 Cases. *J Maxillofac Oral Surg* 2012; 11(4): 451-454.
11. Rose EH. One staged arterialized nasolabial island flap for floor of mouth reconstruction. *Ann Plast Surg* 1981; 6: 71-75.
12. Wallace AF. Esser's skin flap for closing large palatal fistulae. *Br J Plast Surg* 1966; 19: 322-326.
13. Baliarsing AS, Thorat TS, Gupta A. Flap selection in head and neck cancer reconstruction. *Otorhinolaryngol Clin* 2013; 5(2): 63-76.
14. Pribaz J, Stephens W, Crespo L, Gifford G. A new intraoral flap: facial artery musculomucosal (FAMM) flap. *Plast Reconstr Surg* 1992; 90: 421-429.
15. Kim KW, Lee EY. Usage of nasolabial skin flaps for the reconstruction of various intraoral defects. *J Korean Assoc Maxillofac Plast Reconstr Surg* 2007; 1: 71-79.
16. El-Marakby HH, Fouad FA, Ali AH. One stage reconstruction of the floor of the mouth with a subcutaneous pedicled nasolabial flap. *J Egypt Natl Canc Inst* 2012; 24(2): 71-76.
17. Varghese BT, Sebastian P, Koshy CM, Thomas S, Cherian T, Ahmed I, Mohan PM. Nasolabial flaps in oral reconstruction: an analysis of 224 cases. *British journal of plastic surgery*. 2001 Sep 1; 54(6):499-503.
18. Singh S, Singh RK, Pandey M. Nasolabial flap reconstruction in oral cancer. *World J Surg Oncol* 2012; 10: 227.
19. Van Wijk MP, Damen A, Nauta JM, Lichtendahl DHE, Dhar BK. Reconstruction of the anterior floor of the mouth with the inferiorly based nasolabial flap. *Eur J Plast Surg* 2000; 23: 200-203.
20. Napolitano M, Mast BA. The nasolabial flap revisited as an adjunct to floor-of-mouth reconstruction. *Annals of Plastic surgery*. 2001 Mar 1;46(3):265-268.
21. Hao SP. Reconstruction of oral defects with the pedicled buccal fat pad flap. *Otolaryngology-Head and Neck Surgery*. 2000 Jun;122(6):863-867.

22. Ord RA. Local resection and local reconstruction of oral carcinomas. Operative Maxillofacial Surgery. London, Chapman and Hall Medical. 1998.
23. Rhee PH, Friedman CD, Ridge JA, Kusiak J. The use of processed allograft dermal matrix for intraoral resurfacing: an alternative to split-thickness skin grafts. Archives of Otolaryngology-Head and Neck Surgery. 1998 Nov 1;124(11):1201-1204.
24. Lauer G, Schimming R. Tissue-engineered mucosa graft for reconstruction of the intraoral lining after freeing of the tongue: a clinical and immunohistologic study. Journal of oral and maxillofacial surgery. 2001 Feb 1;59(2):169-175.
25. Carruth JA. Cancer of the Face and Mouth. Mc Gregor and Mc Gregor. Churchill Livingstone, 1986. ISBN 0443 02455 3. Hematological Oncology. 1987 Jan;5(1):74.
26. Hynes B, Boyd JB. "The nasolabial flap: Axial or random?". Arch Otolaryngol Head Neck Surg .1988; 114:1389-1391.
27. Mutimer KL, Poole MD. A review of nasolabial flaps for intra-oral defects. British journal of plastic surgery. 1987 Sep 1;40(5): 472-477.
28. Hofstra EI, Hofer SO, Nauta JM, Roodenburg JL, Lichtendahl DH. Oral functional outcome after intraoral reconstruction with nasolabial flaps. British journal of plastic surgery. 2004 Mar 1;57(2):150-155.
29. Maurer P, Eckert AW, Schubert J. Functional rehabilitation following resection of the floor of the mouth: the nasolabial flap revisited. Journal of cranio-maxillofacial surgery. 2002 Dec 1;30(6):369-372.
30. Mebeed AH, Hussein HA, Saber TKh. Critical appraisal of nasolabial flap for reconstruction of oral cavity defects in cancer patients. J Egypt Natl Cancer Inst 2009; 21: 33-44.
31. Garatea J, Buenechea R, Bescos C, Gonzalez E, Bassas C. Intraoral reconstruction with the nasolabial island flap. A modified technique. J Craniomaxillofac Surg. 1991;19(3):119-122.
32. Sajid MA, Latif K, Younus S, Warraich RA, Mehmood HS, Aftab A, Bimb K. Utilization of Nasolabial Flap for Reconstruction Of Oral Cavity Defects. Pakistan Oral and Dental Journal. 2015 Mar 1;35(1).