

Original Article



Using Panoramic Radiograph for Identification of Mandibular Structures: A Study on Bangladeshi Population

Dipayan Mojumder¹, Ruman Banik²,
Md. Shahidul Islam³, Md. Asaduzzaman⁴.

Abstract

Background: Panoramic view of radiograph or Orthopantomogram (OPG) is useful in the aspect of surgery done in mandible, as many visible landmarks can be found in a single tomographic image. **Objectives:** To evaluate the visibility of anatomical structures of mandible in OPG and to determine the relationship of age and gender with this. **Materials and Methods:** It was a cross-sectional study and was conducted in dental OPD of Noakhali General Hospital from January 2019 to June 2019, six-month period. Data were analyzed by SPSS version 20. **Results:** A Total of 272 OPGs were examined of patients (female 165, male 107), having age range of 7-90 years. Here highest visible structure was mandibular canal (about 97.4%) followed by mental foramen and mandibular foramen, where visibility was 92.3% and 87.5% respectively. Anterior loop of mental nerve and incisive canal were seen in 33.5% and 31.6% cases respectively. Only in 15.1% OPG, lingual foramen was visible. There is no significant relationship between gender and visibility of structures ($p > 0.05$). Age and visibility of landmarks showed significant relation only in case of mental foramen and mandibular canal ($p < 0.05$). **Conclusion:** Panoramic view or orthopantomogram is very efficient to detect many anatomic points in adults.

Key words: Panoramic radiograph, OPG, mandible, anatomic landmarks, Bangladeshi.

Date of received: 07.04.2020.

Date of acceptance: 20.08.2020.

KYAMC Journal.2020;11(3): 133-136.

DOI: <https://doi.org/10.3329/kyamcj.v11i3.49870>

Introduction

Successful completion of any surgical procedure depends on identification of anatomical structures of that area. To do any surgery in mandible, like management of fracture, apicectomy, surgical extraction of impacted third molar tooth, even implant placement in mandible, identification of structures like mandibular foramen, mandibular canal, mental foramen etc. is the basic requirement.

Various imaging techniques such as intraoral periapical view (IOPA), orthopantomogram (OPG), occlusal view of mandible, CT scan, and cone beam computed tomography (CBCT) are used to visualize the anatomical structures of mandible. Among

them CT scan is the most helpful because it gives better visualization of structures by section.¹ But cost and unavailability make its uses limited.

Panoramic imaging (also known as Pantomograph) is a technique of producing single tomographic image of both jaws and their supporting structures.² Through it generates a two-dimensional image of three-dimensional structure and overlapping structures sometimes might lead to misdiagnoses, it is helpful to see many anatomical points in a single film, which is not possible in IOPA or occlusal view. Also, low-cost and easy availability make it more acceptable.³

1. Former Lecturer, Department of Dental Public Health, Dhaka Dental College, Mirpur-14, Dhaka, Bangladesh.
2. Medical Officer, Department of Oral and Maxillofacial Surgery, Bangabandhu Sheikh Mujib Medical University (BSMMU), Dhaka, Bangladesh.
3. Associate Professor and HOD, Department of Prosthodontics, Khwaja Yunus Ali Medical College Dental Unit, Enayetpur, Sirajganj, Bangladesh.
4. Assistant Professor, Department of Oral and Maxillofacial Surgery, Bangabandhu Sheikh Mujib Medical University, Dhaka, Bangladesh.

Correspondence: Dr. Dipayan Mojumder, Former Lecturer, Department of Dental Public Health, Dhaka Dental College, Mirpur-14, Dhaka, Bangladesh, Cell: +88 01748694899, Email: dipayan.m.ddc@gmail.com □ □ □

Many studies have been conducted regarding the visibility of different anatomical landmarks in panoramic radiograph such as mental foramen, incisive canal, mandibular foramen, anterior loop of mental nerve, mandibular canal.⁴⁻⁷ In the Bangladeshi population, mandibular condyle and

anatomical variation of mental foramen in OPG was identified in different studies.⁸⁻⁹ But, visibility of all the structures of mandible and their relation with age or gender was not examined before. The aim of our study to evaluate the visibility of six anatomical structures of mandible mandibular foramen, mandibular canal, mental foramen, anterior loop of mental nerve, incisive canal, lingual foramen and to determine the relationship between age or gender with visibility of these structures.

Materials and Methods

It was a cross-sectional study conducted in the Dental OPD of Noakhali General Hospital. Panoramic images were taken from Bangladeshi population without any musculoskeletal disorders, fracture of jaws or having any cystic lesion or tumor. Any developmental anomalies of both jaws were excluded in study. Verbal consent was taken from all the patient in the study.

Images were taken randomly and total 272 images were taken in six-month period from January 2019 to June 2019. Age range was 7-90 years. All images were taken with a digital orthopantomogram machine SCANORA 5.2.2 with parameters of 73-77 kV, 10 mA tube current and time for 9.00s. Status of visibility in radiograph were divided into 4 categories. (Table-I)

All structures that are examined, marked on figure 1. All patients were divided into 4 age groups-

- Group A: First and second decades (Child and adolescence)
- Group B: Third and fourth decades (Adulthood)
- Group C: Fifth and sixth decades (Old adults)
- Group D: More than six decades (Elderly)

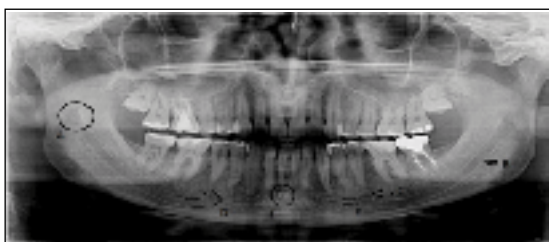


Figure 1: Different structures in panoramic view A. Mandibular foramen, B. Mandibular canal, C. Mental foramen, D. Anterior loop, E. Incisive canal, F. Lingual foramen

This categorization is due to visibility may affect by the changes in mineral content of bone and different growth periods are involved. Radiographs were examined by two dentists.

The data were analyzed by Statistical Package for the Social Sciences (SPSS version 20). P value less than 0.05 considered significant.

Results

In our study total 272 OPGs are examined. Most of them were females and 165 in numbers. Others 107 patients were male. Age range of the patients was 7-90 years and mean age was 35.68 years.

Visibility of all anatomic structures of mandible in panoramic view is shown in table-I. Here highest visible structure was mandibular canal about 97.4%, following this, mental foramen and mandibular foramen showed good visibility. Only 7.7% was not visible in case of mental foramen and mandibular foramen is not detected in 12.5% cases.

Anterior loop and incisive canal have almost same visibility in OPG as identification was possible in only 33.5% and 31.6% respectively. Lingual foramen is the least identified structure in OPG and visibility was only 15.1%. Appearance of anatomical landmarks in each gender is shown in figure 2. There is no significance relationship is found between visibility and gender. (p>0.05).

Table I: Visualization of anatomical structures on panoramic images

	Landmarks											
	Mandibular foramen		Mandibular canal		Mental foramen		Anterior loop		Incisive canal		Lingual foramen	
Visibility	n	%	n	%	n	%	n	%	n	%	n	%
Present on both side	183	67.3%	241	88.6%	200	73.5%	15	5.5%	21	7.7%	41	15.1%
Present on right side	26	9.6%	17	6.2%	23	8.5%	30	11%	8	3%	0	0.0%
Present on left side	29	10.6%	7	2.6%	28	10.3%	46	17%	57	21%	0	0.0%
Not visible	34	12.5%	7	2.6%	21	7.7%	181	66.5%	186	68.4%	231	84.9%

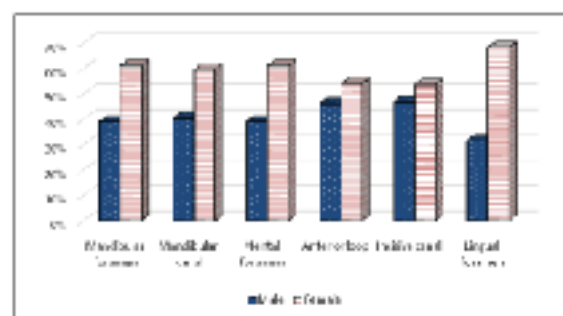


Figure 2: Visibility of anatomic landmarks in each gender

The numbers of males and females of different age groups are shown in table II and visible different structures in multiple age groups shown in figure 3.

Table II: Age and gender distribution of patients

Gender of respondents	Age groups				Total
	Group 1	Group 2	Group 3	Group 4	
Male	17	52	27	11	107
Female	29	83	42	11	165
Total	46	135	69	22	272

In our study visibility mostly found in adulthood (21-40 years of age) and identification was limited in child and elderly. This feature suggests that OPG is considered as a good radiograph in case of adults in comparison to child and old age. In second and third decades, all structures seen in more than 50% cases. On the other hand, in other age groups, less than 20% was seen. Significant relation is found between age groups and visibility of mental foramen and mandibular canal ($p < 0.05$), but no relation is found with other structures ($p > 0.05$).




Figure 3: Appearance of anatomic structures in each age group

Discussion

From our study we found mandibular canal and mental foramen are the most visualized structures in OPG. Both of which seen in more than 90% cases which is similar with the study of Jacobs et al.⁵ In another study mandibular canal and mental foramen were identified in 86% and 66% cases respectively which is lesser than our findings.¹⁰ Mandibular foramen was identified in 87.5% cases in our study which is slightly less than other studies.^{5,11}

Anterior loop of mental nerve is the most important structure in this observation. Along with mental foramen and mandibular canal, this landmark always guides the surgeon to perform implant surgery without damaging the nerve bundle. In 33.5% case anterior loop of mental nerve is identified which is greater than other studies.^{5,10} But in a study of the Iranian population it is found in 66% cases which is almost double than our finding.¹¹

Incisive foramen was identified more than lingual foramen and less than other structures of mandible. It was seen in 31.6% cases which was almost double than another study.⁵ Lingual foramen is the least visualized landmark in this panoramic view study, where it is observed in 15.1% patients. This result is more than twice of the finding of a study by Jalili et al, but very less than another finding of such study.^{5,11}

In different age groups appearance of anatomical points were not the same. Most visibility found in case adulthood (third and fourth decades) of life. But it was least visible in child and elderly. These findings are almost similar to such studies.^{11,12} This type of results may found for many reasons. Firstly, in mixed dentition stage of child, many anatomical structures are overlapped such as mental foramen, anterior loop by tooth buds in child. Also in case of aged people due to edentulousness and decay of bone causes smaller mandible and some structures may change their position in OPG.

On the other hand, adults having a trabecular pattern of bone and dark radiograph may find the anatomical points clearer.⁴

Secondly, there is change in mineral density of bone in various age groups. Sclerotic change occurs during aging and collagen density becomes reduced. For this, radiation absorption and transmission also different in each decade.^{13,14}

Above findings of our study clearly indicate that, effectiveness of panoramic view in adult is good as it shows the greater visibility of anatomic structures of mandible. But, it has its limitation in child and old age people, which can overcome in other imaging technique such as computed tomography.¹⁵

Conclusion

Panoramic view or orthopantomograph is very efficient to detect many anatomic points in adults. Although it creates some confusion regarding measurement of structures because mandible is a three-dimensional structure and resolution should be adequate, but availability and low cost make it more acceptable except special cases. Further research should include larger sample size from people of different geographic regions to evaluate diagnostic possibility of panoramic view and also advanced diagnostic methods should apply for the proper evaluation of anatomical structures in mandible.

Acknowledgement

We would like to express our gratitude to Dr. Susanta Majumder, Dental Surgeon, Noakhali General Hospital, Noakhali, and radiologic technician Md. Forhad for kind cooperation in providing panoramic radiographs.

References

1. Lindh C, Petersson A, Klinge B. Visualisation of the mandibular canal by different radiographic techniques. *Clinical oral implants research*. 1992; 3(2):90-97.
2. White SC, Pharoah MJ. *Oral radiology-E-Book: Principles and interpretation*. Elsevier Health Sciences; 201, 4 May 1.
3. Lins CC, Tavares RM, Silva CC. Use of digital panoramic radiographs in the study of styloid process elongation. *Anatomy research international*. 2015; 28.
4. Yosue T, Brooks SL. The appearance of mental foramina on panoramic radiographs. I. Evaluation of patients. *Oral Surgery, Oral Medicine, Oral Pathology*. 1989; 68(3):360-364.
5. Jacobs R, Mraiwa N, van Steenberghe D, Sanderink G, Quirynen M. Appearance of the mandibular incisive canal on panoramic radiographs. *Surgical and Radiologic Anatomy*. 2004; 26(4):329-333.
6. Kuzmanovic DV, Payne AG, Kieser JA, Dias GJ. Anterior loop of the mental nerve: a morphological and radiographic study. *Clinical oral implants research*. 2003;14(4):464-471.
7. Afkhami F, Haraji A, Boostani HR. Radiographic localization of the mental foramen and mandibular canal. *Journal of Dentistry (Tehran, Iran)*. 2013;10(5):436.
8. Chowdhury TG, Rahman D, Jannat TA, Hossain MM, Sultana A, Iqbal MA, Noor AE. Radiographic position of mental foramen in selected urban population of Bangladesh. *Update Dental College Journal*. 2015; 5(1):3-9.
9. Anisuzzaman MM, Khan SR, Khan MT, Abdullah MK, Afrin A. Evaluation of Mandibular Condylar Morphology by Orthopantomogram In Bangladeshi Population. *Update Dental College Journal*. 2019; 9(1):29-31.
10. Basappa S, Smitha JD, Khanum N, Kanwar S, Mahesh MS, Patil A. Visibility of Maxillary and Mandibular Anatomical Landmarks in Digital Panoramic Radiographs: A Retrospective Study. *Research & Reviews: Journal of Dental Sciences*. 2017; 5(3):36-41.
11. Jalili MR, Esmaeelinejad M, Bayat M, Aghdasi MM. Appearance of anatomical structures of mandible on panoramic radiographs in Iranian population. *Acta Odontologica Scandinavica*. 2012; 70(5):384-389.
12. Ngeow WC, Dionysius DD, Ishak H, Nambiar P. A radiographic study on the visualization of the anterior loop in dentate subjects of different age groups. *Journal of oral science*. 2009; 51(2):231-327.
13. Berger C, Langsetmo L, Joseph L, Hanley DA, Davison KS, Josse R, Kreiger N, Tenenhouse A, Goltzman D. Change in bone mineral density as a function of age in women and men and association with the use of antiresorptive agents. *Cmaj*. 2008; 178(13):1660-1668.
14. Dechow PC, Wang Q, Peterson J. Edentulation alters material properties of cortical bone in the human craniofacial skeleton: functional implications for craniofacial structure in primate evolution. *The Anatomical Record: Advances in Integrative Anatomy and Evolutionary Biology*. 2010; 293(4):618-629.
15. Pereira-Maciel P, Tavares-de-Sousa E, Oliveira-Sales MA. The mandibular incisive canal and its anatomical relationships: A cone beam computed tomography study. *Medicina oral, patologia oral y cirugia bucal*. 2015; 20(6):e723.