

Review Article



Distal Transradial Access For Percutaneous Coronary Intervention And Coronary Angiography : Advances In Interventional Cardiology

S.M. Taslim Yusuf Tamal¹, Steven Huang², Md. Saiful Islam³, SK. Yunus Ali⁴.

Abstract

Since its' introduction in 2017, Distal Transradial Access (dTRA) has shown its advantages over conventional Transradial Approach in terms of risk with Radial Artery Occlusion (RAO) and with the comfort level for both the patient and operator. A large number of patients requiring subsequent intervention gets much benefit with this new technique of Radial Artery (RA) preservation, as it is a refinement of the conventional approach. On the other hand, the most challenging part it has is the supreme level of expertise for a successful puncture for the advancement with the procedure. Still, this new technique has been obtained by the Interventionists world wide with the simultaneous study on it to make the distal transradial access as a default access site for routine Coronary Angiography (CAG) and Percutaneous Coronary Intervention (PCI). For evaluation with the real world feasibility and safety along with the comfort for both the operator and patient, this study has been conducted.

Key words: Coronary angiography, Percutaneous coronary intervention, Distal radial artery, Anatomical snuffbox, Radial artery.

Date of received: 22.05.2020.

Date of acceptance: 20.08.2020.

DOI: <https://doi.org/10.3329/kyamcj.v11i3.49875>

KYAMC Journal.2020;11(3):154 -157.

Introduction

From Femoral to Radial, and subsequently from Radial to Distal Radial, the accessing site for Percutaneous Coronary Intervention (PCI) have been switching for last several decades. The Distal Radial Access was first introduced in the year 2017,¹ since then it showed higher success rate, very few complications and therefore this access site might become the possible best way for cardiac intervention in new era.

Accessing through the anatomical snuffbox into distal radial artery has shown advantages over the traditional radial and femoral artery approach.² The objective of this study is to review the literatures for Coronary Angiography(CAG) and

Percutaneous Coronary Intervention(PCI) via distal Transradial Approach (dTRA) and its possible outcome.³

Advantages of dTRA includes easier access for coronary vessels, preservation of proximal radial artery for future procedure and also include to some extent for patient's and operator's comfort.⁴⁻⁷ This also decreases the risk of radial artery occlusion in post-operative period.

Although one of the very important drawback of the technique is most challenging puncture at a small artery.

To conclude with the feasibility, safety of the access and comfort for patients and operatorsthrough dTRA for CAG and PCI,⁸ this review study is being conducted.

1. MD Candidate, Department of Cardiology, Zhejinag Chinese Medical University, Hangzhou, China.
2. Professor and Head, Department of Cardiology, Hangzhou People's 2nd Affiliated Hospital of Zhejiang Chinese Medical University, Hangzhou, China.
3. Professor and Head, Department of Cardiology, Khwaja Yunus Ali Medical College And Hospital, Enayetpur, Sirajganj, Bangladesh.
4. Professor Emeritus, Head of Cardiology Department, Diabetic Association Medical College Hospital, Faridpur, Bangladesh.

Correspondence: Dr. Steven Huang, Professor and Head, Department of Cardiology, Hangzhou People's 2nd Affiliated Hospital of Zhejiang Chinese Medical University, Hangzhou, P.R.China (310053), Contact: shuweih@hotmail.com

Method

In the Anatomical Snuffbox (Figure 1), the distal branch of radial artery is typically palpable. The patient is asked to lie down with the arm at a neutral position and holding a roll of gauze or a small rolled towel in grip. This gives wider access at the dorsum of the hand and also patient can hold on to something during the procedure and may get relief.⁹

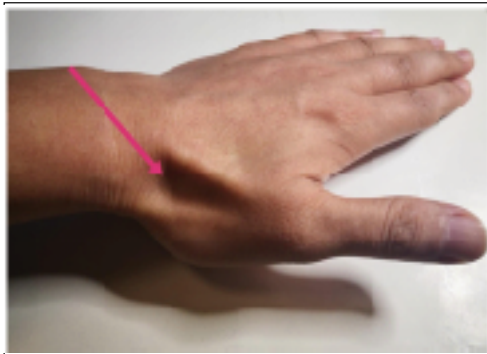


Figure 1: Puncture position at anatomical snuffbox.

For accessing through left arm, the patient is asked to put the left arm on the belly in a natural way so that the hand may lie over the left groin area.⁸ (Figure 2)

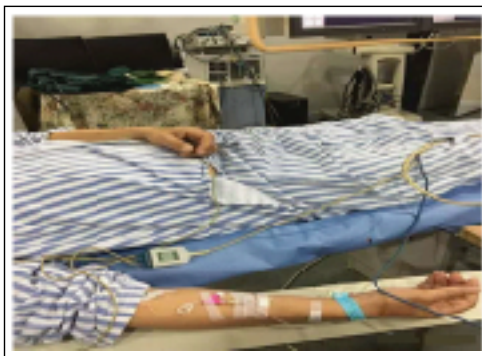

Figure 2: The left hand is placed such a way which is more comfortable for the operator and the patient.¹⁷

After maintaining proper sterility, once the wrist is prepared, access to the artery can be obtained at ease.^{10,11} Use of ultrasound may be of beneficial to use for locating the artery, and also may give an idea to the diameter of the vessel and thus help the operator to choose actual size of catheter and sheaths while doing the procedure.

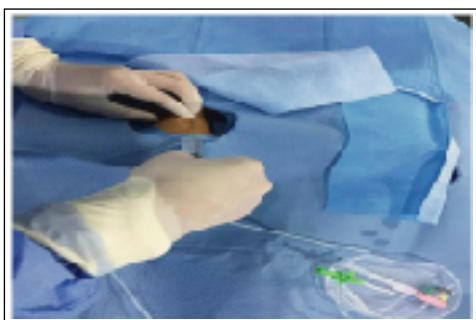


Figure 3: Injecting local anesthetics (2% Lidocaine hydrochloride) at puncture site.

2 to 3 ml of 2% Lidocaine hydrochloride is injected subcutaneously (Figure 3) using 25 G needle in the anatomical snuffbox as local anesthetic. Precautions must be taken to avoid prick injury by needle to styloid process of Radius bone, as it may be very painful at time. The puncture is done at an angle of 30-45 degree (Figure 4) following Seldinger's technique with the help of a 20 G micropuncture cannula at a direction of lateral to medial side.

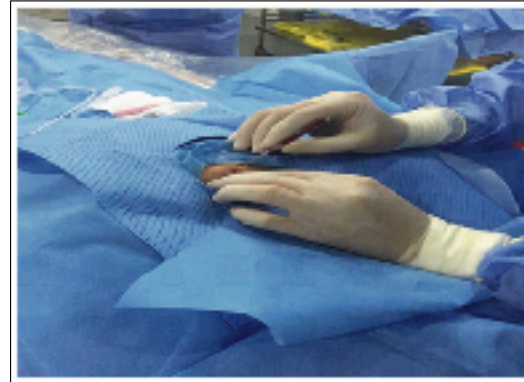


Figure 4: The puncture here is the same as radial artery puncture. The radial artery felt here is superficial and the needle is at 45 degree. patient's pain is not that obvious.¹⁷

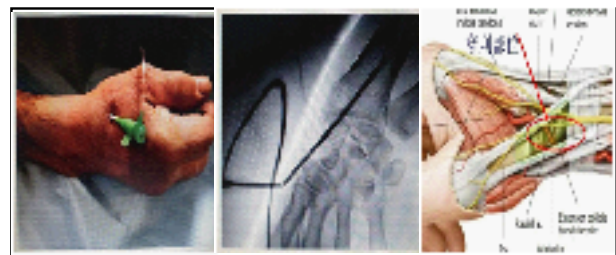

Figure 5: Puncture site established for further enhancement with the procedure.

After a successful puncture at the anatomical snuffbox (Figure 5), comes the most critical part of the procedure- insertion of the short guide wire (Figure 6) through the cannula in a retrograde fashion and advancement of it towards the natural course of radial artery. At this point, good care should be taken with radial expertise for smooth and proper advancement of the guide wire.

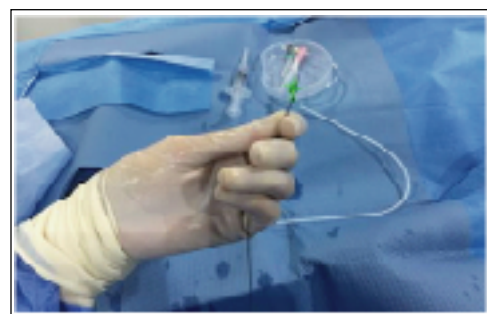

Figure 6: Short guide wire, to be inserted in a retrograde fashion.

It's better to shape the head end of the guide wire to facilitate the smooth entry of the sheath (Figure 7), the forwarding of the sheath should be too gentle as it needs to cross the styloid process and turn to palmar side. Sometimes, it needs PTCA guide wire.

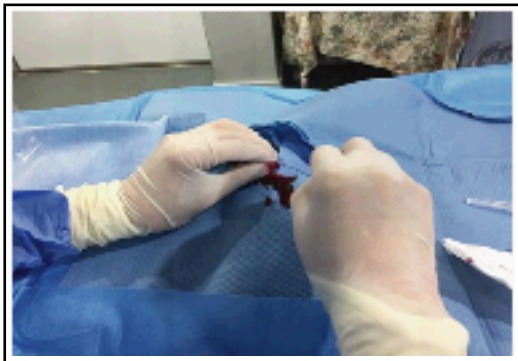

Figure 7: Shaping of the Head-end of the guide wire.

The injection speed must be slow after penetration. One need to feed the guide wire gently.¹⁷

Before introduction of the sheath along the guide wire, a small skin incision may be needed to avoid the sheath damage in some cases. After the insertion of the sheath over the short guide wire, the dilator along with the wire may be removed. Confirmation of the arterial puncture can be obtained by the arterial waveform in the monitor. If the blood pressure of the patient permits, a spasmolytic cocktail of 200 mcg of Nitroglycerine and 2.5 mg of Verapamil can be administered, though usually not needed. The first dose of Heparin (50-100 IU/kg) is given simultaneously. Patient's arm is then stabilized by the side of the body, to manipulate 0.35" wire, the catheters and intracoronary devices as per need. In case of PCI, additional weight adjusted dose of Heparin is administered. In case of any difficulty during guide wire advancement at the elbow level, flouroscopy or angiography can be done to see the arterial loops. CAG and/or PCI is then performed in a usual manner.¹³

Securing Hemostasis

Once the procedure is completed, the sheath is flushed and pulled out. Permitting the blood pressure of the patient, additional dose of vasodilators may be given for the purpose of reduction of the discomfort caused by sheath removal, and also to reduce the chances of Radial artery occlusion(RAO).¹⁴ A radial band is then placed at the puncture site (Figure 8). Pad of wrapped gauze is placed over the puncture site using adhesive tapes. This dressing can be removed usually after 2 to 3 hours in all patients.

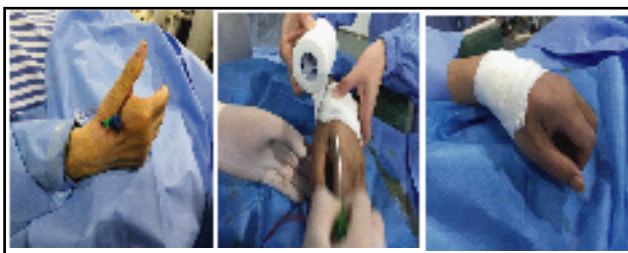


Figure 8: Progressing with steps of Hemostasis.

After operation, the extraction and compression are very simple. Generally the compression time is shorter than that of conventional radial artery. As the elastic bandage doesn't compress the ulnar artery,¹⁷ the patient's hand pain after operation is less.

Finally, radial artery pulsations are checked manually by palpatory method at different anatomical sites.

Justification

The dTRA is advocated for reasons as follows-

1. Radial Artery Occlusion (RAO) risk reduction with decrease in bleeding and vascular site access complication.¹⁵
2. Accessing through the anatomical snuffbox also reduce the risk of compartment syndrome in forearm.
3. Improve patient's and operator's comfort during the procedure and post procedure period.
4. Short compression time with better hemostasis.
5. Preserving the Radial Artery for any further procedure in future.

Limitations

1. The normal diameter of a radial artery varies with sex, race, etc. and is approximately 2.05 to 2.7mm which is found by ultrasound, where as that of distal radial possess 80% less diameter and thus makes it a bit difficult to puncture properly. A succesful puncture thus requires overcoming a relatively longer learning curve.
2. In a certain group of patients, distal radial artery is too weak to attempt a puncture. Those cases should be handled with extra care and the use of ultrasound to detect the accurate puncture site is advocated in such cases. Here also, the operator's expertise will increase with an incresased number of puncture of such cases.
3. Due to more distal puncture site, in case of tall patients, the extra length catheters (110 to 115cm) may be required¹² rather than usual sized catheter (100cm).
4. It is certain that, distal transradial access is definitely not suitable for unselected patient. One of the vital reason being absence of clear pulsation found at anatomical snuffbox.
5. As a whole, accessing the distal radial artery is therefore still remains more challenging for a successful puncture for the procedure.

Conclusion

As far as the procedure is concerned, the distal radial artery access is still a safe, reliable, effective and comfortable approach for the majority of the patients. It has almost the same outcome as traditional radial artery approach. Moreover, through this technique the occlusion of radial artery at forearm can be overcome. Based on the patient's and operator's comfort, dTRA has an upper hand over the traditional approach, though being tough to successful puncture.¹⁶

As more data and study required to precise the role of dTRA in daily practice, it must not replace the standard transradial access. But certainly, it can be considered for the patients who prefer through this access site or are eligible for the procedure as there remains a well palpable distal radial artery branch at anatomical snuffbox.

Acknowledgement

I am very much grateful to my Supervisor Prof. Dr. Steven Huang for his tremendous guidance to me throughout the writing of this article. I am also very much thankful to the other authors of this article for accepting my idea of writing this topic and helping me in every step of mine. My sincere gratitude to the editorials of KYAMC Journal for accepting this review article for publication.

Abbreviations

CAG- coronary angiography, PCI- percutaneous coronary intervention, dTRA- distal transradial access, RAO- radial artery occlusion

References

- Nairoukh Z, Jahangir S, Adjepong D, et al. Distal Radial Artery Access: The Future of Cardiovascular Intervention. *Cureus* 2020;12(3): e7201.
- Radner S. Thoracic aortography by catheterization from the radial artery. *Acta Radiol.* 1948;29:178-180.
- Campeau L. Percutaneous radial approach for coronary angiography. *Cathet Cardiovasc Diagn.* 1989;16:3-7.
- Romagnoli E, Biondi-Zoccai G, Sciahbasi A, Radial versus femoral randomized investigation in ST-segment elevation acute coronary syndrome: the RIFLE-STEACS (radial versus femoral randomized investigation in ST-elevation acute coronary syndrome) study. *J Am Coll Cardiol* 2012;60(24):2481-2489.
- Jolly SS, Yusuf S, Cairns J, et al. Radial versus femoral access for coronary angiography and intervention in patients with acute coronary syndromes (RIVAL): a randomised, parallel group, multicentre trial. *Lancet* 2011;377(9775):1409-1420.
- Bernat I, Horak D, Stasek J, et al. ST-segment elevation myocardial infarction treated by radial or femoral approach in a multicenter randomized clinical trial: the STEMI-RADIAL trial. *J Am Coll Cardio* 2014; 63(10): 964-972.
- Bertrand OF, Belisle P, Joyal D, Comparison of transradial and femoral approaches for percutaneous coronary interventions: a systematic review and hierarchical bayesian meta-analysis. *Am Heart J* 2012;163(4):632-648.
- Kiemeneij F, Laarman GJ. Percutaneous transradial artery approach for coronary stent implantation. *Cathet Cardiovasc Diagn* 1993;30: 173-178.
- Babunashvili A, Dundua D. Recanalization and reuse of early occluded radial artery within 6 days after previous transradial diagnostic procedure. *Catheter Cardiovasc Interv* 2011;77:530-536.
- Kiemeneij F. Left distal transradial access in the anatomical snuffbox for coronary angiography (ldTRA) and interventions (ldTRI). *EuroIntervention* 2017;13:851-857.
- Sgueglia GA, Di Giorgio A, Gaspardone A, Anatomic Basis and Physiological Rationale of Distal Radial Artery Access for Percutaneous Coronary and Endovascular Procedures. *JACC Cardiovasc Interv* 2018;11:2113-2119.
- Kiemeneij F. Left distal transradial access in the anatomical snuffbox for coronary angiography and interventions. *EuroIntervention* 2017; 20:851-857.
- Lee JW, Park SW, Son JW, Real-world experience of the left distal transradial approach for coronary angiography and percutaneous coronary intervention: a prospective observational study (LeDRA). *EuroIntervention* 2018;14:e995-1003.
- Abboud J, Garyali S, A single center experience with radial artery occlusion and spasm after a minor change in the protocol for administration of the radial artery cocktail. *Catheter Cardiovasc Interv* 2013; 81:S171.
- Davies RE, Gilchrist IC. Back hand approach to radial access: The snuffbox approach. *Cardiovasc Revasc Med* 2018;19:324-326.
- Campeau L. Entry sites for coronary angiography and therapeutic interventions: From the proximal to the distal radial artery. *Can J Cardiol* 2001;17:319-325.
- Yu W, Hu P, Wang S, Yao L, Wang H, Dou L, Lu M, Bo G, Yu X, Chen J, Chen C, Luo Y, Yang M, Dong Z, Huang S. Distal radial artery access in the anatomical snuffbox for coronary angiography and intervention: A single center experience. *Medicine* 2020;99(3):e18330.